

Studies on Aortic and Aortic Valve Diseases

Salah A. Mohamed*, Johnson J Yan and Hans H Sievers

Department of Cardiac and Thoracic Vascular Surgery, Universitaetsklinikum Schleswig-Holstein, Campus Luebeck, Germany

Abstract

Bicuspid aortic valve (BAV) is the most common congenital cardiac malformation, with an estimated incidence of 1%–2% in the general population. Patients with BAV are predisposed to early and frequent stenosis, regurgitation, and endocarditis, often accompanied by aneurysm and dissection. A family-based genome-wide analysis found that BAV was linked to chromosomal regions 5q, 13q, and 18q, with autosomal dominant inheritance, reduced penetrance and a non-Mendelian inheritance pattern. Mutations in the transmembrane receptor-encoding gene *NOTCH1* have been detected in familial and sporadic BAV cases. Mutations in the vascular smooth muscle cell alpha actin gene (*ACTA2*) have also been identified in BAV patients. Expression of *UFD1L*, a gene that is highly expressed in the outflow tract during embryogenesis, was downregulated in the cusps of BAV patients compared with those of controls. BAV is associated with left ventricular outflow tract abnormality, including aortic coarctation, arch hypoplasia, and supravalvular and mitral valve stenosis. A male predominance of more than 3:1 has been reported for BAV. This anomaly is very frequent in X0 Turner's syndrome. Many studies have observed similarities between the histology of aortic aneurysmal tissue in the connective tissue disorder Marfan syndrome (MFS) and the histology of the corresponding tissue in BAV. In this lecture, we review our present understanding of BAV malformation and ascending thoracic aortic aneurysm pathogenesis. We discuss the genetic basis and the basic pathology underlying BAV and aortopathy and compare these with known mechanisms underlying MFS.

Keywords: Bicuspid aortic valve; Ascending aorta; Aortopathy

Bicuspid aortic valve (BAV)

BAV, with an incidence of 1–2% in the population, represents the most common congenital heart defect [1]. The heritability of BAV, estimated to be between 0.75 and 0.89, is high. Family-based genome-wide analyses have revealed a linkage between BAV and chromosomal regions 5q, 13q, and 18q [2], with an autosomal dominant mode of inheritance, a reduced penetrance and a non-Mendelian inheritance pattern [3]. Mutations were detected in the transmembrane receptor *NOTCH1* (gene map locus 9q) [4]. Moreover, mutations in the vascular smooth muscle cell alpha actin gene (*ACTA2*, mapped to chromosome 10q) have been identified in patients with BAV and aortic aneurysms [5]. The ubiquitin fusion degradation 1-like gene (*UFD1L*), which is highly expressed in the outflow tract during embryogenesis, is downregulated in the cusps of patients with BAV compared with those of control patients [6]. Furthermore, BAV is associated with left ventricular outflow tract abnormalities, including aortic coarctation, arch hypoplasia and supravalvular and mitral valve stenosis [7]. Tissue-specific deletion of the gene encoding activin receptor type 1 (*Alk2/Acrv1*) in the cushion mesenchyme results in the formation of aortic valve abnormalities, including BAV [8]. A male predominance of more than 3:1 has been reported for BAV, and this anomaly is very frequent in X0 Turner's syndrome (incidence rate: 22–34%), suggesting an X-linked etiology [9]. An analysis of a subpopulation with Andersen syndrome described four members with BAV. In Andersen syndrome, a mutation in the potassium inwardly-rectifying channel, subfamily J, member 2 gene (*KCNJ2*) is observed [10]. Some studies have reported the involvement of miRNAs in BAV. miRNAs are small (approximately 22 nucleotides in length), noncoding nucleotide RNAs that have been shown to modulate mRNA stability and translation. Nigam et al. demonstrated that miR-26a was downregulated in fused aortic valves, and miR-26a was also found to be downregulated in aneurysms [11,12]. Recent studies have also reported a significant decrease in the amount of eNOS protein present in BAV-associated aneurysmal aortic tissue compared with that of tricuspid aortic valve (TAV) tissue [13]. Mohamed et al. detected decreased levels of eNOS protein in

different areas of ascending aortic aneurysms. In conjunction with BAV, this can influence the cytosolic protein levels of pro-apoptotic HTRA2/Omi. They speculate that the local differences in eNOS protein expression observed in BAV compared with TAV aortic aneurysms were probably caused by variations in aortic wall shear stresses [14]. There are several known polymorphisms in the eNOS gene (*NOS3*), some of which have biological relevance [15,16]. This study aimed to investigate the frequency of *NOS3* mutations in patients with BAV and ascending aneurysms. Whole genomic 23.5 kb eNOS gene, including 28 exons, was analyzed. Subsequently, SNP analysis was performed using the MassARRAY method and MALDI-TOF mass spectrometry for analytic detection. A set of 18 variants of the eNOS gene was generated from direct sequencing, whereas 16 variants represent SNPs and two are insertion/deletions and STR variants, respectively. The distribution of alleles was compared in 90 patients with BAV (mean age 52.3 ± 12.8 years, aortic diameter 48.1 ± 8.9 mm) and 11 Patients with TAV (mean age 53.7 ± 18.2 years, aortic diameter 51.2 ± 13.3 mm). Statistical analysis revealed that three SNPs (rs1549758, rs1799983 and rs2566514) featured a significantly different allele distribution between BAV and controls. However, the association between these SNPs and BAV aortopathy requires further replications.

BAV Aortopathy

Many studies have observed similarities between the histology

*Corresponding author: Salah A. Mohamed, Department of Cardiac and Thoracic Vascular Surgery, University Clinic of Schleswig-Holstein Campus Luebeck, Ratzeburger Allee 160, 23538 Luebeck, Germany, Tel: +49-451-5006425; Fax: +49-451-5002051; E-mail: salah.mohamed@uk-sh.de

Received July 06, 2013; Accepted August 16, 2013; Published August 19, 2013

Citation: Mohamed SA, Yan JJ, Sievers HH (2013) Studies on Aortic and Aortic Valve Diseases. J Clin Exp Cardiol 4: 265. doi:10.4172/2155-9880.1000265

Copyright: © 2013 Mohamed SA, et al. This is an open-access article distributed under the terms of the Creative Commons Attribution License, which permits unrestricted use, distribution, and reproduction in any medium, provided the original author and source are credited.

of the aneurysmal tissue of the aorta in MFS and the histology of the corresponding tissue in BAV. However, the current grading of aortic abnormalities during histopathological evaluation of BAV is based on conflicting reports [17]. De Sa et al. graded aneurysmatic tissue according to the severity of seven histopathological features: fibrosis, atherosclerosis, medionecrosis, cystic medial necrosis, smooth muscle cell orientation, elastic fiber fragmentation, and inflammation [18]. They found more pathological changes in aneurysmatic tissue obtained from patients with BAV compared with those of TAV patients. Other studies by Bechtel et al., found that, the ascending aorta abnormalities were more severe in TAV than in BAV [19]. These latter results correlated with recently observed results demonstrated here in Figure 1. Thus, the issue of whether the mechanisms underlying the aneurysmal histological alterations in BAV are caused by genetic heterotopy, wall stress caused by flow turbulence, or both, requires further investigation. In MFS, a mutation of the gene encoding the extracellular matrix protein fibrillin-1 has been detected. This mutation leads to dysregulation of transforming growth factor-beta (TGF- β) signaling. The discovery of fibrillins by Dietz et al. (1991) contributed to our understanding of molecular genetic causes of MFS. Dietz and his group found that a single mutation led to structural changes and caused complex diseases within various organs of the body [20]. According to Mendelian inheritance patterns, MFS is an autosomal dominant inherited disease of the extracellular connective tissue that can occur also spontaneously. Regardless of gender, MFS is diagnosed with a frequency of 1/3000 to 1/5000 [21,22]. Based on the severity of aortic wall abnormalities, further studies are needed to evaluate fibrosis, atherosclerosis, medionecrosis, cystic medial necrosis, smooth muscle cell orientation, elastic fragmentation and inflammation in aneurysmal tissue obtained from patients with MFS and BAV.

Historically, the development of aneurysms in patients with BAV was attributed to altered hemodynamic forces [23]. However, family members of patients with BAV and ascending aneurysm can show aortic dilatation without accompanying valve abnormality. It is also reported that aneurysms do progress after valve replacement in BAV patients [24]. BAV and ascending aneurysms may be variably penetrant manifestations of a common underlying gene defect. Moreover, the aortic valve and ascending aorta share a common embryonic origin; BAV may result from abnormal neural crest cell migration leading to the fusion of endocardial cushions, the precursors of the semilunar valves. Typical histopathological findings in the media of BAV-associated ascending aneurysms include elastic fiber fragmentation, increased ground substance, metalloproteinase activity, and apoptosis of vascular smooth muscle cells (VSMCs). In contrast to known connective tissue disorders, BAV is associated with dilatation above the sinotubular junction of the right antero-lateral aspect (convexity). Recent studies have indicated that aortic wall shear stress differs locally between BAV and control patients, when examined by magnetic resonance imaging [25,26]. Furthermore, two independent studies have provided evidence that VSMCs show different apoptotic behavior in the convex and opposite concave portions of the dilated aorta [27]. Inhibition of caspase-3 protected cultured cells derived from the tunica media of the concavity to a greater extent than those derived from the convexity of the aorta [28]. The convex aortic site is more prone to acute aortic dissection, which is a life-threatening condition with high morbidity and mortality rates and is generally an unpredictable event. By using a simultaneous detection system on the profiles of six MMPs and their four inhibitors at four different aortic sites (concave, convex, distal and proximal) of ascending aortic aneurysms. MMP-2, MMP-8, MMP-9, TIMP-1, TIMP-2, TIMP-3 and TIMP-4 were all detected and

quantified. This method is as accurate as older methods and minimizes the errors that can occur at the mRNA level using PCR techniques [29]. In a recent publication, Jackson and colleagues presented interesting results on the elevation of MMP-14 and -19 associated with TAV-associated thoracic aortic aneurysms, demonstrating upregulation of MMP-14 and -19 in the media of dilated aortas [30]. Of note, MMP-19 was the only MMP that was found to be upregulated in acute aortic dissection (AAD) [31]. Patients with BAV are at an increased risk of developing AAD (5 to 9 times higher than normal and 12.5 to 20.5 times higher than that of patients with MFS) [32].

In the subsequent molecular biological investigations of AAD, further genes were described, and their proteins were altered in the media layer of patients with aortic dissection. The High-mobility-group-AT-hook-2 (HMGA2) protein was detected along with SNAI1 and vimentin, a marker for the epithelial-mesenchymal-transition, in the vasa vasorum of dissection patients. HMGA2 appears so to be involved in the transformation of vasa-vasorum-endothelial cells into mesenchymal cell during AAD [33].

These studies provide new fundamental knowledge about the pathogenesis of BAV, the ascending aorta and AAD. However, present knowledge of ascending aortic aneurysms in patients with BAV reflects only a part of the complex pathogenesis process [34].

Conclusions and Future Directions

BAV presents a technical challenge in heart valve operations, with regard to how this malformation and associated diseases can be optimally corrected in a way that preserves or imitates specific physiological properties. Because approximately >50% BAV patients present with an aneurysm of the ascending aorta, it makes sense to consider potential complications associated with the replacement. Untreated aortic aneurysm can constitute a life-threatening emergency situation and can be fatal if rupture occurs. While the pathogenesis of aneurysm in patients with connective tissue disorders, such as Marfan's syndrome, is fairly well understood, the emergence of thoracic aneurysm in patients with BAV warrants further investigation. Figure 2 depicts the theoretical future direction of research on BAV.

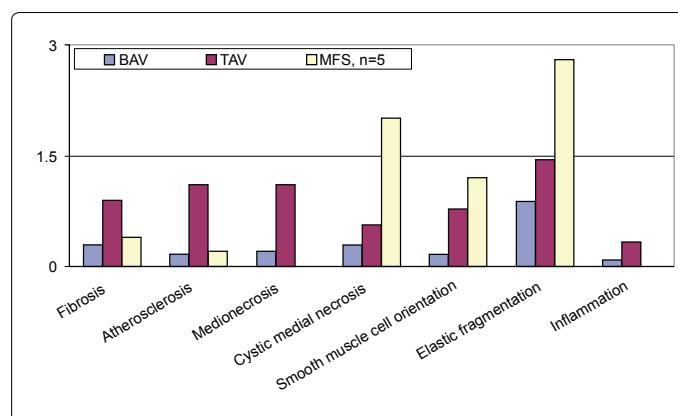
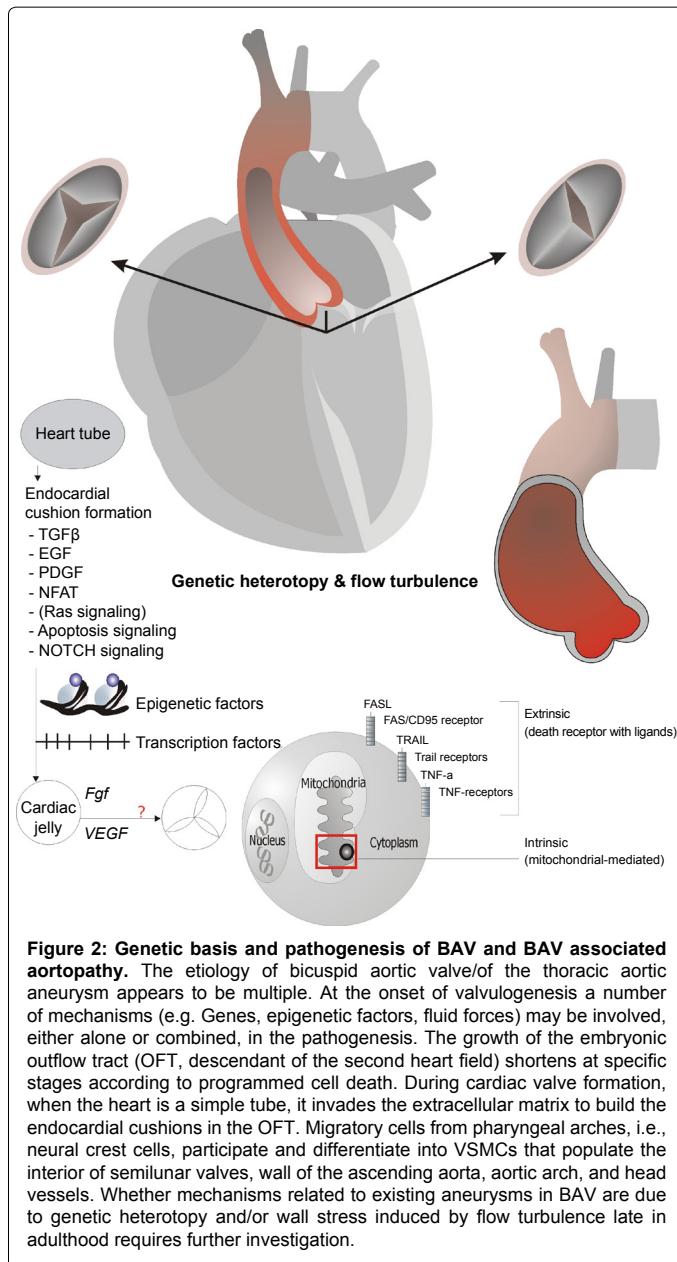


Figure 1: Comparison of histological scores. In terms of fibrosis, atherosclerosis, medionecrosis, cystic medial necrosis, smooth muscle cell orientation, elastic fiber fragmentation, and inflammation in intra-operative obtained biopsies of the sinus section of ascending aorta aneurysms: Aneurysms in the BAV-group demonstrate mild changes in the media with up to incipient moderate ones. There was a significant difference in the histological scores in terms of elastic fragmentation between the groups of TAV and MFS by $p=0.031$, but a highly significant difference was between the groups of BAV and MFS by $p<0.001$.



Acknowledgements

The authors would like to acknowledge and thank members of the Department of Thoracic and Cardiac Vascular Surgery in Luebeck. Dr. Hoepfner and his team provided support for the MassARRAY® method and MALDI-TOF mass spectrometry for analytic detection of mutations of *NOS3*. The authors would also like to acknowledge and thank the Leducq Fondation for supporting our work and giving us the opportunity to study BAV aortopathy over the coming years. We are about to commence a significant study in this area.

References

- Roberts WC (1970) The congenitally bicuspid aortic valve. A study of 85 autopsy cases. *Am J Cardiol* 26: 72-83.
- Martin LJ, Ramachandran V, Cripe LH, Hinton RB, Andelfinger G, et al. (2007) Evidence in favor of linkage to human chromosomal regions 18q, 5q and 13q for bicuspid aortic valve and associated cardiovascular malformations. *Hum Genet* 121: 275-284.
- Cripe L, Andelfinger G, Martin LJ, Shoener K, Benson DW (2004) Bicuspid aortic valve is heritable. *J Am Coll Cardiol* 44: 138-143.
- Garg V, Muth AN, Ransom JF, Schluterman MK, Barnes R, et al. (2005) Mutations in *NOTCH1* cause aortic valve disease. *Nature* 437: 270-274.
- Milewicz DM, Kwartler CS, Papke CL, Regalado ES, Cao J, et al. (2010) Genetic variants promoting smooth muscle cell proliferation can result in diffuse and diverse vascular diseases: evidence for a hyperplastic vasculomyopathy. *Genet Med* 12: 196-203.
- Mohamed SA, Hanke T, Schlueter C, Bullerdiek J, Sievers HH (2005) Ubiquitin fusion degradation 1-like gene dysregulation in bicuspid aortic valve. *J Thorac Cardiovasc Surg* 130: 1531-1536.
- Aboulhosn J, Child JS (2006) Left ventricular outflow obstruction: subaortic stenosis, bicuspid aortic valve, supravalvar aortic stenosis, and coarctation of the aorta. *Circulation* 114: 2412-2422.
- Thomas PS, Sridurongrit S, Ruiz-Lozano P, Kaartinen V (2012) Deficient signaling via *Alk2* (*Acvr1*) leads to bicuspid aortic valve development. *PLoS One* 7: e35539.
- Miller MJ, Geffner ME, Lippe BM, Itami RM, Kaplan SA, et al. (1983) Echocardiography reveals a high incidence of bicuspid aortic valve in Turner syndrome. *J Pediatr* 102: 47-50.
- Andelfinger G, Tapper AR, Welch RC, Vanoye CG, George AL Jr, et al. (2002) *KCNJ2* mutation results in Andersen syndrome with sex-specific cardiac and skeletal muscle phenotypes. *Am J Hum Genet* 71: 663-668.
- Nigam V, Sievers HH, Jensen BC, Sier HA, Simpson PC, et al. (2010) Altered microRNAs in bicuspid aortic valve: a comparison between stenotic and insufficient valves. *J Heart Valve Dis* 19: 459-465.
- Leeper NJ, Raiesdana A, Kojima Y, Chun HJ, Azuma J, et al. (2011) MicroRNA-226a is a novel regulator of vascular smooth muscle cell function. *J Cell Physiol* 226: 1035-1043.
- Aicher D, Urbich C, Zeiher A, Dimmeler S, Schäfers HJ (2007) Endothelial nitric oxide synthase in bicuspid aortic valve disease. *Ann Thorac Surg* 83: 1290-1294.
- Mohamed SA, Radtke A, Saraei R, Bullerdiek J, Sorani H, et al. (2012) Locally different endothelial nitric oxide synthase protein levels in ascending aortic aneurysms of bicuspid and tricuspid aortic valve. *Cardiol Res Pract* 2012: 165957.
- Rossi GP, Taddei S, Viridis A, Cavallini M, Ghiadoni L, et al. (2003) The T-786C and Glu298Asp polymorphisms of the endothelial nitric oxide gene affect the forearm blood flow responses of Caucasian hypertensive patients. *J Am Coll Cardiol* 41: 938-945.
- Rossi GP, Maiolino G, Zanchetta M, Sticchi D, Pedon L, et al. (2006) The T(-786)C endothelial nitric oxide synthase genotype predicts cardiovascular mortality in high-risk patients. *J Am Coll Cardiol* 48: 1166-1174.
- Roberts WC, Vowels TJ, Ko JM, Filardo G, Hebler RF Jr, et al. (2011) Comparison of the structure of the aortic valve and ascending aorta in adults having aortic valve replacement for aortic stenosis versus for pure aortic regurgitation and resection of the ascending aorta for aneurysm. *Circulation* 123: 896-903.
- de Sa M, Moshkovitz Y, Butany J, David TE (1999) Histologic abnormalities of the ascending aorta and pulmonary trunk in patients with bicuspid aortic valve disease: clinical relevance to the Ross procedure. *J Thorac Cardiovasc Surg* 118: 588-594.
- Matthias Bechtel JF, Noack F, Sayk F, Erasmi AW, Bartels C, et al. (2003) Histopathological grading of ascending aortic aneurysm: comparison of patients with bicuspid versus tricuspid aortic valve. *J Heart Valve Dis* 12: 54-59.
- Dietz HC, Pyeritz RE, Hall BD, Cadle RG, Hamosh A, et al. (1991) The Marfan syndrome locus: confirmation of assignment to chromosome 15 and identification of tightly linked markers at 15q15-q21.3. *Genomics* 9: 355-361.
- Dietz HC (1992) Molecular biology of Marfan syndrome. *J Vasc Surg* 15: 927-928.
- Dietz HC, Cutting GR, Pyeritz RE, Maslen CL, Sakai LY, et al. (1991) Marfan syndrome caused by a recurrent de novo missense mutation in the fibrillin gene. *Nature* 352: 337-339.
- Barker AJ, Lanning C, Shandas R (2010) Quantification of hemodynamic wall shear stress in patients with bicuspid aortic valve using phase-contrast MRI. *Ann Biomed Eng* 38: 788-800.
- Liu TB, Fedak PW, Weisel RD, Yasuda T, Kiani G, et al. (2004) Enhanced IGF-1

- expression improves smooth muscle cell engraftment after cell transplantation. *Am J Physiol Heart Circ Physiol* 287: H2840-2849.
25. Barker AJ, Markl M, Bürk J, Lorenz R, Bock J, et al. (2012) Bicuspid aortic valve is associated with altered wall shear stress in the ascending aorta. *Circ Cardiovasc Imaging* 5: 457-466.
26. Bissell MM, Hess AT, Biasioli L, Glaze SJ, Loudon M, et al. (2013) Aortic dilation in bicuspid aortic valve disease: flow pattern is a major contributor and differs with valve fusion type. *Circ Cardiovasc Imaging* 6: 499-507.
27. Della Corte A, Quarto C, Bancone C, Castaldo C, Di Meglio F, et al. (2008) Spatiotemporal patterns of smooth muscle cell changes in ascending aortic dilatation with bicuspid and tricuspid aortic valve stenosis: focus on cell-matrix signaling. *J Thorac Cardiovasc Surg* 135: 8-18, 18.
28. Mohamed SA, Misfeld M, Hanke T, Charitos EI, Bullerdiek J, et al. (2010) Inhibition of caspase-3 differentially affects vascular smooth muscle cell apoptosis in the concave versus convex aortic sites in ascending aneurysms with a bicuspid aortic valve. *Ann Anat* 192: 145-150.
29. Mohamed SA, Noack F, Schoellermann K, Karluss A, Radtke A, et al. (2012) Elevation of matrix metalloproteinases in different areas of ascending aortic aneurysms in patients with bicuspid and tricuspid aortic valves. *ScientificWorldJournal* 2012: 806261.
30. Jackson V, Olsson T, Kurtovic S, Folkersen L, Paloschi V, et al. (2012) Matrix metalloproteinase 14 and 19 expression is associated with thoracic aortic aneurysms. *J Thorac Cardiovasc Surg* 144: 459-466.
31. Mohamed SA, Sievers HH, Hanke T, Richardt D, Schmidtke C, et al. (2009) Pathway analysis of differentially expressed genes in patients with acute aortic dissection. *Biomark Insights* 4: 81-90.
32. Tadros TM, Klein MD, Shapira OM (2009) Ascending aortic dilatation associated with bicuspid aortic valve: pathophysiology, molecular biology, and clinical implications. *Circulation* 119: 880-890.
33. Belge G, Radtke A, Meyer A, Stegen I, Richardt D, et al. (2011) Upregulation of the high mobility group AT-hook 2 gene in acute aortic dissection is potentially associated with endothelial-mesenchymal transition. *Histol Histopathol* 26: 1029-1037.
34. Mohamed SA, Sievers HH (2011) Ascending aneurysm in bicuspid aortic valve. In: Grundmann R, editor. *Aortic aneurysm.ed*. InTech Open Access Publisher; Rijeka, Croatia.