

## Xanthoma in a Child as the First Presentation of Type One Diabetes Mellitus

Abeer Alassaf<sup>\*</sup>, Rasha Odeh and Kamal F Akl

Division of Pediatric Endocrinology, The University of Jordan, Jordan

<sup>\*</sup>Corresponding author: Abeer Alassaf, Division of Pediatric Endocrinology, The University of Jordan, Queen Rania Street, 11942, P. O. Box 13046, Amman, Jordan, Tel: 962-798-50495; E-mail: [dr\\_abeerassaf@hotmail.com](mailto:dr_abeerassaf@hotmail.com)

Rec date: Nov 19, 2014, Acc date: Dec 08, 2014, Pub date: Dec 10, 2014

Copyright: © 2014 Alassaf A, et al. This is an open-access article distributed under the terms of the Creative Commons Attribution License, which permits unrestricted use, distribution, and reproduction in any medium, provided the original author and source are credited.

### Abstract

We are reporting a case of a 12-year-old girl with xanthoma, as a very rare presentation of new onset type one diabetes in children. Xanthoma is a papular skin rash that is associated with severe hypertriglyceridemia, in our patient this was secondary to undiagnosed type one diabetes mellitus. The rash was misdiagnosed as viral illness, till she presented one month later with diabetic ketoacidosis. Xanthoma and hypertriglyceridemia completely resolved after treatment with insulin. Physicians should be aware of the cutaneous signs of systemic illnesses in order to avoid delay in the diagnosis and management; which can be detrimental. This case is the first report of a child under the age of 13 years with xanthoma, as the first presentation of new onset type one diabetes mellitus.

**Keywords:** Xanthoma; Type one diabetes; Diabetic ketoacidosis; Hyperlipidemia

### Abbreviations:

DM: Diabetes Mellitus; DKA: Diabetic Ketoacidosis; LPL: Lipoprotein Lipase

### Introduction

Cutaneous manifestations of systemic illnesses can be important alarming signs that help in preventing serious consequences of the delay in diagnosis and management. Xanthoma is a papular skin rash, which is well-described in adult population with hyperlipidemia of primary or secondary causes like those associated with uncontrolled diabetes mellitus (DM) [1,2]. In children, it is a rare manifestation of hyperlipidemia of all causes, much less secondary to uncontrolled or untreated type 1 DM [3].

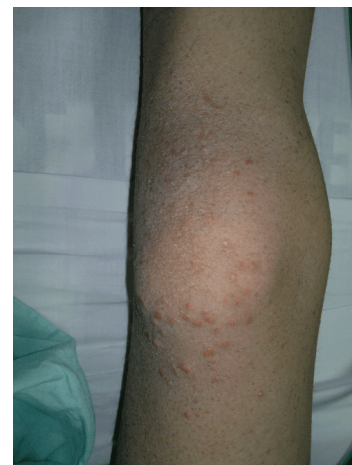
The case we are reporting with xanthoma as the first presentation of new onset type 1 DM and diabetic ketoacidosis (DKA), is extremely rare in children, and it is the first case reported in children under the age of 13 years.

### Presentation

A 12-year-old girl presented with xanthoma. She was reassured by her pediatrician that it was a self-limiting viral illness. One month later, she started to have vomiting and abdominal pain. Additionally, she had history of polyuria and polydipsia of one month duration. On physical exam, the patient was sick-looking, but stable vital signs, with body mass index of 17 kg/m<sup>2</sup>. Exam was significant for xanthoma on extensor surfaces of her knees and elbows (Figure 1). There was no lipemia retinalis.

Initial investigations led to diagnosis of diabetic ketoacidosis. Initially, it was difficult to get readings for lipid profile as blood samples withdrawn were milky indicating a profound lipemia. Treatment was started according to DKA protocol with intravenous fluids and insulin. Within the first few hours, blood gases started to

improve, so did blood glucose. Lipid profile results showed very high triglyceride level of 1113 mg/dL (NL range: 24-145 mg/dL), cholesterol 519 mg/dL (NL<199 mg/dL), LDL 183 mg/dL, (NL<100 mg/dL), HDL 50 mg/dL (NL>35 mg/dL). HbA1c was 11.7 % (NL: 4.5%-5.6%).



**Figure 1:** Xanthoma on the extensor surface of the knee.

Xanthoma started to fade away with the resolution of DKA which occurred 24 hours of starting insulin, and completely disappeared after one month. Similarly, lipid profile tests showed gradual improvement and were completely normalized within 2 weeks, and continued to be normal on subsequent clinic visits. There was no family history of hyperlipidemia except for her paternal uncle, who was diagnosed with hyperlipidemia and type 2 diabetes mellitus at the age of 50 years.

### Discussion

Eruptive xanthoma which consists of yellow-red papules distributed mainly on the extensor surfaces of limbs, is associated with profoundly elevated serum triglyceride levels that may occur with genetic hyperlipidemia or secondary to diabetes mellitus,

hypothyroidism, obesity, pancreatitis, nephrotic syndrome and cholestatic liver disease [1,2]. Although the relationship between xanthoma, hypertriglyceridemia, and diabetes may be well known in adults, in children, xanthoma is very rarely the presenting feature of diabetes of any cause [3].

We are reporting a case of a 12-year-old girl, who presented with diabetic ketoacidosis and new onset type one DM. This was preceded, one month earlier, by papular skin rash on the extensor surfaces of her knees and elbows, but was not recognized by her pediatrician at that time as xanthoma. The delay in diagnosis could be due to the rarity of xanthoma in children, especially secondary to uncontrolled or untreated diabetes [3].

Diabetic ketoacidosis is an acute life-threatening complication of diabetes mellitus. Up to 30% of patients, with newly diagnosed diabetes, present with diabetic ketoacidosis at the onset [4,5]. A mild increase in serum lipid concentrations is a common feature of uncontrolled, untreated diabetes but significant hyperlipidemia is under-reported in children [6].

To our knowledge, this is the first report in English literature, of a case with xanthoma as the first presentation of new onset type one diabetes and DKA in a child less than age 13 years. There was only one case reported in literature [7], for a 6-year-old child known to have type one diabetes and later had xanthoma and DKA due to uncontrolled diabetes, but it was not the first presentation as in our patient. A different case reported previously [8], for a 12-year-old girl with autism who had xanthoma for one year and was erroneously considered as molluscum contagiosum, but she was found to have type 2 diabetes mellitus, and she did not have DKA.

Insulin affects carbohydrate, lipid and protein metabolism. Derangement of lipid metabolism in diabetes mellitus has been known for many years [9,10]. Insulin inhibits lipolysis, decreasing the supply of free fatty acids to the liver for ketogenesis. In addition, it increases the clearance of triglyceride-rich chylomicrons from the circulation by stimulating lipoprotein lipase (LPL), which breaks down triglycerides into monoglycerides, fatty acid and glycerol [6,11].

Under hypoinsulinemic conditions, such as uncontrolled or untreated diabetes mellitus, lipolysis is increased and causes an oversupply of free fatty acids to the liver, leading to hyperlipidemia. Patients presenting with diabetic ketoacidosis have an absolute insulin deficiency that can result in severe hyperlipidemia as seen in our patient [12,13].

Since children with type 1 diabetes rarely have such high triglyceride level, this may suggest the presence of LPL deficiency or deficiency of apolipoprotein CII [14]. In the unlikely event that pronounced hypertriglyceridemia persisted after successful treatment of the diabetic ketoacidosis then these genetic disorders would need to be considered [15]. Further work is required to determine whether more modest levels of hypertriglyceridemia with DKA are also associated with heterozygous mutations of the LPL gene [16].

Genetic testing for our patient was not done as lipid profile normalized rapidly with insulin treatment. Nevertheless, there is a rare possibility that she may have one of the very rare mutations in LPL gene, in addition she may be predisposed to familial hereditary combined hyperlipidemia during adulthood, which necessitates long term close follow up for her lipid profile.

## Conclusion

Severe hyperlipidemia causing xanthoma and lipemic serum in patients with diabetic ketoacidosis and newly diagnosed type one DM has not been reported previously in children under the age of 13 years.

This case acknowledges the rarity of type one diabetes mellitus presenting with xanthoma in children. We do believe that this report will help in increasing the awareness of physicians for such a rare presentation in the pediatric population, in order to decrease the morbidity and mortality caused by delayed diagnosis.

## References

1. Parker F (1985) Xanthomas and hyperlipidemias. *J Am Acad Dermatol* 13: 1-30.
2. Robson KJ, Piette WW (1998) Cutaneous manifestations of systemic diseases. *Med Clin North Am* 82: 1359-1379, vi-vii.
3. Jetha MM, Fiorillo L (2012) Xanthomata and diabetes in an adolescent with familial dysbetalipoproteinemia 9 yr after valproate-induced pancreatitis. *Pediatr Diabetes* 13: 444-447.
4. Rewers A, Klingensmith G, Davis C, Pettitt DB, Pihoker C, et al. (2008) Presence of diabetic ketoacidosis at diagnosis of diabetes mellitus in youth: the Search for Diabetes in Youth Study. *Pediatrics* 121: e1258-1266.
5. Smith CP, Firth D, Bennett S, Howard C, Chisholm P (1998) Ketoacidosis occurring in newly diagnosed and established diabetic children. *Acta Paediatr* 87: 537-541.
6. Waseem M, Dave-Sharma S, Kin LL, Jara F (2012) Lipemic serum in a toddler with new-onset diabetes mellitus presenting with diabetic ketoacidosis. *JOP* 13: 73-75.
7. Batra P, Singhal R, Shah D (2014) Diabetic lipemia presenting as eruptive xanthomas in a child with autoimmune polyglandular syndrome type IIIa. *J Pediatr Endocrinol Metab* 27: 569-571.
8. Sorrell J, Salvaggio H, Garg A, Guo L, Duck SC, et al. (2014) Eruptive xanthomas masquerading as molluscum contagiosum. *Pediatrics* 134: e257-260.
9. Potter JL, Stone RT (1975) Massive hyperlipidemia in diabetic ketoacidosis. The clinical importance of laboratory recognition. *Clin Pediatr (Phila)* 14: 412-413.
10. Nyamugunduru G, Roper H (1997) A difficult case. Childhood onset insulin dependent diabetes presenting with severe hyperlipidaemia. *BMJ* 314: 62-65.
11. Farese RV Jr, Yost TJ, Eckel RH (1991) Tissue-specific regulation of lipoprotein lipase activity by insulin/glucose in normal-weight humans. *Metabolism* 40: 214-216.
12. Hsu JH, Wu JR, Chao MC, Dai ZK, Chiou SS, et al. (2006) Severe hyperlipidaemic pancreatitis associated with diabetes. *Acta Paediatr* 95: 378-379.
13. Shenoy SD, Cody D, Rickett AB, Swift PG (2004) Acute pancreatitis and its association with diabetes mellitus in children. *J Pediatr Endocrinol Metab* 17: 1667-1670.
14. Karagianni C, Stabouli S, Roumeliotou K, Traeger-Synodinos J, Kavazarakis E, et al. (2004) Severe hypertriglyceridaemia in diabetic ketoacidosis: clinical and genetic study. *Diabet Med* 21: 380-382.
15. Nyamugunduru G, Roper H (1997) A difficult case. Childhood onset insulin dependent diabetes presenting with severe hyperlipidaemia. *BMJ* 314: 62-65.
16. McLean AG, Petersons CJ, Hooper AJ, Burnett JR, Burt MG, et al. (2009) Extreme diabetic lipaemia associated with a novel lipoprotein lipase gene mutation. *Clin Chim Acta* 406: 167-169.