

## Unusual Presentations in Pediatric HIV: Case Series

Isaac Oluware Oluwayemi\*, Ezra Olatunde Ogundare, Oyeku Akibu Oyelami, Adebukola Bidemi Ajite and Simeon Oladele Olatunya

Department of Pediatrics, Ekiti State University, Nigeria

\*Corresponding author: Isaac Oluware Oluwayemi, Department of Pediatrics, Faculty of Clinical Sciences, College of Medicine, Ekiti State University, Ado-Ekiti, Ekiti State, Nigeria, Tel: +234 8034 052 536; E-mail: isaac.oluwayemi@eksu.edu.ng

Rec date: Jul 23, 2015, Acc date: Aug 10, 2015, Pub date: Aug 12, 2015

Copyright: © 2015 Oluwayemi IO, et al. This is an open-access article distributed under the terms of the Creative Commons Attribution License, which permits unrestricted use, distribution, and reproduction in any medium, provided the original author and source are credited.

### Abstract

We report two children on treatment for HIV disease who presented differently with difficulty in breathing and on further investigation were found to have lymphocytic interstitial pneumonia (LIP) and rheumatic heart disease respectively. The first patient's diagnosis was made with chest x-ray features suggestive of LIP and she was commenced on low dose steroid in addition to antiretroviral therapy. Her condition improved marginally before she died at home one month after. The second patient was initially thought to have pneumonia in heart failure, but when CXR showed an enlarged globular heart a suspicion of pericardial effusion was entertained. This necessitated Echocardiography which confirmed diagnosis of rheumatic heart disease (severe mitral valve regurgitation) with moderate pulmonary hypertension and moderate pericardial effusion. She also died at home. These cases are being reported to highlight the importance of thorough evaluation of HIV positive patients for other co-morbidities and the negative impact of poverty on their survival.

**Keywords:** HIV; Children; Diagnosis

### Introduction

HIV infection is a disease of public health importance and because it is an immunosuppressive condition patients often present with many non-specific clinical features. Children in developing countries often present late and the possibility of inadvertently overlooking other disease conditions that may likely compromise their growth and development is very high once the child is diagnosed to be HIV-positive. Lymphocytic interstitial pneumonia is regarded as both a disease and a non-neoplastic, inflammatory pulmonary reaction to various external stimuli or systemic diseases [1]. The incidence and prevalence of LIP, a relatively uncommon condition, is largely unknown [1]. LIP may be associated with autoimmune and lymphoproliferative disorders, allogeneic bone marrow transplantation, lupus, and lymphoma [1,2]. Dysproteinemia has also been reported in association with LIP [3,4]. Rheumatic heart disease is a dying disease, because of improvement in accommodation and access to use of antibiotics over the years. However, in places where poverty and overcrowding is still prevalent, rheumatic fever following group A  $\beta$  hemolytic streptococcal pharyngitis can progress to debilitating rheumatic heart disease, as seen in our patient.

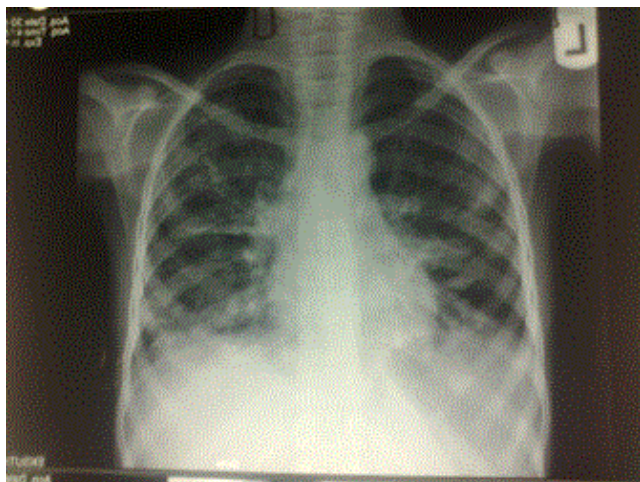
### Patients and Case Report

O.P.T. was a 10 year old girl who presented for the first time at Ekiti State University Teaching Hospital (EkSUTH) on 30th March, 2015 with 2 month history of cough and 5 days history of fever and right ear discharge. Cough was non-paroxysmal, progressively worsening since onset; associated with progressive weight loss despite regular and adequate feeding. She also had fever which was on and off, usually above 4 hour daily and purulent right ear discharge. Retroviral screening was reactive hence referral to EkSUTH. Her parents had separated since child was 3 years old, father died 2 months earlier (cause of death not known). Mother is a 38 years old seamstress with

secondary school education. Child was the only child of the mother. Essential findings at presentation include a chronically ill looking girl, underweight 20 kg (61.5% of expected weight for age), febrile (38.1°C), had grade 3 digital clubbing, whitish plaque in the mouth (oral thrush), multiple healed septic spots on the extremities; had dyspnoea and tachypnoea (RR=80 cycles/minute), resonant percussion note, vesicular breath sound; tachycardia (HR=160 beats/minute), normal heart sounds; liver was palpably enlarged to 6cm below the right costal margin, firm and not tender. An assessment of HIV infection stage 3 was made. She had normal hematocrit (PCV=32%), very low CD4 count (3 cells/ $\mu$ L of blood), leucocytosis (31.1 $\times$ 10<sup>9</sup>/L), sputum was negative for acid fast bacilli, chest x-ray (Figure 1) showed reticulo-nodular pulmonary infiltrates. Patient had to be managed on out-patient basis because mother declined admission due to financial constraint. She was commenced on antiretroviral therapy (ART), Co-trimoxazole, and oral Nystatin. Patient was also placed on low dose steroid (prednisolone 10 mg bd) for the suspected lymphoid interstitial pneumonitis. Patient had slight improvement in cough, however weight remained static at 20 kg for 2 weeks when she was last seen in ART clinic. She died at home before the next scheduled clinic visit. We were informed about her demise through phone call (Figure 1).

J.M.I. was a 4 year old girl who first presented at EkSUTH on 24th October, 2014 with one year history of recurrent fever and progressive weight loss, 4 days history of cough, chest pain and vomiting. Fever was on and off while weight loss was progressively worsening with suboptimal appetite. Chest pain was dull and generalized; denied history of trauma. Vomiting was mainly post prandial. She was the third of 3 children of her mother in a polygamous family setting. The parents were separated. The father was a police officer. Her mother was HIV-positive; the two older siblings are HIV negative and the HIV status of the father was not known. Essential findings on examination included an acute on chronically ill looking girl, underweight 13 kg (72% of expected) mildly pale, afebrile (36°C), she had no sign of dehydration, there was significant peripheral lymph nodes

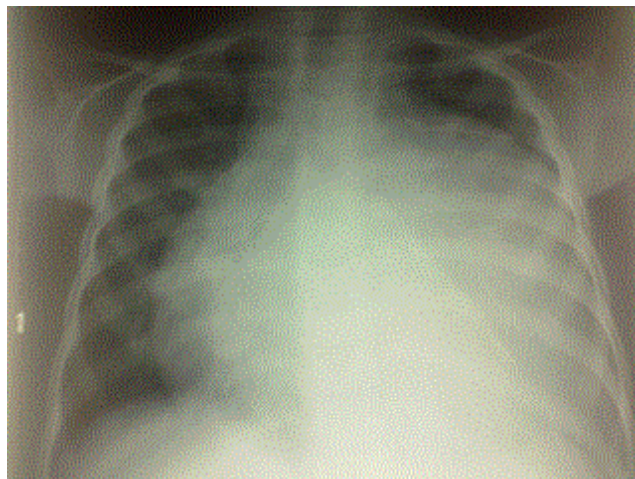
enlargement. She had tachypnoea (RR=52 cycles/minute), crepitations in both lung bases; tachycardia (HR=140 beats/min).



**Figure 1:** Chest x-ray showing reticulo-nodular infiltrates in keeping with LIP.

Liver was palpably enlarged to 4 cm below the right costal margin, smooth, not tender. An initial assessment of HIV infection stage II and Pneumonia not in heart failure was made. HIV test was positive; Mantoux test was negative; she had very low CD4 count of 26 cells/ $\mu$ L of blood; mildly anaemic (packed cell volume=28%); leucocytosis of  $21.5 \times 10^9$  c/L and neutrophilia of 84%. The child was commenced on ART, Co-trimoxazole (prophylaxis for *Jerovaci* pneumonia) and amoxicillin-clavulanate. She made some improvement as evidenced by improvement in the weight from 13 kg to 15 kg over 5 months period of treatment. However, 6 month into treatment with ART, she presented with fever, cough, generalized body swelling, reduction in urinary output and difficulty in breathing of 5 days duration. On examination she had dyspnoea, respiratory rate was 42cycles/minute, percussion note was dull on right hemithorax with bronchial breath sound posteriorly medial to the scapular, and crepitations bilaterally; BP=90/64 mmHg; HR=126 beats/minute, normal first and second heart sounds as well as grade 4/6 systolic murmur. Liver was palpably enlarged to 10cm below the right costal margin, firm, not tender. There was demonstrable ascites by fluid thrill. An assessment of Retroviral disease with pneumonia and chronic heart failure was made. The patient was admitted into children emergency ward. She had normal random blood glucose of 3.1mmol/L; normal SPO<sub>2</sub> of 93%; normal PCV of 43%; normal electrolyte, urea & creatinine (Cl=110.3, Na=133.1, k=4.06, Urea 5.2, Creatinine=32.7 mmol/L); normal urinalysis and negative blood film for malaria parasite. The chest X-ray (Figure 2) showed a markedly enlarged globular heart, some patchy opacities in the right lung field. Echocardiography (paid for by the doctors in a quest to get to the root of the problem) showed features of rheumatic mitral valve disease with severe mitral regurgitation, moderate pulmonary hypertension, and moderate pericardial effusion. The patient was treated with intravenous cefuroxime, and frusemide in addition to routine oral ART and cotrimoxazole. She made remarkable improvement and was discharged home after 8 days on oral cefuroxime, enalapril, hydrochlorothiazide. She was also referred to the University College Hospital, Ibadan for definitive treatment of the Rheumatic heart

disease. Patient however could not go because of financial constraint (her hospital bill had to be off-set by the hospital management when she could not pay after discharge). We heard about a month later that the child died when asked after from the mother who came to collect her routine ART drugs at the adult ART clinic.



**Figure 2:** chest x-ray showing an enlarged globular heart in a patient with HIV.

## Discussion

HIV/AIDS is a disease of public health importance and mother to child transmission is one of the major routes of spread of the virus [5]. The prevalence of DNA PCR reactivity among HIV-exposed infants in EksUTH, Ado-Ekiti, Nigeria was 6.3% [6]. About 330,000 children under the age of 15 became infected with HIV in the year 2012 worldwide according to recent estimates by the Joint United Nations Program (UNAIDS) on HIV/AIDS with more than 90 percent of paediatric HIV infections occurring in sub-Saharan African countries [5].

LIP is known to be associated with infection by human immunodeficiency virus (HIV) type 1, Epstein-Barr virus, and human T-cell lymphotropic virus (HTLV) type 1 [1,7-9]. HIV positive children are particularly prone to developing LIP and the symptoms of progressive cough and dyspnea predominate [1]. The symptoms of our patient matched the predominant symptom of LIP. Laboratory test results are nonspecific for LIP. The most essential items in making diagnosis are the chest radiograph, measurement of gas exchange, and histology. The typical chest x-ray finding of bibasilar interstitial or micronodular infiltrates with coalescence into an alveolar pattern are present (Figure 1). Grade 3 digital clubbing in this patient could be a pointer to chronic hypoxemia in the patient. There is great variability in the clinical course of LIP, from resolution without treatment to progressive respiratory failure and death [1]. Other factors that might have contributed to early death of our patient despite treatment include late presentation, abject poverty, chronic malnutrition, very low CD4 count and single parenthood. This case is an example of so many HIV infected children in developing countries dying because of lack of necessary social support and is a call for help and intensified effort from local and international support groups [10]. Also, there is need for proper monitoring of the aids being provided presently.

The second HIV positive patient with Rheumatic heart disease is a call for thorough evaluation of every patient diagnosed with HIV who is also presenting with features pointing to specific organ dysfunction. Early identification, diagnosis and management of other co-morbidities in HIV-positive children will greatly enhance their survival. Failure to identify and treat these co-morbidities will result in wasted effort and resources. Health workers need to be reminded that HIV-positive children like other children can have non-HIV related diseases which must be looked for and promptly treated.

## References

1. Swigris JJ, Berry GJ, Raffin TA, Kuschner WG (2002) Lymphoid interstitial pneumonia: a narrative review. *Chest* 122: 2150-2164.
2. Tokuyasu H, Watanabe E, Okazaki R, Kawasaki Y, Kikuchi R, et al. (2007) Sjögren's syndrome with multiple bullae caused by lymphocytic interstitial pneumonia. *Lung* 185: 187-188.
3. Greenberg SD, Haley MD, Jenkins DE, Fischer SP (1973) Lymphoplasmacytic pneumonia with accompanying dysproteinemia. *Arch Pathol* 96: 73-80.
4. Liebow AA, Carrington CB (1973) Diffuse pulmonary lymphoreticular infiltrations associated with dysproteinemia. *Med Clin North Am* 57: 809-843.
5. Dube Q, Dow A, Chirambo C, Lebov J, Tenthani L, et al. (2012) Implementing early infant diagnosis of HIV infection at the primary care level: experiences and challenges in Malawi. *Bull World Health Organ* 90: 699-704.
6. Oluwayemi IO, Olatunya SO (2015) PCR Results and PMTCT Treatment Outcomes among HIV-Exposed Infants in a Tertiary Hospital in Nigeria, 2010-2014. *IJMA* 3: 168-173.
7. Grieco MH, Chinoy-Acharya P (1985) Lymphocytic interstitial pneumonia associated with the acquired immune deficiency syndrome. *Am Rev Respir Dis* 131: 952-955.
8. Lin RY, Gruber PJ, Saunders R, Perla EN (1989) Lymphocytic interstitial pneumonitis in adult HIV infection. *AIDS* 1989: 129-132.
9. Zar HJ (2008) Chronic lung disease in human immunodeficiency virus (HIV) infected children. *Pediatr Pulmonol* 43: 1-10.
10. Azuine RE, Singh GK, Ekejiuba SE, Ashu E, Azuine MA (2014) Global Health Donor Presence, Variations in HIV/AIDS Prevalence, and External Resources for Health in Developing Countries in Africa and Asia. *IJMA* 2: 190-199.