

Tubo-Ovarian Abscess after Uterine Artery Embolization for Uterine Fibroid

Aska Toda¹, Kenjiro Sawada^{1*}, Keigo Osuga², Noboru Maeda², Hiroki Higashihara², Eiji Kobayashi¹, Kaori Koizumi¹, Naoya Shigeta¹, Noriyuki Tomiyama² and Tadashi Kimura¹

¹Departments of Obstetrics and Gynecology, Osaka University Graduate School of Medicine, 2-2 Yamadaoka, Suita, Osaka, Japan

²Department of Diagnostic and Interventional Radiology, Osaka University Graduate School of Medicine, 2-2 Yamadaoka, Suita, Osaka, Japan

Abstract

Tubo-ovarian abscess is a rare but potentially serious event that can occur after uterine artery embolization (UAE). We describe herein two cases of severe inflammatory tubo-ovarian abscesses. Two women presented with severe abdominal pain, cramping, and fever several months after UAE. Abdominal computed tomography demonstrated an enlarged tubo-ovarian mass, suggestive of an abscess. Percutaneous catheter drainage was performed. In one patient, tubo-ovarian abscess completely disappeared after the drainage, but the other patient eventually required hysterectomy and salpingo-oophorectomy. It is important for clinicians to be aware of tubo-ovarian abscess as a rare complication. Percutaneous drainage might be a useful treatment option.

Keywords: UAE; Tubo-ovarian abscess; Drainage

Introduction

Uterine leiomyomas are the most common solid pelvic tumors in women. Since the initial report of Ravina et al. [1] in 1995, uterine artery embolization (UAE) has emerged as an effective noninvasive treatment option for women with symptomatic leiomyomas. The average reduction in myoma volume is approximately 30–50%, with improvement in the symptoms and menorrhagia in more than 90% of patients. Approximately 90% of patients do not experience complications, and serious complications are reportedly rare [2]. In a recent comprehensive review including 7 randomized controlled trials (RCTs) with 793 women, UAE has been shown to be a safe, minimally invasive alternative to surgery, while patient selection and counselling should be considered due to a higher risk of requiring future surgical intervention [3]. Herein, we report two cases of severe pelvic inflammatory disease complicated by tubo-ovarian abscesses after UAE and thus required inpatient admission.

Case 1

A 41-year-old nulliparous woman presented with severe menorrhagia and anemia (hemoglobin level, 7.9 g/dL) caused by symptomatic uterine fibroids. She has a history of several surgeries, including abdominal myomectomy at the age of 31 years and abdominal left salpingo-oophorectomy for left tubo-ovarian abscess at the age of 37 years. She declined definitive surgical therapy and was referred for UAE. Through preprocedural magnetic resonance imaging (MRI), a 14 cm dominant intramural fibroid and other multiple fibroids with a right hydrosalpinx were confirmed. She underwent bilateral UAE with porous gelatin particles (Gelpart, Nippon Kayaku, Tokyo, Japan; 1 mm porous, 120 mg and 2-mm porous, 140 mg), without adverse events and immediate complications. She was administered prophylactic intravenous antibiotics (cefazolin) before the procedure and oral antibiotics (amoxicillin) for 3 days after the procedure. She was admitted for pain management and discharged within 72 hours.

Six months after the UAE, she presented to our emergency department with severe abdominal pain and cramping. On physical examination, tenderness, which was the size of a child's head, over the uterus and right adnexa were noted. Pelvic computed tomography (CT) revealed a bulky, 11 × 8 cm necrotic-appearing fibroid and a thick-walled multilocular right adnexal mass that measured 12.5 × 9.5 cm, suggestive of an abscess. She was admitted and managed conservatively

with intravenous broad-spectrum antibiotics (meropenem), as her blood culture results were positive for *Bacteroides fragilis* infection. Three days after administering intravenous (i.v.) antibiotics, she became afebrile and showed no peritoneal signs, or leukocytosis or anemia. However, 22 days later, she presented with a recurrent right lower abdominal pain, foul-smelling vaginal discharge, fever, and chills. Thus, the administration of i.v. antibiotics (meropenem) was restarted. Her white blood cell count elevated to 28,000/μL, with a left shift (neutrophil level, 91.5%). Because of her persistent symptoms (fever and abdominal pain) and her strong refusal to undergo surgical therapy, CT-guided percutaneous drainage of the right adnexal mass was performed by interventional radiologists and a drainage catheter was placed (Figure 1). A total of 600 mL of purulent fluid was discharged, and the anaerobic gram-negative rods *Bacteroides* was identified in the drainage fluid. Her symptoms seemed to improve drastically, and her white blood cell count returned within its normal range. Even though the diameter of the right adnexal mass had decreased to half, a second drainage was performed on day 29 because the mass was multicystic and persistent. For 8 days, she had been afebrile, without peritoneal signs and leukocytosis. The drainage catheter was removed on day 37, and oral minocyclines were prescribed. However, on the day after the second drainage catheter was removed, she developed an uncontrollable abdominal pain and became febrile. She finally consented to undergo surgery, and a laparotomy was performed on day 39. The surgical findings were as follows: uterus, the size of a newborn's head; rectum and sigmoid colon firmly adhering the posterior uterine wall; a fist-sized right adnexa adhering the uterus; an enlarged vermiform appendix; and dense pelvic and abdominal adhesions. The left adnexa was previously removed. The patient underwent total abdominal hysterectomy, right salpingo-oophorectomy, appendectomy, and

***Corresponding author:** Kenjiro Sawada, Department of Obstetrics and Gynecology, Osaka University Graduate School of Medicine, 2-2, Yamadaoka Suita, Osaka 5650871, Japan, Tel: 81-6-6879-3351; Fax: 81-6-6879-3359; E-mail: daasawada@gyne.med.osaka-u.ac.jp

Received July 11, 2015; Accepted July 22, 2015; Published July 29, 2015

Citation: Toda A, Sawada K, Osuga K, Maeda N, Higashihara H, et al. (2015) Tubo-Ovarian Abscess after Uterine Artery Embolization for Uterine Fibroid. Gynecol Obstet (Sunnyvale) 5: 306. doi:10.4172/2161-0932.1000306

Copyright: © 2015 Toda A, et al. This is an open-access article distributed under the terms of the Creative Commons Attribution License, which permits unrestricted use, distribution, and reproduction in any medium, provided the original author and source are credited.

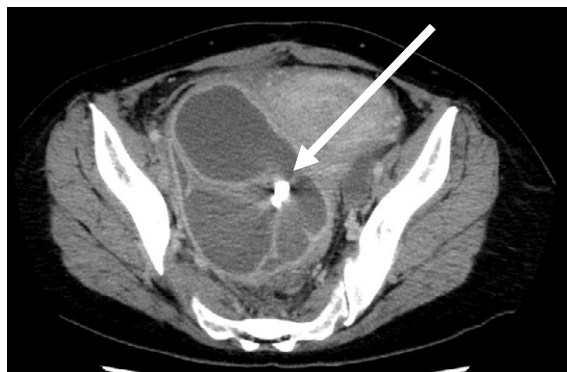

Figure 1: Computed tomography scan of the pelvis showing the fluid-containing right adnexal cyst, suggestive of an abscess. The arrow indicates the inserted catheter.

adhesiolysis. The enlarged uterus with the firmly adherent right adnexa was removed (Figure 2). Histopathological examination confirmed a tubo-ovarian abscess of the right fallopian tube and ovary and leiomyoma of the uterine corpus with necrosis. In her appendix, moderate infiltrations of leukocytes as well as histiocytes were found in serosa; however minimal neutrophils in muscularis propria were found, suggesting that this inflammation is caused by neighboring adnexa. The postoperative course was uneventful, and the patient was discharged in good condition on postoperative day 14. At 9 months' follow-up, no evidence of recurrent pelvic infection or other sequelae were found.

Case 2

A 47-year-old nulliparous woman presented with a symptomatic fibroid uterus, which caused menorrhagia, dysmenorrhea, and bulk-related symptoms (frequent urination). She had a history of appendectomy for appendicitis at the age of 9 years, which was complicated by peritonitis, and laparotomy for ileus at the age of 10 years. She also had asymptomatic bilateral adnexal masses, for which she had undergone follow-up for approximately 10 years, with the presumptive diagnosis of endometriotic cysts. She declined definitive surgical therapy, and was referred for UAE. Preprocedural pelvic MRI confirmed that the uterus had grown to more than the size of a newborn's head, and an 8 cm intramural anterior dominant fibroid and a 5 cm right and 4 cm left endometriotic cyst also present. She underwent a bilateral UAE with porous gelatin particles (Gelpart; 1 mm particles at 160 mg and 2 mm particles at 36 mg), without adverse events and immediate complications. She was administered prophylactic intravenous antibiotics (cefazolin) before the procedure and oral antibiotics (amoxicillin) for 3 days after the procedure. She was admitted for pain management and discharged within 72 hours.

Five months later, the patient presented to our emergency department with a 2 day history of right lower abdominal pain and fever. A strong tenderness was observed around the right adnexal lesion, and transvaginal ultrasonography and CT revealed an enlarged right adnexa that measured 7 cm and wall thickening of the fallopian tube, suggestive of a tubo-ovarian abscess (Figure 3). Her white blood cell count elevated to 11,200/ μ L, with a left shift (neutrophil level, 79.7%). She was admitted, and under ultrasonography guidance, a percutaneous drainage catheter was placed into the abscess, and brown serous fluid was drained. *Streptococcus agalactiae* was identified in the drainage fluid. She was treated with intravenous ampicillin, gentamycin, and clindamycin, and then transitioned to oral

sitafloxacin. On hospital day 14, the size of the cavity reduced, and the culture test of yellow serous sample was negative. On hospital day 20, the drainage catheter was removed, and the patient was discharged in good condition. At 5 months' follow-up, a pelvic MRI revealed that the multiple-fibroid uterus, as well as the left endometriotic cyst was reducing in size. No right adnexal mass was detected. She had been in good condition throughout the follow-up period.

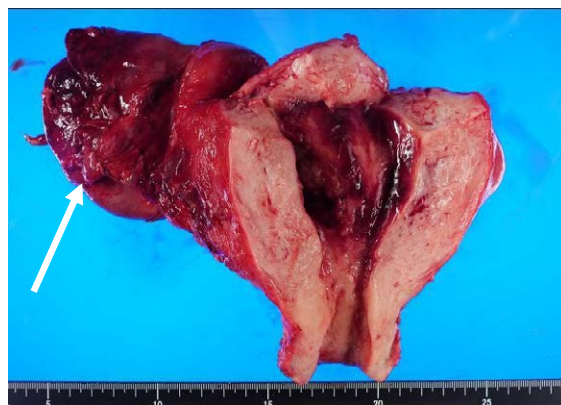


Figure 2: Gross photo of the uterine specimen containing the infarcted necrotic leiomyoma with an enlarged right adnexa, consistent with the finding of a tubo-ovarian abscess (arrow).

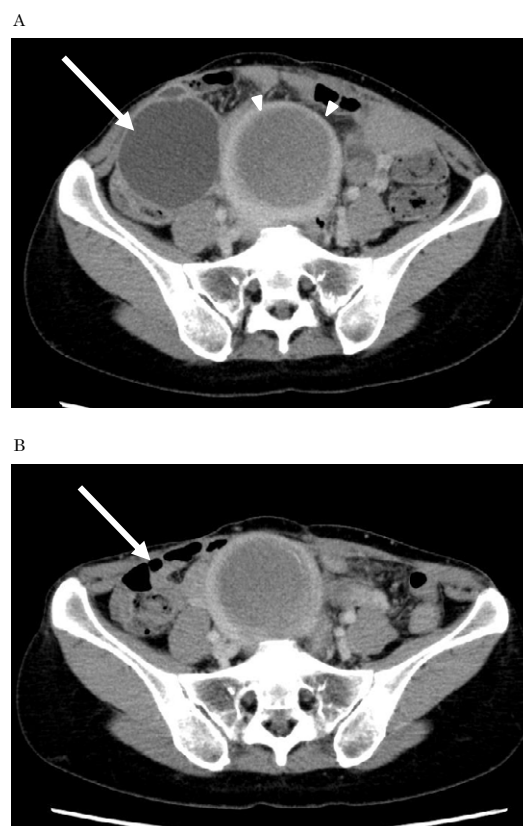


Figure 3: Computed tomography scan of the pelvis. A: Pre-drainage examination shows the right adnexal mass with wall thickening (arrow) and an infarcted myoma (arrow heads). B: Post-drainage examination shows resolution of the previously seen right adnexal mass (arrow).

Discussion

Currently, UAE is a frequently performed alternative to surgical intervention for the management of symptomatic uterine fibroids. In general, it is associated with a good success rate in appropriately selected patients, and severe complications such as pelvic infection and death have been reported but are rare [2]. Although infectious complications after UAE have been reported in 1% to 2% of cases [4], most of the cases had related uterine infections. In a recent meta-analysis of 76 non-randomized studies, while the incidence of uterine infection was 1.39% (155/11,195), only one case of tubo-ovarian abscess was reported [5]. Herein, we report two cases of serious tubo-ovarian abscess that required intensive therapies.

The risk factors of tubo-ovarian abscess generally include having multiple sex partners, age between 15 and 25 years, and a history of pelvic inflammatory disease [6]. Tubo-ovarian abscess may also develop from local spread of infection associated with uncontrolled inflammatory bowel disease, appendicitis, or adnexal surgery [6]. Both of our cases had a history of previous surgeries. UAE likely causes ischemia of the fallopian tube that increases the propensity of microbes to ascend the tract easily and cause endothelial damage, leading to a tubo-ovarian abscess [7].

Case 1 had a right hydrosalpinx, and case 2 had bilateral endometriotic cysts. It remains controversial whether a preexisting adnexal mass is a predisposing factor. Nikolic et al. [8] reported a case of pyosalpinx 8 weeks after UAE in a patient with preexisting hydrosalpinx, which required treatment with hysterectomy and oophorectomy. Walker et al. [9] reported a case that required hysterectomy and salpingo-oophorectomy because of a large tubo-ovarian abscess with histological evidence of endometriosis. In contrast, Petruzzi et al. reported that 16 patients with preexisting hydrosalpinx successfully underwent bilateral UAE, with no clinical evidence of pyosalpinx after the procedure [10]. They commented that UAE is safe for patients and may not impose an increased risk of infection. Further accumulation of clinical evidences would be needed to discuss whether UAE should be contraindicated in cases with hydrosalpinx or ovarian endometrioma.

In our cases, a percutaneous drainage catheter was placed to avoid an undesirable laparotomy. In case 2, the tubo-ovarian abscess successfully resolved after the drainage, and no other sequelae were

noted. Considering that laparotomy in patients with tubo-ovarian abscesses followed by a previous history of several surgeries potentially carries a high risk of complications such as perforation of the surrounding organs, we assume that such a drainage technique should be considered as an initial step. At least, it helps clinicians to identify the pathogen promptly and to start appropriate antibiotic treatment.

In conclusion, it is important for all physicians, including interventional radiologists, emergency physicians, and gynecologists, to be aware of a tubo-ovarian abscess as a potential complication, especially in patients with surgical histories or preexisting adnexal masses. Percutaneous drainage, if possible, is potentially useful as an initial treatment option for this infectious disease.

References

1. Ravina JH, Herbreteau D, Ciraru-Vigneron N, Bouret JM, Houdart E, et al. (1995) Arterial embolisation to treat uterine myomata. *Lancet* 346: 671-672.
2. Spies JB, Spector A, Roth AR, Baker CM, Mauro L, et al. (2002) Complications after uterine artery embolization for leiomyomas. *Obstet Gynecol* 100: 873-880.
3. Gupta JK, Sinha A, Lumsden MA, Hickey M (2014) Uterine artery embolization for symptomatic uterine fibroids. *Cochrane Database Syst Rev* 12: CD005073.
4. Rajan DK, Beecroft JR, Clark TW, Asch MR, Simons ME, et al. (2004) Risk of intrauterine infectious complications after uterine artery embolization. *J Vasc Interv Radiol* 15: 1415-1421.
5. Martin J, Bhanot K, Athreya S (2013) Complications and reinterventions in uterine artery embolization for symptomatic uterine fibroids: a literature review and meta analysis. *Cardiovasc Intervent Radiol* 36: 395-402.
6. Chappell CA, Wiesenfeld HC (2012) Pathogenesis, diagnosis, and management of severe pelvic inflammatory disease and tuboovarian abscess. *Clin Obstet Gynecol* 55: 893-903.
7. Granberg S, Gjelland K, Ekerhovd E (2009) The management of pelvic abscess. *Best Pract Res Clin Obstet Gynaecol* 23: 667-678.
8. Nikolic B, Nguyen K, Martin LG, Redd DC, Best I, et al. (2004) Pyosalpinx developing from a preexisting hydrosalpinx after uterine artery embolization. *J Vasc Interv Radiol* 15: 297-301.
9. Walker WJ, Pelage JP (2002) Uterine artery embolisation for symptomatic fibroids: clinical results in 400 women with imaging follow up. *BJOG* 109: 1262-1272.
10. Petruzzi NJ, McCann JW, Patel NA, Gonsalves CF (2012) Safety of uterine artery embolization in patients with preexisting hydrosalpinx. *J Vasc Interv Radiol* 23: 796-799.