

Treatment of Temporomandibular Disorder Using Synergistic Laser and Ultrasound Application

Vitor Hugo Panhóca, Larissa Biason Lopes, Fernanda Rossi Paolillo, Vanderlei Salvador Bagnato

São Carlos Institute of Physics, University of São Paulo, São Carlos, São Paulo, Brazil

Abstract

The aim of this study was to present a clinical case showing the effects of an innovative device that applies low power laser and ultrasound for the rehabilitation of a voluntary patient with temporomandibular disorder (TMD). The aim of this therapy is to reduce muscle and joint pain and increase joint functionality, thus improving the quality of life of the patient. ATS, the voluntary patient, a female Caucasian who is 27 years old, was selected as being apt to receive the TMD treatment after undergoing a clinical assessment according to the Research Diagnostic Criteria for TMD (RDC/TMD). In this study, two therapeutic sessions were carried out per week for 4 weeks, followed by an assessment of the initial pain: ($t=0$), at the end of 8 clinical sessions ($t=1$) and 30 days after the end of the treatment ($t=2$). During the clinical assessments, data was collected, using the analogue scale for pain and oral quality of life questionnaire [Oral Health Impact Profile (OHIP-14)] in the pre- and post-treatment periods. Thermographic images were also taken. The results showed reduced pain and improved quality of life. It can be concluded that the synergistic effect of applying laser with ultrasound has a potential effect on the treatment of TMD.

Key Words: Low power laser, Ultrasound, Temporomandibular disorder, Thermography

Introduction

Temporomandibular Disorder (TMD) is a condition that has a high impact on the world population affecting millions of people in Brazil. Recent research has related TMD to individuals with anxiety disorders and also to genetic predisposition in individuals who present this disorder related to the temporomandibular joint. TMD is a condition that initially presents acute or transient pain that can become a disease with chronic or persistent pain [1].

The first interest in studying TMD began in 1934 with the otolaryngologist James Costen [2]. Epidemiological studies concerning TMD are thanks to the Scandinavian school which were carried out in 1974 by Helkimo [3]. In 1990, studies conducted by Dworkin et al. showed some difficulties in obtaining similar methodologies among the studies to validate TMD treatments [4]. These authors developed a Research Diagnostic Criteria for Temporomandibular Disorders (RDC/TMD) to standardize and, therefore, ensure more reliability to TMD studies. In 2011, the prospective study “Orofacial Pain: Prospective Evaluation and Risk Assessment” (OPPERA) for evaluating risk factors in TMD identified some findings showing a genetic component predisposing patients to TMD [5]. In 2014, a publication that appeared in the first edition of the “Journal of Orofacial Pain” presented the Diagnostic Criteria (DC/TMD) showing concern in assessing the main complaint during the physical exam, as well as the familiarity of the pain [6].

The treatment of TMD has been carried out in several ways, and non-invasive or minimally invasive treatments have been accepted as the first choice in bibliographic reviews and clinical practice. The most commonly found treatments in the literature are: occlusal stabilization splints of temporomandibular joints (TMJs) and the muscles of mastication, physiotherapy exercises, phototherapy, transcutaneous electrical nerve stimulation (TENS), ultrasound, dry needling, biofeedback therapy,

pharmacotherapy and psychological treatment. This is mainly due to the fact that TMD is considered a multi-factorial and self-limiting disease [7].

Treatments that are considered invasive, such as occlusal adjustment and surgical interventions have been considered last choice interventions or for specific cases which are being increasingly less used. Other invasive treatments in particular are arthrocentesis and intra-joint viscosupplementation, both showing satisfactory results for degenerative osteoarticular diseases [8].

A previous study conducted by our research group showed that phototherapy reduced pain and increased the maximal mouth opening capacity of patients with TMD [9]. Within this context, physical modalities such as laser and ultrasound may be an interesting strategy for non-invasive treatment of TMD.

The aim of this study is to present a clinical case of a patient diagnosed with TMD who was treated using an innovative device that combines simultaneous application of laser and ultrasound.

Clinical Case Presentation

The patient is ATS, a Caucasian female, 27 years old, who was selected and evaluated at the dental office of the Biophotonics Laboratory at the São Carlos Institute of Physics, University of São Paulo (IFSC - USP) for TMD treatment according to the “Research diagnostic criteria for temporomandibular disorders (RDC/TMD)” designed by Dworkin [4]. The main complaint reported by the patient was pain on the left and right preauricular regions. Additional complaints reported by the patient included: difficulties in chewing and headaches. A diagnostic hypothesis of muscle and joint TMD with secondary headache comorbidity due to TMD was suggested. The patient was treated using a new prototype comprising ultrasound and laser within a single system.

Corresponding author: Vitor Hugo Panhóca, São Carlos Institute of Physics, University of São Paulo, PO Box 369, 13560-970, São Carlos, SP, Brazil, Tel: 0123456789; E-mail: vhpahoca@ifsc.usp.br

Prototype

A prototype was developed (Figure 1) at the Technological Support Laboratory at IFSC - USP. This system includes a laser beam at the center of the ultrasound transducer so that the therapies can be carried out or applied simultaneously. The ultrasound can be operated at 1 or 3 MHz frequency and in a continuous or pulsed mode. The laser has a power output of 100 mW and red (660 nm) or infrared (808 nm) wavelength.



Figure 1. Laser and ultrasound in the same hand piece (prototype).

Treatment and measurements

To treat the TMD, an infrared laser (808 nm) was used in the continuous mode with a power output of 100 mW associated with a pulsed ultrasound (50% duty cycle) with a frequency of 1 MHz and intensity of 1 W/cm². The application time was 120 seconds per region. The prototype was used in three regions on each side of the face (left and right): (i) masseter muscle body; (ii) anterior temporal muscle fibers; (iii) TMJ (Figure 2). The treatment was carried out twice a week for one month, making a total of 8 treatment sessions. During the treatment, the applications were carried out using colorless gel as a coupling medium for the transmission of ultrasound waves and the applications were made in circular, slow and gentle movements. The patient wore safety glasses during the treatment.

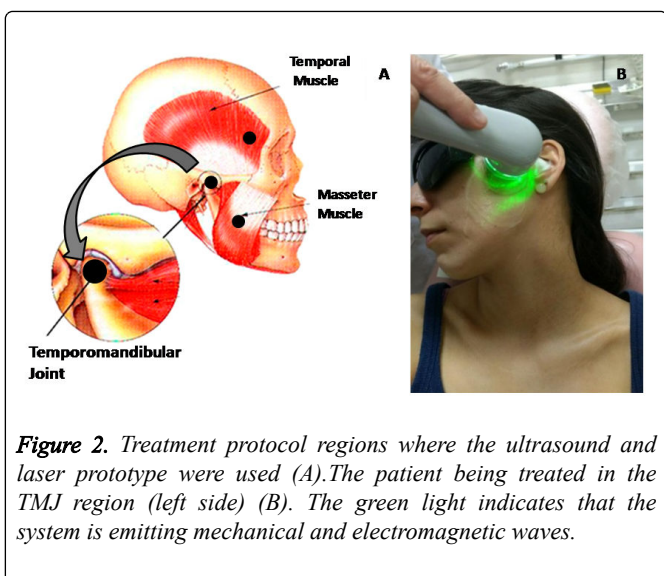


Figure 2. Treatment protocol regions where the ultrasound and laser prototype were used (A). The patient being treated in the TMJ region (left side) (B). The green light indicates that the system is emitting mechanical and electromagnetic waves.

Pain was assessed before and after the 8 treatment sessions by the visual analogue scale (VAS) performing manual palpation with a pressure of approximately 1.0 Kgf and 0.5 Kgf on the mastication muscles and the TMJ, respectively. The VAS scores were considered in the range of 0-3 (0=no pain, 1=mild pain, 2=moderate pain, 3=severe pain). This methodology was determined from the study that evaluated the careful palpation training by Dworkin&LeResche – described in “Research Diagnostic Criteria for Temporomandibular Disorders” (RDC/TMD) [4]. The patient was reevaluated after 30 days of treatment.

Additionally, an Oral Health Impact Profile (OHIP-14) questionnaire was carried out before and after the low power laser and ultrasound therapy. The questionnaire included 7 dimensions: functional limitations, physical pain, psychological discomfort, physical limitation, psychological limitation, social limitation and disability. Each domain comprised two questions. The scores attributed to each question were: never=0, rarely=1, sometimes=2, often=3 and always=4. The answers were totalized and the maximum score was 56 points. The higher the score, the lower the patient’s quality of life [10]

Thermographic images were carried out before, during, immediately after and two minutes after the laser application with ultrasound to measure the cutaneous temperature. The thermographic evaluations were carried out always at the same time of day in an acclimatized laboratory with temperatures ranging from 22°C to 24°C and relative humidity between 50% and 60%. An IR-CAM thermal imager (FLUKE Corp., Washington, USA) was used to detect far-infrared radiation. FlukeView® software (FLUKE Corp., Washington, USA) was used for image acquisition. Six different points within the region of interest (application area of prototype) were selected to calculate an average and standard deviation of the temperature.

Results

Data for VAS (pain score) and for OHIP-14 are listed in Tables 1 and 2, respectively. The cutaneous temperature is shown in Figure 3. Regarding the treatment, no thermal effect was observed. The mean and standard deviation values of temperature (°C) before, during, immediately after and five minutes after the treatment were: 28.4 ± 0.1°C, 28.9 ± 0.4°C, 29.3 ± 0.1°C and 28.9 ± 0.1°C, respectively.

Discussion

This is the first case study that shows a new system that promotes synergistic application of laser and ultrasound for TMD treatment. The results after the low power laser and ultrasound, which were assessed by VAS, showed a reduction in pain sensitivity by the patient after palpation of the masseter, temporal and TMJ muscles. In the OHIP-14 quality of life assessment, which measures the impact of TMD treatment on the patient’s quality of life, it can be observed that there was a 96% improvement in the total oral quality of life score.

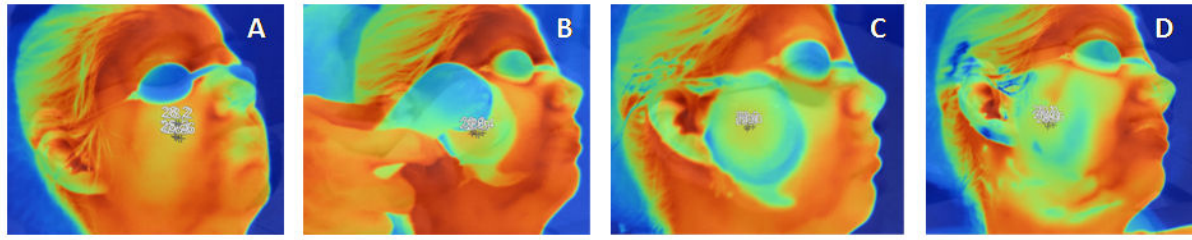


Figure 3. Thermal images before (A), during (B), immediately after (C) and five minutes (D) after treatment with ultrasound and laser.

Table 1. Assessment by the VAS (pain score) before and after the treatment of TMD of ATS, a 27 year-old patient.

Palpations / VAS	Before treatment T=0	After 8 treatment sessions T=1	30 days after the end of the treatment T=2
TMJ	2R 2L	0R 0L	1R 0L
Masseter	2R 1L	0R 0L	0R 0L
Temporal	2R 2L	0R 0L	0R 0L

VAS stands for Visual Analogue Scale (0=no pain, 1=mild pain, 2=moderate pain, 3=severe pain). R stands for right and L for left.

Table 2. Assessment by OHIP-14 before and after treatment of TMD of patient ATS.

OHIP-14 / Dimensions	Before treatment T=0	After 8 treatment sessions T=1	Percentage change after therapy (%)
Functional limitation	0	0	0
Physical pain	6	1	83
Psychological discomfort	5	0	100
Physical limitation	1	0	100
Psychological limitation	3	0	100
Social limitation	2	0	100
Disability	4	0	100
Total	21	1	96

Maximum score of OHIP-14 = 56

Using these techniques separately is well known for treating osteoarticular disorders, particularly TMD. Various studies [9-13] show that low power laser (LLLT) can be considered a useful physical modality in TMD management, relieving pain and increasing the orofacial function. Regarding ultrasound, Esposito et al. showed that this therapy can be used effectively to relieve myofascial pain [14]. In addition, Ucar et al. showed that the combination of ultrasound with home exercise was more effective compared to home exercise alone for pain relief and greater mouth opening in patients with TMD [15].

In this context it was expected that the synergistic use would be positive for pain reduction in the patient with TMD of this study. Moreover, 30 days after the end of the treatment, the pain had not returned. These therapeutic effects are related to the interaction of photoacoustic (photons + acoustic wave) effect with biological tissue.

A literature review shows that LLLT is able to act on biological tissue due to the absorption of photons by the photoreceptors present in the mitochondria, for example:

Cytochrome c peroxidase and NADH dehydrogenase, which accelerates the mitochondrial electron transport chain, promoting biochemical cascade reactions, which in turn generates an increase in the ATP synthase [16]. Furthermore, LLLT promotes cytokine modulation which produces an anti-inflammatory effect, as well as stimulating nitric oxide (NO) synthase which in turn increases peripheral vascularization and oxygen supply to these tissues [16,17]. LLLT can also be considered an analgesic treatment as it modulates nociception. Moreover, it stimulates opioids such as beta-endorphin [18]. These photobiomodulatory effects converge for muscle relaxation [19].

Infrared laser was chosen because this wave length allows greater tissue penetration so that the photons act in the osteoarticular system [20]. The pulsed ultrasound was chosen as it does not present a predominant thermal effect, as observed in thermographic images [20,21]. The non-thermal effect is important for avoiding an increase in edema, heat, redness and pain when treating an acute inflammatory

process. Therefore, the laser and ultrasound parameters used for this case study were adequate for the treatment of TMD.

While the laser emits photons, ultrasound is an acoustic waveform whereby energy is transmitted by molecular vibrations through a medium that can be solid, liquid or gaseous through which the wave passes, with absorption of mechanical energy by the tissues. Therefore, the vibrational energy is transformed into molecular energy [22]. Ultrasound applied in a continuous mode has a predominant thermal effect. However, for this study the pulsed mode was used as it has a predominant non-thermal effect and promotes stable cavitation, whereby resonant bubbles or microvibrations, remaining intact. There was a microvibration of particles which results in a constant circulation of fluids. This vibration, located around the bubbles and adjacent cell membranes and their organelles, increases membrane permeability to ions and metabolites, promoting various therapeutic effects [23,24]. Various studies concerning ultrasound show that there is an increase in cytokine vascularization and modulation, promoting an anti-inflammatory effect, as well as the modulation of the nerve conduction velocity and the increase in the nociceptive threshold result in the treatment of pain [25-27]. Ultrasound also changes muscle contractility, promoting relaxation [28].

To treat TMD of the clinical case presented here, infrared laser (808 nm) associated to ultrasound was used, with an application time of 120 seconds per region. It could be observed that there was pain reduction in the anterior temporal muscle fibers, masseter muscle and TMJs on the left and right sides. Additionally, the patient reported secondary headaches to the TMD, which at the end of the treatment and after the 30-day assessment, no longer had this symptom.

Conclusion

The current case study showed the treatment of TMD through the synergistic action of the laser and ultrasound with an analgesic effect and improvement of the patient's quality of life. Future large randomized clinical trials should be conducted to explore more potent effects of this treatment.

Acknowledgments

The authors acknowledge the financial support by Financier of Studies and Projects (FINEP) (FINEP) -grant 01.13.0430-00, São Paulo Research Foundation (FAPESP) - grant no. 2013/14001-9 and 2013/07276-1 (CEPOF – CEPID Program), and has the partnership with MMOptics.

References

1. Verhaak PF, Kerssens JJ, Dekker J, Sorbi MJ, Bensing JM. Prevalence of chronic benign pain disorder among adults: a review of the literature. *Pain*. 1998; **77**: 231-239.
2. Costen JB. A syndrome of ear and sinus symptoms dependent upon disturbed function of the temporomandibular joint. *Annals of Otolaryngology and Laryngology*. 1934; **43**: 1-15.
3. Helkimo M. Studies on function and dysfunction of the masticatory system: IV. Age and sex distribution of symptoms of dysfunction of the masticatory system in lapps in the north of Finland. *Acta Odontologica Scandinavica*. 1974; **32**: 255-267.
4. Dworkin SF, LeResche L. Research diagnostic criteria for temporomandibular disorders: review, criteria, examinations and specifications, critique. *Journal of Craniomandibular Disorders*. 1992; **6**: 301-355.
5. Smith SB, Maixner DW, Greenspan JD, Dubner R, Fillingim RB, et al. Potential genetic risk factors for chronic TMD: genetic associations from the OPPERA case control study. *Journal of Pain*. 2011; **12**: T92-101.
6. Schiffman E, Ohrbach R, Truelove E, Look J, Anderson G, et al. Diagnostic Criteria for Temporomandibular Disorders (DC/TMD) for Clinical and Research Applications: Recommendations of the International RDC/TMD Consortium Network* and Orofacial Pain Special Interest Group†. *Journal of Oral & Facial Pain and Headache*. 2014; **28**: 6-27.
7. Medlicott MS, Harris SR. A systematic review of the effectiveness of exercise, manual therapy, electrotherapy, relaxation training, and biofeedback in the management of temporomandibular disorder. *Physical Therapy*. 2006; **86**: 955-973.
8. Bonotto D, Custódio LG, Cunali PA. Viscosuplementação como tratamento das alterações internas da articulação temporomandibular: relato de casos. *Revista Dor*. 2011; **12**: 274-278.
9. Panhoca VH, de Fatima Zanirato Lizarelli R, Nunez SC, Pizzo RC de A, Grecco C, et al. Comparative clinical study of light analgesic effect on temporomandibular disorder (TMD) using red and infrared led therapy. *Lasers in Medical Science*. 2015; **30**: 815-822.
10. Robinson PG, Gibson B, Khan FA, Birnbaum W. A comparison of OHIP 14 and OIOP as interviews and questionnaires. *Community Dental Health*. 2001; **18**: 144-149.
11. De Moraes Maia ML, Ribeiro MAG, Maia LGM, Stuginski-Barbosa J, Costa YM, et al. Evaluation of low-level laser therapy effectiveness on the pain and masticatory performance of patients with myofascial pain. *Lasers in Medical Science*. 2014; **29**: 29-35.
12. Ahrari F, Madani AS, Ghafouri ZS, Tunér J. The efficacy of low-level laser therapy for the treatment of myogenous temporomandibular joint disorder. *Lasers in Medical Science*. 2014; **29**: 551-557.
13. Kulekcioglu S, Sivrioglu K, Ozcan O, Parlak M. Effectiveness of low-level laser therapy in temporomandibular disorder. *Scandinavian Journal of Rheumatology*. 2003; **32**: 114-118.
14. Esposito CJ, Veal SJ, Farman AG. Alleviation of myofascial pain with ultrasonic therapy. *Journal of Prosthetic Dentistry*. 1984; **51**: 106-108.
15. Ucar M, Sarp Ü, Koca İ, Eroğlu S, Yetisgin A, et al. Effectiveness of a home exercise program in combination with ultrasound therapy for temporomandibular joint disorders. *Journal of Physical Therapy Science*. 2014; **26**: 1847-1849.
16. Vladimirov YA, Osipov AN, Klebanov GI. Photobiological principles of therapeutic applications of laser radiation. *Biochem*. 2004; **69**: 81-90.
17. Karu TI, Pyatibrat LV, Afanasyeva NI. A novel mitochondrial signaling pathway activated by visible-to-near infrared radiation. *Photochemistry and Photobiology*. 2004; **80**: 366-372.
18. Chow RT, David MA, Armati PJ. 830 nm laser irradiation induces varicosity formation, reduces mitochondrial membrane potential and blocks fast axonal flow in small and medium diameter rat dorsal root ganglion neurons: Implications for the analgesic effects of 830 nm laser. *Journal of the Peripheral Nervous System*. 2007; **12**: 28-39.
19. Castano AP, Dai T, Yaroslavsky I, Cohen R, Apruzzese WA, et al. Low-level laser therapy for zymosan-induced arthritis in rats: Importance of illumination time. *Lasers in Surgery and Medicine*. 2007; **39**: 543-550.
20. Paolillo AR, Paolillo FR, João JP, João HA, Bagnato VS. Synergic effects of ultrasound and laser on the pain relief in women with hand osteoarthritis. *Lasers in Medical Science*. 2014; **30**: 279-286.

21. Naito K, Watari T, Muta T, Furuhashi A, Iwase H, et al. Low-intensity pulsed ultrasound (LIPUS) increases the articular cartilage type II collagen in a rat osteoarthritis model. *Journal of Orthopedic Research*. 2010; **28**: 361-369.
22. Ter Haar G. Therapeutic ultrasound. *European Journal of Ultrasound*. 1999; **9**: 3-9.
23. Dyson M. Non-thermal cellular effects of ultrasound. *British Journal of Cancer*. 1982; **5**: 165-171.
24. Robertson VJBK. A review of therapeutic ultrasound: Effectiveness studies. *Physical Therapy*. 2001; **81**: 1339-1350.
25. Reher P, Doan N, Bradnock B, Meghji S, Harris M. Effect of ultrasound on the production of IL-8, basic FGF and VEGF. *Cytokine*. 1999; **11**: 416-423.
26. Hashish I, Hai HK, Harvey W, Feinmann C, Harris M. Reduction of postoperative pain and swelling by ultrasound treatment: a placebo effect. *Pain*. 1988; **33**: 303-311.
27. Chen YW, Tzeng JI, Huang PC, Hung CH, Shao DZ, et al. Therapeutic Ultrasound Suppresses Neuropathic Pain and Upregulation of Substance P and Neurokinin-1 Receptor in Rats after Peripheral Nerve Injury. *Ultrasound in Medicine and Biology*. 2015; **41**: 143-150.
28. Falconer J, Hayes KW, Chang RW. Effect of ultrasound on mobility in osteoarthritis of the knee. A randomized clinical trial. *Arthritis Care and Research*. 1992; **5**: 29-35.