



Total Hip Arthroplasty *versus* Hip Resurfacing: Evidence Based Review and Current Indications

Jonathan RB Hutt, Martin Lavigne and Pascal-Andre Vendittoli*

Maisonneuve Rosemont Hospital, Montreal University, Canada

Abstract

Total hip arthroplasty (THA) is the gold standard in the treatment of degenerative hip disease, especially in the older patient. Concerns regarding the higher levels of failure of traditional implants in younger, more active patients have led to a search for alternative arthroplasty techniques. Hip resurfacing (HR) is one of these alternatives. When compared with THA, HR has some theoretical advantages that stem from preservation of the patient's normal proximal femoral anatomy and the use of a large diameter metal on metal bearing. This has the potential to more accurately replicate physiological hip function, reduce the risk of dislocation and allow higher levels of activity with minimal wear of the articulating surface. In addition, the preservation of proximal femoral bone stock offers the potential for easier revision options as would inevitably be required in younger patients. In order to be considered a suitable alternative, HR would need to demonstrate improvements or at least equivalence in functional outcomes and survivorship along with evidence of successful preservation of bone stock leading to good outcomes from future revision surgery. Whilst the recent expansion of data both in the orthopaedic literature and the mainstream media concerning the potentially devastating problems from large metal-on-metal (MoM) bearings in some settings carries some salient lessons for both the development, marketing and uptake of new orthopaedic implants, it should be put in the context of the resurfacing literature as a whole. In this review we aim to review the current evidence base for HR compared with THA and examine the current indications for the procedure.

Keywords: Hip; Resurfacing; Arthroplasty; Metal-on-metal; Evidence-based; Hip replacement

Introduction

Total hip arthroplasty (THA) is the gold standard in the treatment of degenerative hip disease, especially in the older patient. Concerns regarding the higher levels of failure of traditional implants in younger, more active patients [1] have led to a search for alternative arthroplasty techniques. Hip resurfacing (HR) is one of these alternatives, and has been around in a recognizable form since the 1970s [2]. When compared with THA, HR has some theoretical advantages that stem from preservation of the patient's normal proximal femoral anatomy and the use of a large diameter metal on metal bearing. This has the potential to more accurately replicate physiological hip function, reduce the risk of dislocation and allow higher levels of activity with minimal wear of the articulating surface. In addition, the preservation of proximal femoral bone stock offers the potential for easier revision options as would inevitably be required in younger patients. In order to be considered a suitable alternative, HR would need to demonstrate improvements or at least equivalence in functional outcomes and survivorship along with evidence of successful preservation of bone stock leading to good outcomes from future revision surgery. Whilst the recent expansion of data both in the orthopaedic literature and the mainstream media concerning the potentially devastating problems from large metal-on-metal (MoM) bearings in some settings carries some salient lessons for the development, marketing and uptake of new orthopaedic implants, it should be put in the context of the resurfacing literature as a whole. Whilst a systematic review would allow the formation of more definite conclusions, it is hard to evaluate more than one or two outcomes. The choice of implant is a significant factor in the outcomes of HR especially; the proliferation onto the market of inferior implants had an effect on available evidence [3,4]. The results from even high quality studies evaluating the results of recalled or discontinued implants would skew the conclusions. In this paper we therefore chose to review the broader evidence base for HR compared with THA covering multiple different aspects between the two procedures. The aim is to provide a comprehensive overview to help surgeons understand the current areas of controversy.

Methodology

The structure of this article was designed to review the relevant published evidence for HR and THA under the following sub-sections: Biomechanics, Clinical Function, Patient Reported Outcomes, Implant Survivorship, Adverse Events and Implant Revision. Articles for each section were identified using a broad range of search terms to identify comparative studies between HR and THA or descriptive studies for either technique relevant to each section heading. We included only studies published in the English language after searching the MEDLINE, PubMed, EMBASE and Scopus electronic databases. The numbers and references for each set of articles reviewed for each section are summarized in Appendix 1. Each has been graded for a level of evidence according to the system used by the JBJS (Am) since 2003 [5]

Biomechanics

From a biomechanical point of view, the minimal bone resection on the femoral side and the preservation of proximal femoral anatomy in HR has the potential to better replicate the normal hip physiology of the patient (Figure 1). Although accurate pre-operative templating may reduce inaccuracies in offset and leg length in THA, inevitably the ability to completely restore these factors will be limited by the modularity and flexibility of the implant system used. Two retrospective studies by Ahmed et al and Silva et al demonstrated that HR more accurately

***Corresponding author:** Pascal-Andre Vendittoli, Professor of surgery, Montreal University, Maisonneuve Rosemont Hospital, 5415 boulevard de l'Assomption, Montreal, Quebec H1T 2M4, Canada, Tel: 514 252-3823, Fax: 514 252-0115; E-mail: pa.vendittoli@me.com

Received July 30, 2014; **Accepted** October 31, 2014; **Published** November 04, 2014

Citation: Hutt JRB, Lavigne M, Vendittoli PA (2014) Total Hip Arthroplasty *versus* Hip Resurfacing: Evidence Based Review and Current Indications. Orthop Muscul Syst 3: 173. doi:10.4172/2161-0533.1000173

Copyright: © 2014 Hutt JRB, et al. This is an open-access article distributed under the terms of the Creative Commons Attribution License, which permits unrestricted use, distribution, and reproduction in any medium, provided the original author and source are credited.

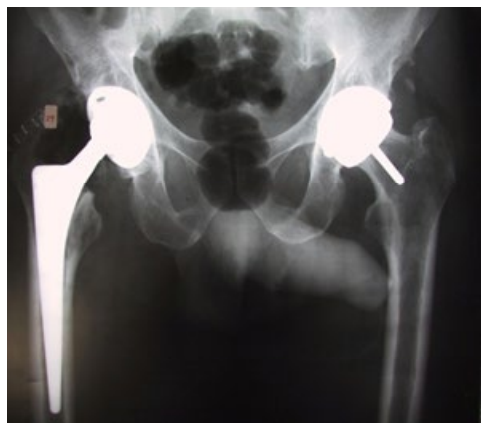


Figure 1: Right total hip arthroplasty and left hip resurfacing.

restores femoral offset and leg length compared with THA [6,7]. Girard et al. showed similar findings in a prospectively randomized study [8]. Notably however, the study by Silva et al. also suggested that if the pre-operative leg length discrepancy is greater than 1 cm, a THA may be required in order to restore this variable [7]. A single surgeon trial by Loughhead et al. showed in contrast a more accurate restoration of offset and leg length in a THA group compared with HR, although the measured differences of this study (mean offset changes of 4.5mm and length increase of 3.1mm), may not be clinically significant.

Clinical Function

A number of studies have looked at gait and postural balance after THA and HR, with conflicting results. In a retrospective study, matched for gender, Mont et al. found better gait parameters and walking speed in HR patients compared with THA [9]. In an age-matched cohort of high functioning HR and THA patients with asymptomatic controls, Shimmin et al could find no demonstrable differences, whilst Lavigne et al. looked at gait speed and postural balance between HR and large-diameter THA in a prospective, randomized, double-blind trial out to 12 months and again found no significant differences between the two groups [10]. Aqil et al. used a small cohort of 9 patients with one HR and one THA, showing that the HR side demonstrated gait parameters which more closely approached those of normal control subjects [11]. From a more subjective point of view, Collins et al. evaluated the patient's perception of their artificial joint relative to a normal native joint, and did not find any significant differences between groups of HR and THA patients [12].

Patient reported outcomes

Perhaps the most important outcome of all is whether hip function is ultimately improved for the patient. There is much debate about how this should be assessed, with many authors commenting on the potential ceiling effect of common hip function scores masking the potential benefits of one procedure over another [13-15]. A number of retrospective and non-randomized studies comparing HR and THA have produced conflicting evidence: Some demonstrate higher clinical scores [16,17] and others no difference [18-22]. Some of these latter studies did show higher activity levels for the HR group [18,19,21] but this was not universal [20,21]. The lack of randomization in all of these reports does however mean there is a significant risk of bias. Two prospective randomized studies by Garbuz et al. and Lavigne et al. showed similar clinical outcomes and UCLA scores comparing groups

of HR patients and large diameter THRs [23,24]. A recent pragmatic randomized trial by Costa et al. showed no difference in clinical function at 12 months between hip resurfacings and standard THRs [25]. Penny et al. reported on their randomized trial at 2yrs follow-up, again demonstrating no significant differences in clinical function scores, UCLA or EQ-5D scores [26]. The longest running randomized trial by Vendittoli et al. recently published follow-up of 6 to 9 years and did not find any significant differences in clinical function scores, although patients in their HR group did demonstrate significantly higher UCLA activity scores 5 years after surgery [15].

Implant survivorship

One proposed advantage of HR is the potential longevity afforded by reliable modern implant fixation and the minimal wear properties of a metal on metal bearing. Overall, registry data demonstrates poorer results when HR is used in wider populations. The UK registry has a revision rate of 12% at 9 years for all HR procedures, and the Australian registry has 11% revision at 12 years. There are a number of confounding factors here. Many different companies developed resurfacing products after initial promising results from other designs, but with varying success. The same UK registry report has a revision rate for the now recalled ASR component at 36% at 9 years and problems with this particular prosthesis are reported by multiple authors in the literature [27-29]. Revision rates for HR in the setting of these problems and their appearance in the mainstream media and in large scale legal battles may well escalate further as the threshold for revision is likely to decrease in the light of the potential concerns regarding metal debris and the consequences of abnormal high wear. This factor should be taken into account when looking at registry and other data that is not implant specific, as the inclusion of dis-continued devices may skew the interpretation. This fact is well demonstrated in a recent systematic review of outcomes, where the authors demonstrated that revisions and re-operations were more frequent for HR, unless devices which have been withdrawn from the market are excluded [30]. The only randomised study comparing HR and THA with published mid-term outcomes did not demonstrate differences in revision rates at a mean of 8 years [15]. An interesting feature of survivorship studies in which the data is analyzed in more detail is the demonstration that survivorship of HR implants within certain cohorts of patients is better than others. In a review of multiple registry data, Corten et al. showed that HR component sizes greater than 50mm in diameter had much improved survival rates, and male patients younger than 65yrs had comparable or even slightly improved survivorship with HR compared with THA [31]. The latest published data analysis from the UK National Joint Registry shows that in men with a femoral head size greater than 54mm, revision rates are comparable to the best performing THAs [32,33]. This analysis is supported by long-term data from high volume and designer centers using the best performing implants, demonstrating excellent results in selected cohorts. In young male patients, 10-year survivorship has been reported in the order of 93-99% [2,34-38]. Many of these studies confirmed that the size of the implant and the sex of the patient were significant predictors of failure during this period and this has been confirmed by further large cohort analysis [29-40] suggesting that revision rates are higher with smaller resurfacing implants and female patients.

Adverse events

The incidence of general complications of hip arthroplasty applicable to both procedures, such as venous thromboembolism, pulmonary embolism, infection, acetabular component malposition, nerve palsy or mortality does not differ between HR and THA, and due

to the nature of resurfacing, it is perhaps not surprising that dislocation rates are lower for this procedure [15,30,41]. Native femoral neck fracture is unique to HR, and is often the main cause for revision [30,32,40]. However, this particular problem may relate to errors in surgical technique, and this is one of the reasons why the learning curve for HR is highlighted as an important factor in outcomes [42,43].

One complication that has had significant attention recently is adverse reactions to metal debris (ARMD), which is of significant interest in both HR and large diameter head THA (LDH THA) with metal-on-metal bearings. The release of metal ions appears to cause a spectrum of effects, from asymptomatic raised metal ions with well-functioning implants to host responses leading to the formation of pseudotumours, sometimes accompanied by significant soft tissue and bony destruction [44]. Protocols for accurate diagnosis are still evolving. Currently, a combination of patient symptoms, metal ion levels and cross sectional imaging is used to establish the extent of any problem [44-46]. Identification is important as the consequences, most notably in the setting of tissue loss, have the potential to be catastrophic for the patient. The full causation of this problem has not yet been fully elucidated. There is undoubtedly a contribution from excessive wear in poorly engineered implants, and wear problems will be exacerbated by malposition and smaller components [47,48]. This latter issue has been cited as one reason for the higher failure rates in female patients, but there also appears to be an additional and as yet undefined patient specific contribution [49,50] which means the occurrence of this potentially very serious complication cannot be fully predicted. It is also possible that a number of different pathological processes may occur in different situations, partly explaining the wide spectrum of noted effects [51]. Despite the concerns and increasing literature on the subject, however, in a recent review of 2773 HR performed by 11 Canadian centers, only 10 potential ARMD (6 confirmed) were reported (0.36%) which reflects the low occurrence rate of the problem in a group of different HR designs performed by multiple surgeons [40]. A meta-analysis of the literature identified a pooled incidence of adverse reactions of just 0.6%, from just fewer than 14,000 MoM THA or HR operations [52]. ARMD rates do appear to be higher in LDH THA where altered forces from the large articulation acting at the modular junction at the stem trunion and head taper have been incriminated as an additional source of metal ion release [53-55]. Interestingly, and possibly as a result of the problems with metal bearings, the diagnosis of ARMD is now increasingly made in the presence of more standard THA implants without metal articulating surfaces. Again, wear and corrosion at junction of the femoral trunion and head taper, potentially as a result of manufacturing changes and more widespread use of larger diameter heads in all bearing types, has been identified as a potential causative factor [56-58].

Implant revision

Many of the younger, more active patients at whom HR technology is targeted will eventually be facing revision surgery. Whilst hip resurfacing has potential benefits for preservation of femoral bone stock, and thus use of a straightforward THA femoral component at revision, there are concerns surrounding loss of bone stock after removal of a supposedly larger acetabular component. A retrospective study by Loughhead et al. found larger acetabular sizes were used in an HR group compared with a hybrid THA group [59]. A similar study by Naal et al came to the same conclusion [60], whereas Moonot et al suggested that acetabular components in HR were either comparable to THA or even smaller in women [61]. Vendittoli et al. compared acetabular bone resection between HR and THA in a randomized

trial [62]. Using the size of the last reamer as a surrogate measure of acetabular bone loss, there were no significant differences between the two groups, although in a small proportion of cases (6.8%) the acetabular component had to be upsized by 2mm to accommodate the selected femoral component size. Similarly, Brennan et al. showed no significant differences in dehydrated, defatted acetabular bone reaming weights between HR and THA [63].

In terms of the functional outcomes of revision, there are multiple small short-term reports suggesting that the HR revision may have similar functional outcomes to primary THA (Figure 2a and 2b). Some of these series report femoral revisions only [64], others a majority of single component revision [65-67] or a majority of both component revisions [68]. In contrast, Desloges et al. reported on a retrospective propensity matched series of HR revisions, and found HR revision outcomes similar to revision THA, but not to primary THA [69]. The outcome may depend on the reason for revision [70], with poor outcomes being reported in patients having HR revised for ARMD [71]. Direct comparison with primary THA is probably not warranted due to the risk of further surgery. Data from the Australian Registry suggests that femoral component only HR revision has a similar re-revision rate to both component revision, but in both cases this is higher than the revision risk for primary THA [72]. A review of data from multiple registries had similar findings, but did point out that subsequent re-revision rates are similar to that of revision THA [31].

Again, the explosion of manufacturing development in the area of large metal bearings gives a number of confounding issues here. Until recently, it was assumed that femoral revision of HR with a well fixed and positioned acetabular component was a relatively straightforward procedure. However, emerging data from both published series [73], and the UK registry [74] suggests that large bearing MoM THR's have unacceptably high failure rates, although data from the Finnish Registry only found this to be the case in females over 55yrs old [75]. The British Orthopaedic Association now says that surgeons and hospitals 'must not use such implants [76]. Although there is little data regarding the longer term outcome of conversion of a HR to a stemmed large head MoM THA, it would be reasonable to assume that the potential consequences are no different from using such an implant in the primary setting. However, each different design of LDH THA performs differently, and the decision to convert a HR to a LDH THA should be based on the results of the specific implant to be revised [77].

Conclusions

The explosion of interest in large bearing hip arthroplasty, both as HR and LDH THA, and the subsequent manufacturing and commercial rush for involvement has led to the rather unwelcome

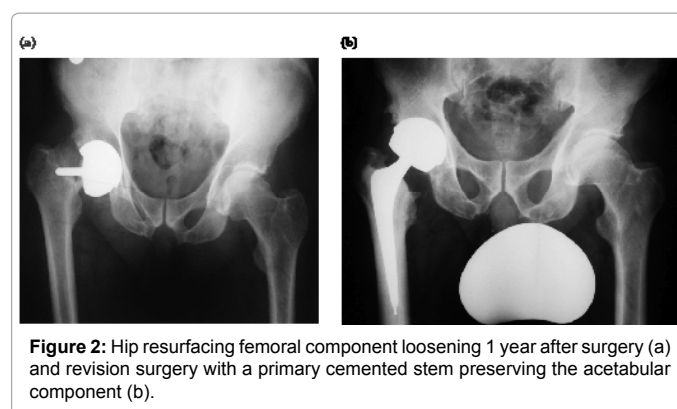


Figure 2: Hip resurfacing femoral component loosening 1 year after surgery (a) and revision surgery with a primary cemented stem preserving the acetabular component (b).

situation of the orthopaedic community discovering problems and complications in this area in large patient populations rather than controlled research cohorts. Undoubtedly, this story still has some way to play out, and there is a danger that the reports of the beneficial sides to HR technology will be lost as surgeons and implant companies aim to reclaim the trust of patients. Certainly if HR is to be used, then the current evidence base would suggest that the patient cohort in which it should be considered is shrinking. Arguably it should be limited to young, male patients of sufficient dimensions to allow a large bearing to be implanted. In addition, it ought to be performed by experienced surgeons in high volume centers. Surgeons wishing to perform the procedure should recognize the significant learning curve and seek appropriate initial training and supervision.

As the current evidence base stands however, despite the theoretical potential, numerous trials have failed to prove that HR provides significant functional benefit to patients over THA, although another way of looking at it would be to say that HR appears to perform equally well. This may well reflect ongoing developments in modularity and bearing surfaces in THA that allow accuracy of replication of hip anatomy without the bearing wear issues that initially prompted the search for an alternative in younger, more active patients. It might also be argued this is a reflection on how we measure our outcomes and whether we currently have the tools to realistically differentiate these gains clinically, but it should also be born in mind that any measurable differences should be relevant to the patient and it must be proven that there are clinically significant gains to be made before a conclusion of anything over equivalence is made. As the suitable population for HR narrows, it may be possible to perform more focused studies to further establish where such gains might be made.

Again within a young male cohort, however, it appears that one area in which hip resurfacing is performing as hoped is in its longevity. Even if functional comparisons are disregarded, this is of significant potential benefit to a young patient population. In addition, current data would appear to support the observation that revision of HR to THA in the absence of infection or ARMD is relatively straightforward and provides good outcomes. However, the recent concerns over large head MoM THA probable mean that for the foreseeable future, further replacement in the presence of a resurfacing is likely to involve a both component revision. Although this would appear to mitigate some of the proposed ease of resurfacing revision in the presence of a well fixed acetabular component, it does appear that revision of the acetabular component should not prove any more destructive than during revision of a THA, whilst femoral bone stock remains preserved, allowing the use of a standard primary THA stem.

Overall, although not all the proposed advantages of hip resurfacing appear to have been realized, the results in a selected patient population remain encouraging: However, despite the increasing numbers of higher quality trials, this particular conclusion remains largely based on level IV evidence. Further studies within more defined cohorts are required to elucidate the ideal option for young, active patients with degenerative hip disease.

References

1. Malchau H, Herberts P, Eisler T, Garellick G, Söderman P (2002) The Swedish Total Hip Replacement Register. *J Bone Joint Surg Am* 84-84A Suppl 2: 2-20.
2. Amstutz HC, Le Duff MJ (2012) Hip resurfacing: a 40-year perspective. *HSS J* 8: 275-282.
3. Ng VY, Arnott L, McShane MA (2011) Perspectives in managing an implant recall: revision of 94 Durom Metasul acetabular components. *J Bone Joint Surg Am* 93.
4. Cohen D (2011) Out of joint: the story of the ASR. *BMJ* 342: d2905.
5. Wright JG, Swiontkowski MF, Heckman JD (2003) Introducing levels of evidence to the journal. *J Bone Joint Surg Am* 85-85A: 1-3.
6. Ahmad R, Gillespie G, Annamalai S, Barakat MJ, Ahmed SM, et al. (2009) Leg length and offset following hip resurfacing and hip replacement. *Hip Int* 19: 136-140.
7. Silva M, Lee KH, Heisel C, Dela Rosa MA, Schmalzried TP (2004) The biomechanical results of total hip resurfacing arthroplasty. *J Bone Joint Surg Am* 86-86A: 40-6.
8. Girard J, Lavigne M, Vendittoli PA, Roy AG (2006) Biomechanical reconstruction of the hip: a randomised study comparing total hip resurfacing and total hip arthroplasty. *J Bone Joint Surg Br* 88: 721-726.
9. Mont MA, Seyler TM, Ragland PS, Starr R, Erhart J, et al. (2007) Gait analysis of patients with resurfacing hip arthroplasty compared with hip osteoarthritis and standard total hip arthroplasty. *J Arthroplasty* 22: 100-108.
10. Marker DR, Strimbu K, McGrath MS, Zywiol MG, Mont MA (2009) Resurfacing versus conventional total hip arthroplasty - review of comparative clinical and basic science studies. *Bull NYU Hosp Jt Dis* 67: 120-127.
11. Aqil A, Drabu R, Bergmann JH, Masjedi M, Manning V, et al. (2013) The gait of patients with one resurfacing and one replacement hip: a single blinded controlled study. *Int Orthop* 37: 795-801.
12. Collins M, Lavigne M, Girard J, Vendittoli PA (2012) Joint perception after hip or knee replacement surgery. *Orthop Traumatol Surg Res* 98: 275-280.
13. Oussedik S, Konan S, Haddad F (2012) Study lacks rigour to determine choice of hip resurfacing or arthroplasty. *BMJ* 344: e3667.
14. Wamper KE, Sierveit IN, Poolman RW, Bhandari M, Haverkamp D (2010) The Harris hip score: Do ceiling effects limit its usefulness in orthopedics? *Acta Orthop* 81: 703-707.
15. Vendittoli PA, Rivière C, Roy AG, Barry J, Lusignan D, et al. (2013) Metal-on-metal hip resurfacing compared with 28-mm diameter metal-on-metal total hip replacement A randomised study with six to nine years' follow-up. *Bone Jt J*: 95-B:1464-73
16. Vail TP, Mina CA, Yergler JD, Pietrobon R (2006) Metal-on-metal hip resurfacing compares favorably with THA at 2 years followup. *Clin Orthop Relat Res* 453: 123-131.
17. Fowble VA, dela Rosa MA, Schmalzried TP (2009) A comparison of total hip resurfacing and total hip arthroplasty - patients and outcomes. *Bull NYU Hosp Jt Dis* 67: 108-112.
18. Mont MA, Marker DR, Smith JM, Ulrich SD, McGrath MS (2009) Resurfacing is comparable to total hip arthroplasty at short-term follow-up. *Clin Orthop Relat Res* 467: 66-71.
19. Zywiol MG, Marker DR, McGrath MS, Delanois RE, Mont MA (2009) Resurfacing matched to standard total hip arthroplasty by preoperative activity levels - a comparison of postoperative outcomes. *Bull NYU Hosp Jt Dis* 67: 116-119.
20. Stulberg BN, Fitts SM, Bowen AR, Zadilka JD (2010) Early return to function after hip resurfacing: is it better than contemporary total hip arthroplasty? *J Arthroplasty* 25: 748-753.
21. Pollard TC, Baker RP, Eastaugh-Waring SJ, Bannister GC (2006) Treatment of the young active patient with osteoarthritis of the hip. A five- to seven-year comparison of hybrid total hip arthroplasty and metal-on-metal resurfacing. *J Bone Joint Surg Br* 88: 592-600.
22. Le Duff MJ, Wisk LE, Amstutz HC (2009) Range of motion after stemmed total hip arthroplasty and hip resurfacing - a clinical study. *Bull NYU Hosp Jt Dis* 67: 177-181.
23. Garbuz DS, Tanzer M, Greidanus NV, Masri BA, Duncan CP (2010) The John Charnley Award: Metal-on-metal hip resurfacing versus large-diameter head metal-on-metal total hip arthroplasty: a randomized clinical trial. *Clin Orthop Relat Res* 468: 318-325.
24. Lavigne M, Therrien M, Nantel J, Roy A, Prince F, et al. (2010) The John Charnley Award: The functional outcome of hip resurfacing and large-head THA is the same: a randomized, double-blind study. *Clin Orthop Relat Res* 468: 326-336.
25. Costa ML, Achten J, Parsons NR, Edlin RP, Foguet P, et al. (2012) Prakash U, Griffin DR, Young Adult Hip Arthroplasty Team. Total hip arthroplasty versus

- resurfacing arthroplasty in the treatment of patients with arthritis of the hip joint: single centre, parallel group, assessor blinded, randomised controlled trial. *BMJ* 344 :e2147.
26. Penny J, Ovesen O, Varmarken JE, Overgaard S (2013) Similar range of motion and function after resurfacing large-head or standard total hip arthroplasty. *Acta Orthop* 84: 246-253.
27. Hug KT, Watters TS, Vail TP, Bolognesi MP (2013) The withdrawn ASRTM THA and hip resurfacing systems: how have our patients fared over 1 to 6 years? *Clin Orthop* 471: 430-438.
28. Shemesh S, Kosashvili Y, Heller S, Sidon E, Yaari L, et al. (2013) Hip arthroplasty with the articular surface replacement (ASR) system: survivorship analysis and functional outcomes. *Eur J Orthop Surg Traumatol Orthop Traumatol*.
29. Whitwell GS, Shine A, Young SK (2012) The articular surface replacement implant recall: a United Kingdom district hospital experience. *Hip Int* 22: 362-370.
30. Marshall DA, Pykerman K, Werle J, Lorenzetti D, Wasylak T, et al. (2014) Hip resurfacing versus total hip arthroplasty: a systematic review comparing standardized outcomes. *Clin Orthop Relat Res* 472: 2217-2230.
31. Corten K, MacDonald SJ (2010) Hip resurfacing data from national joint registries: what do they tell us? What do they not tell us? *Clin Orthop Relat Res* 468: 351-357.
32. Smith AJ, Dieppe P, Howard PW, Blom AW; National Joint Registry for England and Wales (2012) Failure rates of metal-on-metal hip resurfacings: analysis of data from the National Joint Registry for England and Wales. *Lancet* 380: 1759-1766.
33. Annual reports
34. Treacy RB, McBryde CW, Shears E, Pynsent PB (2011) Birmingham hip resurfacing: a minimum follow-up of ten years. *J Bone Joint Surg Br* 93: 27-33.
35. Holland JP, Langton DJ, Hashmi M (2012) Ten-year clinical, radiological and metal ion analysis of the Birmingham Hip Resurfacing: from a single, non-designer surgeon. *J Bone Joint Surg Br* 94: 471-476.
36. Coulter G, Young DA, Dalziel RE, Shimmin AJ (2012) Birmingham hip resurfacing at a mean of ten years: results from an independent centre. *J Bone Joint Surg Br* 94: 315-321.
37. Murray DW, Grammatopoulos G, Pandit H, Gundle R, Gill HS, et al. (2012) The ten-year survival of the Birmingham hip resurfacing: an independent series. *J Bone Joint Surg Br* 94: 1180-1186.
38. Hartmann A, Lütznier J, Kirschner S, Witzleb WC, Günther KP (2012) Do survival rate and serum ion concentrations 10 years after metal-on-metal hip resurfacing provide evidence for continued use? *Clin Orthop Relat Res* 470: 3118-3126.
39. Jameson SS, Baker PN, Mason J, Porter ML, Deehan DJ, et al. (2012) Independent predictors of revision following metal-on-metal hip resurfacing: a retrospective cohort study using National Joint Registry data. *J Bone Joint Surg Br* 94: 746-54
40. Canadian Arthroplasty Society (2013) The Canadian Arthroplasty Society's experience with hip resurfacing arthroplasty. An analysis of 2773 hips. *Bone Joint J* 95-95B: 1045-51.
41. Smith TO, Nichols R, Donell ST, Hing CB (2010) The clinical and radiological outcomes of hip resurfacing versus total hip arthroplasty: a meta-analysis and systematic review. *Acta Orthop* 81: 684-695.
42. Carrothers AD, Gilbert RE, Jaiswal A, Richardson JB (2010) Birmingham hip resurfacing: the prevalence of failure. *J Bone Joint Surg Br* 92: 1344-1350.
43. Nunley RM, Zhu J, Brooks PJ, Engh CA Jr, Raterman SJ, et al. (2010) The learning curve for adopting hip resurfacing among hip specialists. *Clin Orthop Relat Res* 468: 382-391.
44. Lombardi AV Jr, Barrack RL, Berend KR, Cuckler JM, Jacobs JJ, et al. (2012) The Hip Society: algorithmic approach to diagnosis and management of metal-on-metal arthroplasty. *J Bone Joint Surg Br* 94: 14-18.
45. Macnair RD, Wynn-Jones H, Wimhurst JA, Toms A, Cahir J (2013) Metal ion levels not sufficient as a screening measure for adverse reactions in metal-on-metal hip arthroplasties. *J Arthroplasty* 28: 78-83.
46. Malek IA, King A, Sharma H, Malek S, Lyons K, et al. (2012) The sensitivity, specificity and predictive values of raised plasma metal ion levels in the diagnosis of adverse reaction to metal debris in symptomatic patients with a metal-on-metal arthroplasty of the hip. *J Bone Joint Surg Br* 94: 1045-1050.
47. Reito A, Puolakka T, Elo P, Pajamäki J, Eskelinen A (2013) High prevalence of adverse reactions to metal debris in small-headed ASR[®] hips. *Clin Orthop Relat Res* 471: 2954-2961.
48. Langton DJ, Sprowson AP, Joyce TJ, Reed M, Carluke I, et al. (2009) Partington P, Nargol AVF. Blood metal ion concentrations after hip resurfacing arthroplasty: a comparative study of articular surface replacement and Birmingham Hip Resurfacing arthroplasties. *J Bone Joint Surg Br* 91: 1287-95
49. Hart AJ, Matthies A, Henckel J, Ilo K, Skinner J, et al. (2012) Understanding why metal-on-metal hip arthroplasties fail: a comparison between patients with well-functioning and revised birmingham hip resurfacing arthroplasties. AAOS exhibit selection. *J Bone Joint Surg Am* 94: e22.
50. Ebramzadeh E, Campbell P, Tan TL, Nelson SD, Sangiorgio SN (2014) Can Wear Explain the Histological Variation Around Metal-on-metal Total Hips? *Clin Orthop Relat Res* .
51. Berstock JR, Baker RP, Bannister GC, Case CP (2014) Histology of failed metal-on-metal hip arthroplasty; three distinct sub-types. *Hip Int* 24: 243-248.
52. Wiley KF, Ding K, Stoner JA, Teague DC, Yousuf KM (2013) Incidence of pseudotumor and acute lymphocytic vasculitis associated lesion (ALVAL) reactions in metal-on-metal hip articulations: a meta-analysis. *J Arthroplasty* 28: 1238-1245.
53. Vendittoli PA, Amzica T, Roy AG, Lusignan D, Girard J, et al. (2011) Metal Ion release with large-diameter metal-on-metal hip arthroplasty. *J Arthroplasty* 26: 282-288.
54. Elkins JM, Callaghan JJ, Brown TD (2014) Stability and trunnion wear potential in large-diameter metal-on-metal total hips: a finite element analysis. *Clin Orthop Relat Res* 472: 529-542.
55. Nassif NA, Nawabi DH, Stoner K, Elpers M, Wright T, et al. (2014) Taper design affects failure of large-head metal-on-metal total hip replacements. *Clin Orthop Relat Res* 472: 564-571.
56. Porter DA, Urban RM, Jacobs JJ, Gilbert JL, Rodriguez JA, et al. (2014) Modern Trunnions Are More Flexible: A Mechanical Analysis of THA Taper Designs. *Clin Orthop Relat Res* .
57. Cooper HJ, Della Valle CJ, Berger RA, Tetreault M, Paprosky WG, et al. (2012) Corrosion at the head-neck taper as a cause for adverse local tissue reactions after total hip arthroplasty. *J Bone Joint Surg Am* 94: 1655-1661.
58. Wassef AJ, Schmalzried TP (2013) Femoral taperosis: an accident waiting to happen? *Bone Joint J* 95-95B: 3-6.
59. Loughhead JM, Starks I, Chesney D, Matthews JN, McCaskie AW, et al. (2006) Removal of acetabular bone in resurfacing arthroplasty of the hip: a comparison with hybrid total hip arthroplasty. *J Bone Joint Surg Br* 88: 31-34.
60. Naal FD, Kain MS, Hersche O, Munzinger U, Leunig M (2009) Does hip resurfacing require larger acetabular cups than conventional THA? *Clin Orthop Relat Res* 467: 923-928.
61. Moonot P, Singh PJ, Cronin MD, Kalairajah YE, Kavanagh TG, et al. (2008) Birmingham hip resurfacing: is acetabular bone conserved? *J Bone Joint Surg Br* 90: 319-323.
62. Vendittoli PA, Lavigne M, Girard J, Roy AG (2006) A randomised study comparing resection of acetabular bone at resurfacing and total hip replacement. *J Bone Joint Surg Br* 88: 997-1002.
63. Brennan SA, Harty JA, Gormley C, O'Rourke SK (2009) Comparison of acetabular reamings during hip resurfacing versus uncemented total hip arthroplasty. *J Orthop Surg (Hong Kong)* 17: 42-46.
64. Garrett SJ, Bolland BJ, Yates PJ, Gardner EM, Latham JM (2011) Femoral revision in hip resurfacing compared with large-bearing metal-on-metal hip arthroplasty. *J Arthroplasty* 26: 1214-1218.
65. Ball ST, Le Duff MJ, Amstutz HC (2007) Early results of conversion of a failed femoral component in hip resurfacing arthroplasty. *J Bone Joint Surg Am* 89: 735-741.
66. McGrath MS, Marker DR, Seyler TM, Ulrich SD, Mont MA (2009) Surface replacement is comparable to primary total hip arthroplasty. *Clin Orthop Relat Res* 467: 94-100.

-
67. Eswaramoorthy VK, Biant LC, Field RE (2009) Clinical and radiological outcome of stemmed hip replacement after revision from metal-on-metal resurfacing. *J Bone Joint Surg Br* 91: 1454-1458.
68. Sandiford NA, Muirhead-Allwood SK, Skinner JA (2010) Revision of failed hip resurfacing to total hip arthroplasty rapidly relieves pain and improves function in the early post operative period. *J Orthop Surg Res* 5: 88.
69. Desloges W, Catelas I, Nishiwaki T, Kim PR, Beaulé PE (2012) Do revised hip resurfacing arthroplasties lead to outcomes comparable to those of primary and revised total hip arthroplasties? *Clin Orthop Relat Res* 470: 3134-3141.
70. Su EP, Su SL (2013) Surface replacement conversion: results depend upon reason for revision. *Bone Joint J* 95-95B: 88-91.
71. Grammatopolous G, Pandit H, Kwon YM, Gundle R, McLardy-Smith P, et al. (2009) Hip resurfacings revised for inflammatory pseudotumour have a poor outcome. *J Bone Joint Surg Br* 91: 1019-1024.
72. de Steiger RN, Miller LN, Prosser GH, Graves SE, Davidson DC, et al. (2010) Poor outcome of revised resurfacing hip arthroplasty. *Acta Orthop* 81: 72-76.
73. Hosny HA, Srinivasan SC, Keenan J, Fekry H (2013) Midterm results with Birmingham Hip Resurfacing/Synergy stem modular metal-on-metal total hip arthroplasty. *Acta Orthop Belg* 79: 386-391.
74. Smith AJ, Dieppe P, Vernon K, Porter M, Blom AW, (2012) National Joint Registry of England and Wales. Failure rates of stemmed metal-on-metal hip replacements: analysis of data from the National Joint Registry of England and Wales. *Lancet* 379: 1199-1204
75. Mokka J, Mäkelä KT, Virolainen P, Remes V, Pulkkinen P, et al. (2013) Cementless total hip arthroplasty with large diameter metal-on-metal heads: short-term survivorship of 8059 hips from the Finnish Arthroplasty Register. *Scand J Surg* 102: 117-123.
76. Metal on Metal Hips
77. Lavigne M, Belzile EL, Roy A, Morin F, Amzica T, et al. (2011) Comparison of whole-blood metal ion levels in four types of metal-on-metal large-diameter femoral head total hip arthroplasty: the potential influence of the adapter sleeve. *J Bone Joint Surg Am* 93 Suppl 2: 128-136.