

The Protective Effects of Erdosteine and N-acetyl Cysteine in Rats With Paracetamol Induced Hippocampal Tissue Damage

Anzel Bahadir^{1*}, Süber Dikici², Hayati Kandis³, Havva Erdem⁴ and Ismail Hamdi Kara⁵

¹Department of Biophysics, Duzce University, Medical School, Duzce, 81620, Turkey

²Department of Neurology, Duzce University, Medical School, Duzce, 81620, Turkey

³Department of Emergency Medicine, Duzce University, Medical School, Duzce, 81620, Turkey

⁴Department of Pathology, Duzce University, Medical School, Duzce, 81620, Turkey

⁵Department of Family Medicine, Duzce University, Medical School, Duzce, 81620, Turkey

Abstract

This study was designed to examine the protective effects of N-acetyl cysteine (NAC) and erdosteine (ERD) on hippocampal tissue damage associated with paracetamol (acetaminophen) intoxication. Thirty female Wistar Albino rats were divided randomly into six equal groups: control; paracetamol (1 g/kg); paracetamol (1 g/kg) + ERD (150 mg/kg/day); paracetamol (1 g/kg) + NAC (140 mg/kg bolus, followed by 70 mg/kg); NAC control (140 mg/kg bolus, followed by 70 mg/kg) and ERD control (150 mg/kg/day), given orally in this study. In all the experimental groups, the protective effects of NAC and ERD were investigated by analysis of histopathology measurement on hippocampal tissues. Histopathological examination was described by neuronal degeneration, edema, and vascular congestion. Neuronal degeneration ($p < 0.01$), edema ($p < 0.00$) and vascular congestion ($p = 0.006$) were increased by significant in paracetamol experiment group, when compared with EDR and NAC treatment groups. The use of ERD and NAC was significantly decreased the severity of histopathological changes, such as neuronal degeneration, edema and vascular congestion, after experimentally paracetamol-induced intoxicity in rat hippocampal tissues. Also, the results of this study have been indicated that NAC is more protective against paracetamol intoxicity than ERD in the tissues.

Keywords: Paracetamol; Erdosteine; N-acetyl cysteine; Hippocampal tissue; Rat

Introduction

Paracetamol (acetaminophen, N-acetyl-p-amino-phenol, APAP) acts in the central nervous system (CNS) and whatever the dose and the time point considered, its concentrations were very close in the various brain and spinal areas. Furthermore, APAP is able to cross the blood-brain barrier with a homogenous distribution in all brain areas [1]. APAP have a central antinociceptive effect that is accompanied by an increase in brain serotonin content in cortical membranes [2,3].

N-Acetyl cysteine (NAC), which is used as a mucolytic agent, is a thiol compound and a membrane-permeable precursor of glutathione, which interacts directly with intracellular oxidants. Also, NAC has the capacity to inhibit several inflammatory elements related to oxidant stress and is involved in the pathophysiology of inflammation [4,5].

Like NAC, erdosteine (N-carboxymethylthioacetyl-homocysteine thiolactone, ERD), which is a thiol derivate, has been developed as mucolytic drug. In previous studies, ERD has been proved as a protective substance against diverse toxic agents such as acetaldehyde, adriamycin, bromobenzene, cisplatin, cyclophosphamide, doxorubicin, halothane, isophosphamide, isoniazid, paracetamol and penicillic acid in several animal and human reports [6-11]. Because ERD metabolites include two blocked sulphhydryl groups (SH), become available for free radical scavenging and antioxidant activity [12,13]. Additionally, several studies have been comparatively showed that protective and therapeutic effects of both ERD and NAC have been caused by paracetamol experimentally induced intoxication in different tissue damages [14,15].

To the best of our knowledge, the possible therapeutic and protective effects of ERD and NAC after paracetamol intoxication in brain tissues have not yet been investigated. For this reason, in this study were investigated the damage of rat hippocampal tissues after

paracetamol intoxication and a therapeutic effects of two antioxidant agents (NAC and ERD) on the tissues.

Materials and Methods

Animals

Thirty female Wistar Albino rats, aged 6-7 weeks and weighing 200-230 g, were used and they were given a standard laboratory diet and water *ad libitum*. The rats individually housed in metabolic cages at a temperature of $22 \pm 2^\circ\text{C}$, relative humidity of 50-60% and a 12-h light-dark cycle. Body temperature was maintained around $37 \pm 0.5^\circ\text{C}$ throughout the surgical procedure. The rats were cared for under a protocol approved by Local Ethics Committee and according to the Guide for the Care and Use of Laboratory Animals.

Treatment schedule

In the current study, we applied the methods of the previously published research of the Kandis et al. [14]. The rats were divided into the following six equal groups, composed of five rats each,

Group 1, control group: physiological saline (0.5 mL/rat) given

*Corresponding author: Anzel Bahadir (PhD), Department of Biophysics, Duzce University, Medical School, Duzce, 81620, Turkey, Tel: +90 505 758 26 61; Fax: 90 380 542 13 02; Phone: +90 380 542 14 16- 4148; E-mail: anzelbahadir@duzce.edu.tr (or) anzel78@hotmail.com

Received July 18, 2014; Accepted September 28, 2014; Published September 30, 2014

Citation: Bahadir A, Dikici S, Kandis H, Erdem H, Kara IH (2014) The Protective Effects of Erdosteine and N-acetyl Cysteine in Rats With Paracetamol Induced Hippocampal Tissue Damage. J Phys Chem Biophys 4: 15. doi:10.4172/2161-0398.1000158

Copyright: © 2014 Bahadir A et al. This is an open-access article distributed under the terms of the Creative Commons Attribution License, which permits unrestricted use, distribution, and reproduction in any medium, provided the original author and source are credited.

orally;

Group 2, paracetamol group: paracetamol (1 g/kg) given orally;

Group 3, erdosteine treatment group: ERD (150 mg/kg as initial dose) given orally, 2h after oral paracetamol (1 g/kg), followed by ERD (150 mg/kg as single daily dose) for 3 days;

Group 4, NAC treatment group: NAC (140 mg/kg as initial dose) given orally, 2h after oral paracetamol (1 g/kg), followed by NAC (70 mg/kg as a maintenance dose) given 17 times by 4h interval;

Group 5, NAC control group: NAC (140 mg/kg as initial dose) given orally, followed by NAC (70 mg/kg as a maintenance dose) given 17 times by 4h interval;

Group 6, erdosteine control group: ERD (150mg/kg) given orally for 3 days.

Paracetamol (Sigma- Aldrich Co. St. Louis, MO), NAC (Bilim Drug Industries, Turkey), and ERD (Ilsan-Iltas, Turkey) solutions were dissolved in distilled water and given orally via nasogastric tube. All animals were anesthetized by intramuscular (i.m) injection of ketamine hydrochloride (50 mg/kg, Ketalar; Eczacibasi-Farma, Turkey) and xylazine hydrochloride (Bayer AG- Leverkusen, Germany) after three days of treatment. Supplemental doses of drugs and chemicals were used as needed during surgical step. Brain tissue samples were obtained from all rats. Then the rats were killed by intraperitoneal (i.p) injection of a lethal dose ketamine hydrochloride.

Histopathological analysis

Hippocampal tissues were rapidly dissected, and the tissue samples were fixed in Zenker solution for 24 h, processed by using a graded ethanol series, and embedded in paraffin for histopathological investigation. Fixed sections (5 μ m thick slices) were cut and stained with hematoxylin and eosin (HE) for light microscopic examination. The sections were examined and photographed with an Olympus light microscope (Olympus BX51, Tokyo, Japan) with an attached photograph machine (Olympus E-330, Olympus Optical Co. Ltd., Japan) by an experienced pathologist. All sections were assessed the degree of neuronal degeneration, edema and vascular congestion in hippocampus. For each hippocampal slide, the severity of the changes were scored by using a scale of none (-), mild (+), moderate (++) and severe (+++) damage (Table 1).

Statistical analysis

All values were determinate by Statistical Package for the Social Science (SPSS) Version 11.5 (Inc., Chicago, IL, USA) software. Differences between means of the six groups were calculated by a one-way analysis of variance (ANOVA) test, followed by Bonferroni correction test for *post-hoc* multiple comparisons. A p value of < 0.05 was indicated as statistically significant.

Results

Histopathological analysis

Histopathological finding of hippocampal tissue samples were significantly different when compared with control (groups 1, 5 and 6) and the experimental (group 2) groups. These differences have been presented by Table 1 and Figure 1A and 1B). Also, Figure 2 represents histological photomicrographs of hippocampal tissues obtained from the all groups. Light microscopic examination has been revealed by normal neuronal structure in the control group (group 1) (Figure 1B).

When histopathological sections were evaluated by light microscopic examination, neuronal degeneration were found significantly ($p < 0.01$) higher in the paracetamol group (group 2) than NAC treatment (group 4), NAC control (group 5) and ERD control groups (group 6) (Figure 1A and 1B)). There was no edema in ERD control group (group 6), but there was significantly difference ($p < 0.001$) by mild and moderate edema degrees in paracetamol group (group 2) when compared with other groups (Figures 1 and 2). Also, vascular congestion were significantly ($p = 0.006$) more extensive occurred in the paracetamol group (group 2) than NAC control (group 5) and ERD control groups (group 6). However, although the significant differences ($p > 0.05$) in degeneration and edema effects were no detected between ERD treatment (group 3) and NAC treatment groups (group 4), the vascular congestion effect was found to be increased ERD treatment group (group 3) when compared with NAC treatment group (group 4) (Figures 1 and 2, Table 1).

Consequently, treatments with ERD and NAC have been significantly reduced the effects of degeneration and edema, and vascular congestion in brain hippocampal tissues after the paracetamol induced intoxication. Also, the present study indicates that NAC is more protective against paracetamol toxicity than ERD (Table 1).

Discussion

Acute paracetamol intoxication cases occur frequently in human. When organ distributions of paracetamol concentration were researched, the concentration is the lowest in brain and while its concentration is the highest in liver. However, paracetamol concentration has not been significant statistical difference from kidney and brain in several rat studies [16,17]. Additionally, Sandrini et al. [2] have been reported that a full dose of paracetamol was active in frontal cortex, where in particular its antinociceptive activity, rather than the temporal-parietal cortex of rat brain. Although Hendrickson and Bizovi [18] indicated that paracetamol affected the central nervous system (CNS) by consuming glutathione, but they could not explained how the CNS is affected by acute paracetamol poisoning in their pre-study. Also, Blecharz Klin et al. [19] have been showed that therapeutic doses of paracetamol cause significant changes in neurotransmission with subtle changes concerning behavior and particularly spatial learning in rat brain structures.

Although previous studies have been reported that paracetamol can cause damages such as hepatic necrosis, acute tubular necrosis, acute renal failure, vascular congestion, vacuolar degeneration, sinusoidal dilatation, portal inflammation in renal and liver tissues [10,14,15], this study is the first preliminary study to demonstrate hippocampal tissue damages such as degeneration, edema and vascular congestion after overdose paracetamol administration. However, the effects of ERD and NAC have not been previously examined on the structure regulation of hippocampal tissue. Only it has been notified that NAC has been reduced the generation of lipid peroxidation products, locomotor hyperactivity and hippocampal neuron loss [20]. Also, several studies have been demonstrated that an important neuroprotective effect of ERD on neurological status of spinal cord or brain ischemia/reperfusion in some animal models [21, 22].

In the present study, we evaluated the effects of NAC and ERD on the alterations of paracetamol-induced hippocampal damage which occurs neuronal degeneration, edema and vascular congestion in experimental rat model. Firstly, the hippocampal tissues were characterized by extensive degeneration, edema and vascular congestion after paracetamol intoxication (group 2). Then, our results

Parameter	Score	GROUPS						p value ^a
		Group 1	Group 2 ^a	Group 3	Group 4	Group 5	Group 6	
		Control	Paracetamol	ERD Treatment	NAC Treatment	NAC Control	ERD Control	
		<i>n</i>	<i>n</i>	<i>n</i>	<i>n</i>	<i>n</i>	<i>n</i>	
Degeneration ^b	None	0	0	0	0	0	0	<0.01
	Mild	3	1	2	5	5	5	
	Moderate	2	4	3	0	0	0	
	Severe	0	0	0	0	0	0	
Edema ^b	None	0	0	0	4	3	5	<0.001
	Mild	5	3	5	1	2	0	
	Moderate	0	2	0	0	0	0	
	Severe	0	0	0	0	0	0	
Vascular Congestion ^c	None	0	3	0	4	3	5	=0.006
	Mild	3	2	5	0	2	0	
	Moderate	2	0	0	1	0	0	
	Severe	0	0	0	0	0	0	
Total	None	5	5	5	5	5	30	

NAC: N-acetyl cysteine; ERD: erdosteine

^aComparing of Group 2 vs. other groups; statistically significant difference in degeneration and edema, and vascular congestion effects (p<0.01)

^bComparing of Group 3 vs. Group 4; no statistically significant difference in degeneration and edema effects (p>0.05)

^cComparing of Group 3 vs. Group 4; statistically significant difference in vascular congestion effect (p<0.005)

Table 1: The results of histological examination of rat hippocampal tissues

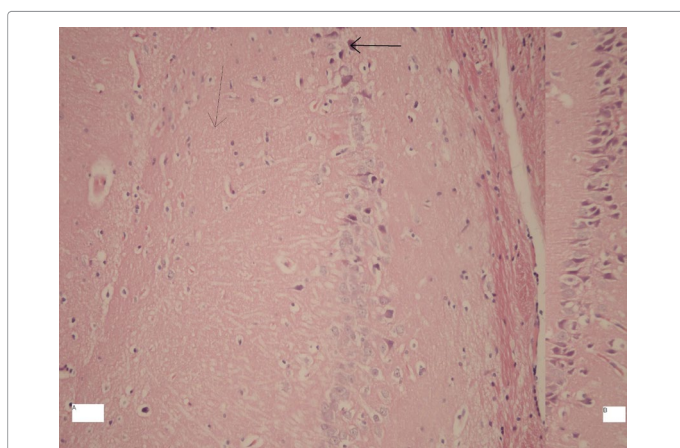


Figure 1: A-Increased neuronal degeneration, edema, and vascular congestion (H&EX 200) in experimental group, B- control group (H&EX 200)

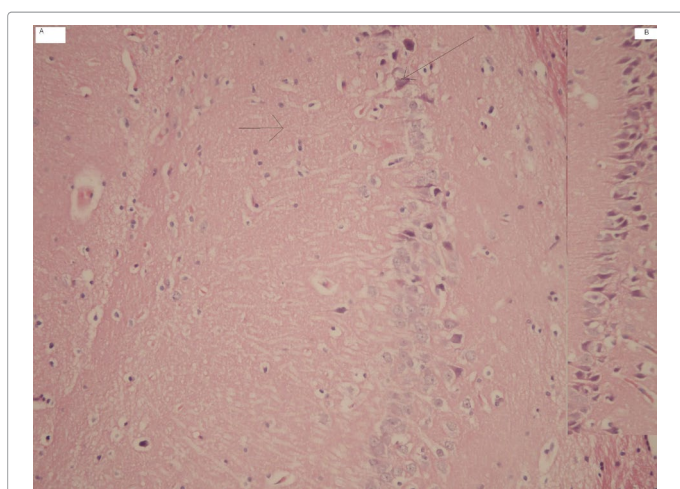


Figure 2: Decreased neuronal degeneration, edema, and vascular congestion (H&EX 200) in ERD and NAC treatment groups.

demonstrated that the use of ERD and NAC significantly decreased histopathological changes such as neuronal degeneration, edema and vascular congestion induced by paracetamol intoxication in rat hippocampal tissues (groups 3 and 4). Also, this study indicates that NAC is more protective against paracetamol toxicity than erdosteine in the tissues (group 4). According to these results, because of its antioxidant and anti-inflammatory properties, NAC may be suggested to decrease hippocampal damages after administration of overdose paracetamol.

In conclusion, we have demonstrated that a possible protective effects of ERD and NAC by semi-quantitative morphological assessment of hippocampal tissues in paracetamol induced intoxication. Our results suggest that ERD and NAC might be a new therapeutic agent for preventing paracetamol intoxication which may occur neuronal degeneration, edema, and vascular congestion in hippocampal tissues. Finally, these findings were put forward to the administration of NAC and ERD in attenuation of neuronal damage, especially hippocampal damage after paracetamol induced intoxication. Further studies are needed to elucidate the mechanisms of paracetamol induced intoxication and to investigate the direct and specific effects of these substances on hippocampal tissue regulation. However, clinical studies should be performed to investigate its possible effectiveness as an adjuvant therapeutic agent in treating human hippocampal damage.

Acknowledgment

This research received no specific grant from any funding agency in the public, commercial or not-for-profit sectors. The authors declare that there are no conflicts of interest, including specific financial interest, relationships, and/or affiliations relevant to the subject matter or materials included in this manuscript.

References

1. Courad JP, Besse D, Delchambre C, Hanoun N, Hamon M, et al. (2001) Acetaminophen distribution in the rat central nervous system. *Life Sci* 69: 1455-1464.
2. Sandrini M, Romualdi P, Vitale G, Morelli G, Capobianco A, et al. (2001) The effect of a paracetamol and morphine combination on dynorphin A levels in the rat brain. *Biochem Pharmacol* 61: 1409-1416.
3. Sandrini M, Vitale G, Ruggieri V, Pini LA (2007) Effect of acute and repeated administration of paracetamol on opioidergic and serotonergic systems in rats. *Inflamm Res* 56: 139-142.

4. Blackwell TS, Blackwell TR, Holden EP, Christman BW, Christman JW (1996) In vivo antioxidant treatment suppresses nuclear factor-kappa B activation and neutrophilic lung inflammation. *J Immunol* 157: 1630-1637.
5. Blesa S, Cortijo J, Mata M, Serrano A, Closa D, et al. (2003) Oral N-acetylcysteine attenuates the rat pulmonary inflammatory response to antigen. *Eur Respir J* 21: 394-400.
6. Fadillioglu E, Yilmaz HR, Erdogan H, Sogut S (2003) The activities of tissue xanthine oxidase and adenosine deaminase and the levels of hydroxyproline and nitric oxide in rat hearts subjected to doxorubicin: protective effect of erdosteine. *Toxicology* 191: 153-158.
7. Yagmurca M, Fadillioglu E, Erdogan H, Ucar M, Sogut S, et al. (2003) Erdosteine prevents doxorubicin-induced cardiotoxicity in rats. *Pharmacol Res* 48: 377-382.
8. Yildirim Z, Sogut S, Odaci E, Iraz M, Ozyurt H, et al. (2003) Oral erdosteine administration attenuates cisplatin-induced renal tubular damage in rats. *Pharmacol Res* 47: 149-156.
9. Cicek E, Sutcu R, Gokalp O, Yilmaz HR, Ozer MK, et al. (2005) The effects of isoniazid on hippocampal NMDA receptors: protective role of erdosteine. *Mol Cell Biochem* 277: 131-135.
10. Isik B, Bayrak R, Akcay A, Sogut S (2006) Erdosteine against acetaminophen induced renal toxicity. *Mol Cell Biochem* 287: 185-191.
11. Kalcioğlu MT, Kizilay A, Gulec M, Karatas E, Iraz M, et al. (2005) The protective effect of erdosteine against ototoxicity induced by cisplatin in rats. *Eur Arch Otorhinolaryngol* 262: 856-863.
12. Dechant KL, Noble S (1996) Erdosteine. *Drugs* 52: 875-881.
13. Braga PC, Dal Sasso M, Zuccotti T (2000) Assessment of the antioxidant activity of the SH metabolite I of erdosteine on human neutrophil oxidative bursts. *Arzneimittelforschung* 50: 739-746.
14. Kandis H, Erkan ME, Yildirim U, Gunes H, Erbas M, et al. (2011) Comparison of the effects of N-acetyl cysteine and erdosteine in rats with renal injury caused by paracetamol intoxication. *Hum Exp Toxicol* 30: 1350-1358.
15. Saritas A, Kandis H, Baltaci D, Yildirim U, Kaya H, et al. (2012) N-Acetyl cysteine and erdosteine treatment in acetaminophen-induced liver damage. *Toxicol Ind Health* 30: 670-678.
16. Hilberg T, Ripel A, Slordal L, Bjorneboe A, Morland J (1999) The extent of postmortem drug redistribution in a rat model. *J Forensic Sci* 44: 956-962.
17. Battal D, Hilal A, Daglioglu K, Unal I, Gulmen M (2013) Evaluation of paracetamol distribution and stability in case of acute intoxication in rats. *Hum Exp Toxicol* 32: 82-89.
18. Hendrickson R, Bizovi KE (2006) Acetaminophen. In: Goldfrank LR, Flomenbaum N, Howland MA et al. (Eds) *Goldfrank's Toxicology Emergencies*. New York: McGraw-Hill 523-543.
19. Blecharz-Klin K, Piechal A, Pyrzanowska J, Joniec-Maciejak I, Kiliszek P, et al. (2013) Paracetamol—the outcome on neurotransmission and spatial learning in rats. *Behav Brain Res* 253: 157-164.
20. Cuzzocrea S, Mazzon E, Costantino G, Serrano I, Dugo L, et al. (2000) Beneficial effects of n-acetylcysteine on ischaemic brain injury. *Br J Pharmacol* 130: 1219-1226.
21. Ege E, Ilhan A, Gurel A, Akyol O, Ozen S (2004) Erdosteine ameliorates neurological outcome and oxidative stress due to ischemia/reperfusion injury in rabbit spinal cord. *Eur J Vasc Endo vasc Surg* 28: 379-386.
22. Ozerol E, Bilgic S, Iraz M, Cigli A, Ilhan A, et al. (2009) The protective effect of erdosteine on short-term global brain ischemia/reperfusion injury in rats. *Prog Neuropsychopharmacol Biol Psychiatry* 33: 20-24.