

## Takotsubo Cardiomyopathy with a Tombstoning ST Segment Elevation: a Case Report

Huan Sun<sup>1</sup>, Jinsha Liu<sup>1</sup>, Mingzhou Yan<sup>1</sup>, Yanjing Wang<sup>2</sup>, Yena Oh<sup>3</sup>, Bo Yu<sup>1\*</sup>

<sup>1</sup>Department of Cardiology, China-Japan Union Hospital of Jilin University, China

<sup>2</sup>Department of Radiology, China-Japan Union Hospital of Jilin University, China

<sup>3</sup>Departments of Physiology and Medicine, University of Toronto, Canada

\*Corresponding author: Bo Yu, Department of Cardiology, China-Japan Union Hospital of Jilin University, 126 Xiantai Street, Changchun, China, Tel: +86 431 8499 5222; E-mail: [yubo6912@163.com](mailto:yubo6912@163.com)

Received date: May 11, 2016; Accepted date: June 23, 2016; Published date: June 30, 2016

Copyright: © 2016 Yu B, et al. This is an open-access article distributed under the terms of the Creative Commons Attribution License, which permits unrestricted use, distribution, and reproduction in any medium, provided the original author and source are credited.

### Abstract

A 50-year-old female with a final diagnosis of Takotsubo cardiomyopathy (TCM) was reported. Episodes of seizures, which were companied with a transient tombstoning ST elevation, were recorded during treatment. This report on TCM with tombstoning ST elevation implies to clinicians that the ECG changes of TCM are of great variability.

**Keywords:** Takotsubo cardiomyopathy; Acute coronary syndrome; Electrocardiography; Echocardiography; Tombstoning ST elevation

### Introduction

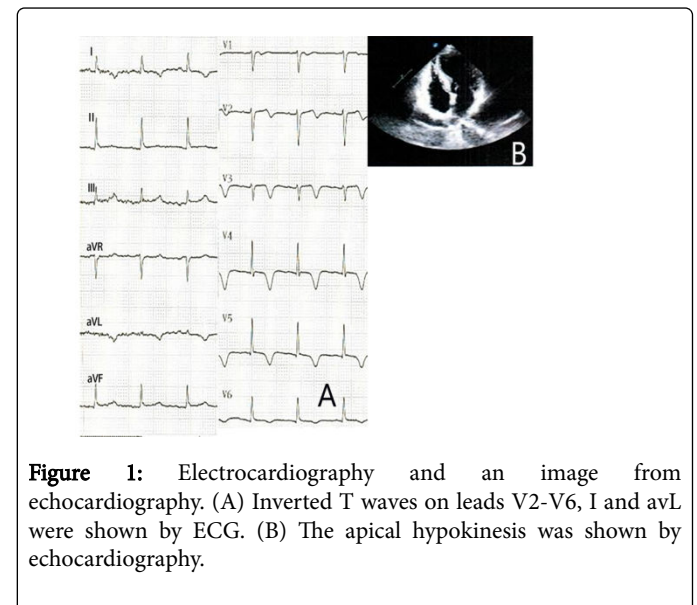
The purpose of this case report is to highlight the ECG variability of Takotsubo Myocardiopathy (TCM) [1]. This ECG change reported in our case might be confusing when first seen in medical contact.

### Case Report

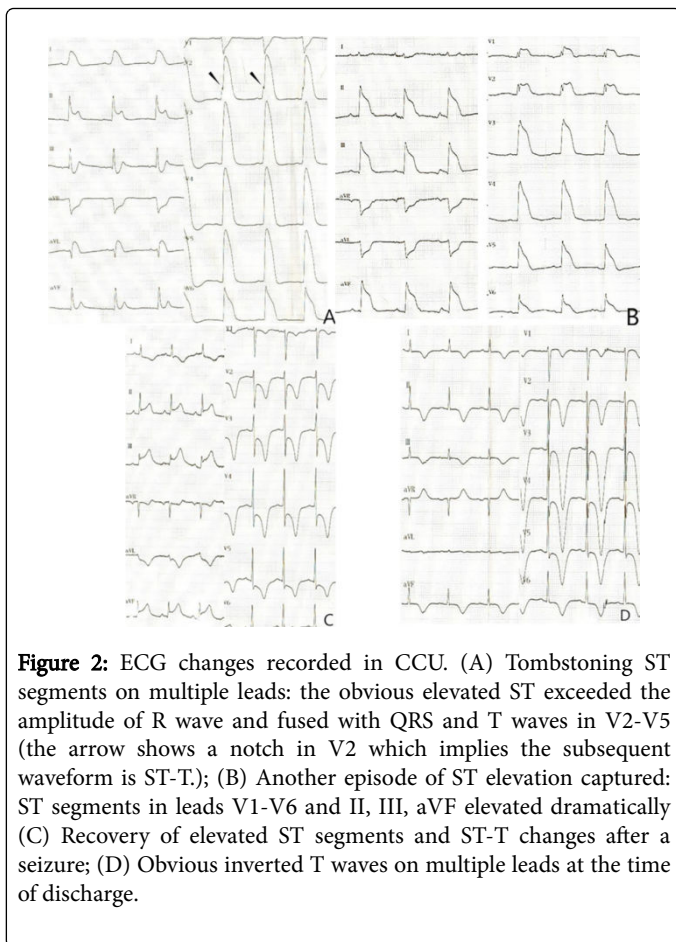
A 50-year-old female presented to emergency room with an emotion-triggered chest pain which persisted for about 2 hours on July 6, 2014. She had a hypertension history for about 2 years. The ECG in emergency room showed inverted T waves in precordial leads (Figure 1A). The echocardiography showed an apical hypokinesis (Figure 1B). The serum cTnI level elevated slightly (0.20 ng/mL, with a normal range of 0.00-0.04 ng/mL). A diagnosis of acute coronary syndrome (ACS) was made. Subsequently, anti-thrombosis therapy and anti-ischemia therapy were administrated. Although the chest pain was relieved by drug therapy quickly after hospitalization, the ECG changes did not show great improvement. Coronary angiography was performed on July 6, and significant coronary stenosis was absent.

On July 10 a sudden loss of consciousness and seizure caused by pulseless electrical activity made us transfer her into CCU. Totally three episodes of seizures happened and recovered after performances of CPR every time. We recorded a serial of transient ECG changes in CCU: Obvious ST segment elevation was observed in both limb leads and precordial leads, which was captured before and shortly after every episode. These elevated ST segments exceeded the amplitude of R waves, which was coincident with the conception of tombstoning ST segment elevation (Figure 2A and B). Such a change persisted for about ten minutes after seizures and followed by depressed ST segments and inverted T waves (Figure 2C) without any Q waves formed. A drop of dopamine was given to maintain a blood pressure level above 90/60 mmHg until stabilization was achieved. After approximate 7-hour's intensive care and supportive therapy, no

recurrent seizures occurred anymore. The patient was transferred out of CCU on July 12, and she was discharged on July 17 with multiple inverted T waves on the ECG (Figure 2D). The prescription of aspirin and beta-blocker were given after the discharge.



**Figure 1:** Electrocardiography and an image from echocardiography. (A) Inverted T waves on leads V2-V6, I and avL were shown by ECG. (B) The apical hypokinesis was shown by echocardiography.



**Figure 2:** ECG changes recorded in CCU. (A) Tombstoning ST segments on multiple leads: the obvious elevated ST exceeded the amplitude of R wave and fused with QRS and T waves in V2-V5 (the arrow shows a notch in V2 which implies the subsequent waveform is ST-T); (B) Another episode of ST elevation captured: ST segments in leads V1-V6 and II, III, aVF elevated dramatically (C) Recovery of elevated ST segments and ST-T changes after a seizure; (D) Obvious inverted T waves on multiple leads at the time of discharge.

The patient remained well during our 3-month follow-up. No hypokinesia was detected by echocardiography anymore 1 month after the discharge. Finally, the diagnosis of Takotsubo cardiomyopathy was made according to the progress of the disease and the result of the follow-up [2].

## Discussion

Takotsubo cardiomyopathy (TCM), also known as apical ballooning syndrome or stress-induced cardiomyopathy was first reported in 1991 [1]. Although several mechanisms have been proposed, the pathophysiology of this reversible cardiomyopathy has not been completely understood [2-4]. According to Myo Clinic Criteria [3], a diagnosis of Takotsubo cardiomyopathy can be made for the present case. Although the etiology of this disease has not been fully understood yet, the supportive treatment is the major managing approach during acute phase [5].

Tombstoning ST elevation has been reported in ST elevated myocardial infarction (STEMI). This pattern is considered to be associated with sudden ischemia in large areas of myocardium without any collaterals or ischemic preconditioning. This phenomenon is considered as a high-risk pattern for myocardial infarction patients [6]. A potential explanation for the seizures is that the significant and sudden abnormality reflected by the tombstoning ST elevation caused an acute drop of cardiac output, which subsequently led to a critical decrease of cerebral blood flow and episodes of seizures.

In our case, the pattern of the tombstoning ST elevation would be confusing and mimic a wide QRS complex, if not analyzed carefully enough. The following can be useful to differentiate that: 1) The QRS duration and QT interval can be acquired more easily in limb leads, especially in II, III, aVR and aVF, and we can find that the QRS duration is much shorter than duration of those wide waves, whose duration are identical to the QT interval shown in limb leads, found in precordial leads; 2) A notch-like signal can be identified shortly after the peak of QRS in lead V2 (Figure 2B), which can imply an abrupt change in ventricular electric activity. In the present case, this ECG pattern was captured before and after every episode of seizure.

Several studies have demonstrated that the ST elevation patterns are of difference between Takotsubo cardiomyopathy and STEMI. TCM can show a less obvious deviation of ST segment, and the V1 lead is less involved in the ST elevation [7-9]. However, it is pointed out that these characters are not sufficient for making diagnosis due to the low sensitivity and specificity [7]. In our report, the ECG showed an obvious ST elevation in all precordial leads, which supported such a conclusion that the ECG patterns of TCM are variable.

We have not found any previously published reports on tombstoning ST elevation in TCM. It cannot be concluded that such a ST elevation pattern is rare among TCM patients because of its short duration, as shown in our case. If the patient was not located in CCU or the episode was not recurrent, this ECG pattern would barely be easily recorded.

In conclusion, the present case enhanced the opinion that ECG changes of TCM are of variety and the diagnosis should be made according to the progress of the disease.

## References

1. Dote K, Sato H, Tateishi H, Uchida T, Ishihara M (1991) [Myocardial stunning due to simultaneous multivessel coronary spasms: a review of 5 cases]. *J Cardiol* 21: 203-214.
2. Coons JC, Barnes M, Kusick K (2009) Takotsubo cardiomyopathy. *American journal of health-system pharmacy* 66: 562-566.
3. Prasad A (2007) Apical ballooning syndrome: an important differential diagnosis of acute myocardial infarction. *Circulation* 115: e56-59.
4. Moriya M, Mori H, Suzuki N, Hazama M, Yano K (2002) Six-month follow-up of takotsubo cardiomyopathy with I-123-beta-methyl-iodophenyl pentadecanoic acid and I-123-meta-iodobenzyl-guanidine myocardial scintigraphy. *Intern Med* 41: 829-833.
5. Lyon AR, Bossone E, Schneider B, Sechtem U, Citro R, et al. (2016) Current state of knowledge on Takotsubo syndrome: a Position Statement from the Taskforce on Takotsubo Syndrome of the Heart Failure Association of the European Society of Cardiology. *Eur J Heart Fail* 18: 8-27.
6. Balci B (2009) Tombstoning ST-Elevation Myocardial Infarction. *Curr Cardiol Rev* 5: 273-278.
7. Parkkonen O, Allonen J, Vaara S, Viitasalo M, Nieminen MS, et al. (2014) Differences in ST-elevation and T-wave amplitudes do not reliably differentiate takotsubo cardiomyopathy from acute anterior myocardial infarction. *J Electrocardiol* 47: 692-699.
8. Thakar S, Chandra P, Hollander G, Lichstein E (2011) Electrocardiographic changes in Takotsubo cardiomyopathy. *Pacing Clin Electrophysiol* 34: 1278-1282.
9. Johnson NP, Chavez JF, Mosley WJ, Flaherty JD, Fox JM (2013) Performance of electrocardiographic criteria to differentiate Takotsubo cardiomyopathy from acute anterior ST elevation myocardial infarction. *Int J Cardiol* 164: 345-348.