

## Successful Excision of a 710 gram Intrathoracic Thyroid Carcinoma – A Very Rare Case

Hung-Hsing Chiang<sup>1</sup>, Hon-Man Chan<sup>1</sup>, Li-Chun Chen<sup>1</sup>, Meei-Feng Huang<sup>1</sup>, Tzu-Ju Chen<sup>2</sup>, Tsun-En Lin<sup>1</sup> and Shah-Hwa Chou<sup>1,3\*</sup>

<sup>1</sup>Department of Surgery, Kaohsiung Medical University Hospital, Kaohsiung, Taiwan, Republic of China

<sup>2</sup>Department of Pathology, Kaohsiung Medical University Hospital, Kaohsiung, Taiwan, Republic of China

<sup>3</sup>Department of Respiratory Therapy, College of Medicine, Kaohsiung Medical University, Kaohsiung, Taiwan, Republic of China

\*Corresponding author: Shah-Hwa Chou, Department of Surgery, Kaohsiung Medical University Hospital, No. 100, Tz-You 1st road, Kaohsiung, Taiwan, Republic of China, Tel: +886-7-3121101; Fax: +886-7-3127056; E-mail: [shhwch@kmu.edu.tw](mailto:shhwch@kmu.edu.tw)

Rec date: March 17, 2016; Acc date: March 31, 2016; Pub date: April 12, 2016

Copyright: © 2016 Chiang HH, et al. This is an open-access article distributed under the terms of the Creative Commons Attribution License, which permits unrestricted use, distribution, and reproduction in any medium, provided the original author and source are credited.

### Abstract

**Background:** Intrathoracic goiters that compress nearby structures require surgical excision.

**Method and result:** An abnormally large intrathoracic thyroid carcinoma (ITC) weighing 710 g was excised successfully from a 76 year-old female. For already 62 months, she is still surviving.

**Conclusion:** To the best of our knowledge, it is the largest ITC ever reported in the literature.

**Keywords:** Intrathoracic thyroid papillary carcinoma; Tumor

### Case Report

A 76 year-old female complaining of recent dyspnea, dysphagia and facial swelling came to our clinic. Her medical history revealed that she underwent left subtotal thyroidectomy thirty-five years ago at a local hospital, where the original pathology report has been lost. She suffered from no other systemic disease. Upon physical examinations, a Grade III thyroid enlargement was found in her neck. She showed no signs of hyper- or hypothyroidism. Chest roentgenogram (Figure 1) revealed a huge extrapulmonary mass occupying over two thirds of the right thoracic cavity with mediastinal shifting.

Chest computed tomographic scan (Figure 2) showed the right enlarged thyroid extending through the thoracic inlet into thoracic cavity, compressing the right lung, trachea, esophagus and superior vena cava. Laboratory examinations revealed euthyroid stage. Aspiration cytology found no malignant cells. Because of the impending compromise of the airway, urgent operation for excision was arranged. The patient was in the supine position for cervical incision first.

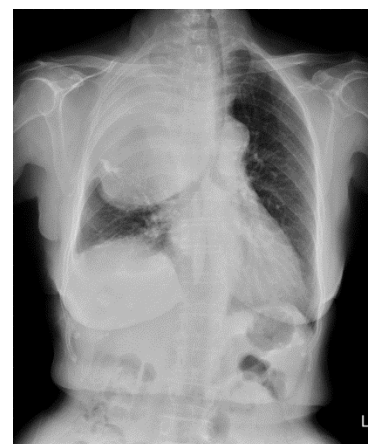
The cervical part of the thyroid was entirely dissected and separated from all surrounding tissues but not yet divided from the intrathoracic portion. The patient was then turned to the left lateral position. Right thoracotomy was performed. The tumor was found to be huge and encapsulated. The overlying pleura were of abundant engorged collaterals which caused easy oozing and bleeding during manipulation. It was gradually dissected from the mediastinal structures after ligations of several larger collaterals.

Finally the cervical portion of the mass was pulled downward and removed with the intrathoracic part as a whole. The operation took 4 hours and 30 mins with 3250 ml blood lost. Although the hemodynamic was very unstable during the procedure, patient's condition was finally stabilized at the end of the operation as a result of

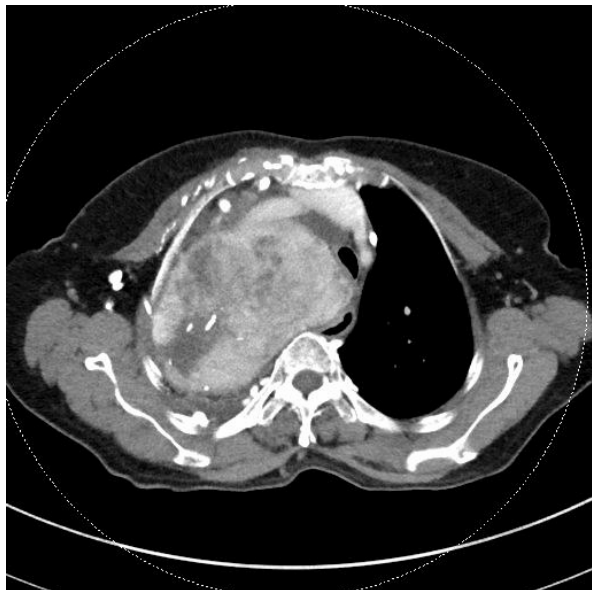
excellent teamwork with anesthesiologists. The patient was sent to the intensive care unit (ICU) for post-operative monitoring.

The endotracheal tube was removed on the same day. At the ICU, intensive chest care and bronchofiberscopic toilet (administered once) were given. The chest tube drainage amount was moderate and gradually slowing. Calcium ions were within normal range. She was transferred to the ward two days later, where we performed bronchofiberscopic pulmonary toilet twice more, and aggressive chest care. Her condition and image studies were gradually improving. She was discharged on the 12th post-operative day.

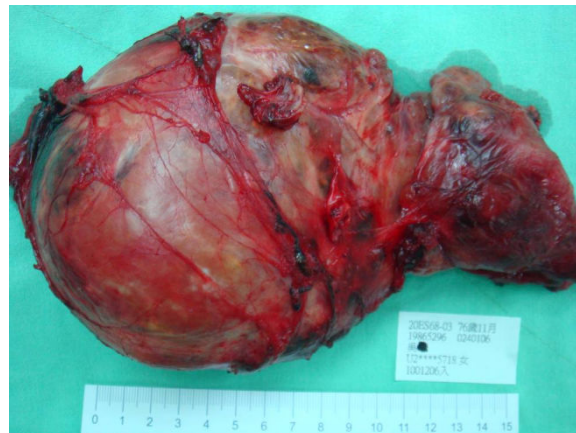
The specimen measured  $21 \times 12 \times 7 \text{ cm}^3$  and weighed 710 g (Figure 3). Pathology revealed papillary carcinoma (Figure 4).



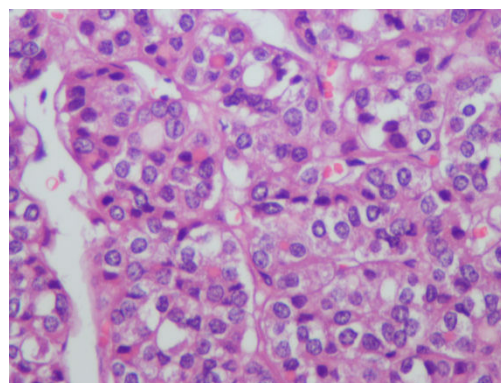
**Figure 1:** Pre-operative chest roentgenogram revealed a huge mass occupying the right hemithorax with tracheal deviation to the left.



**Figure 2:** Chest computed tomography with enhancement revealed a heterogenic mass over the right hemithorax. Note the compressed trachea and esophagus, absent SVC, engorgement of collateral vessels.



**Figure 3:** Surgical specimen. Dimensions: 21 × 12 × 7 cm<sup>3</sup>. Weight: 710 gm.



**Figure 4:** Pathology showing papillary carcinoma. (hematoxylin and eosin, 400x).

## Discussion

Our case involved a malignant intrathoracic thyroid carcinoma weighing 710 g, the largest reported in the literature. Previously, the largest reported intrathoracic thyroid tumor, a benign lesion, weighed 680 g [1].

Intrathoracic goiters that compress nearby structures, e.g. airway, or have a probability of malignancy, require surgical excision [2]. The patient in question required urgent operation to relieve her airway. In most cases, intrathoracic goiters can be excised via cervical incision [3]. But for large lesions or suspicion of adhesion with intrathoracic organs, thoracic approach including thoracotomy and sternotomy should be considered in order to avoid dangerous traction [4]. Some authors recommend thoracic incision for lesions extending below aortic arch, with posterior mediastinal involvement, duration of diagnosis beyond 160 months, or with vascular invasion [4,5]. In this case, a transthoracic procedure seemed to be the only choice because of the lesion size. Thoracotomy was chosen owing to the fact that (i) it is easier for lung resection as pulmonary invasion cannot be ruled out; (ii) invasion of mediastinal structures seemed unlikely, as determined by consulting radiologists.

Fortunately, the margins were fine with no adhesion to the surrounding organs. Surgeons were confronted with abundant engorged collaterals overlying the tumors, which caused serious bleeding during manipulation. Furthermore, due to its huge size, the operative field, especially the medial upper region, was unclear. Meticulous and careful dissection was imperative. Blood pressure once dropped to 40 mmHg systolic. In such a scenario, effective cooperation with anesthesiologists was the key to stabilizing the patient's condition, so that complete excision of the tumor can be accomplished.

Postoperative care was also crucial to the patient's recovery. Firstly, the complications of a massive transfusion had to be prevented. Hemodynamics and fluid supply were closely monitored. Secondly, the airway was frequently and carefully checked, as coagulopathy leading to neck hematoma was possible. Thirdly, calcium ions were carefully monitored. Finally, aggressive chest care with bronchofiberscopic pulmonary toilet was administered. The right upper lobe had been compressed for quite a long period of time prior to the operation, and there was profuse secretion after decompression.

This is the largest intrathoracic thyroid malignancy ever reported. This operation was successful and the patient survives happily as a result of detailed preoperative planning, fine perioperative teamwork, and aggressive, careful and attentive postoperative care.

## Acknowledgement

The authors thank Jadzia Chou for her revision of the article.

## References

1. Margaritora S, Cesario A, Porziella V, Granone P (2003) Huge mediastinal goiter. *Eur J Cardiothorac Surg* 23: 840.
2. Katlic MR, Wang CA, Grillo HC (1985) Substernal goiter. *Ann Thorac Surg* 39: 391-399.
3. Newman E, Shaha AR (1995) Substernal goiter. *J Surg Oncol* 60: 207-212.
4. Casella C, Pata G, Cappelli C, Salerni B (2010) Preoperative predictors of sternotomy need in mediastinal goiter management. *Head Neck* 32: 1131-1135.
5. Kilic D, Findikcioglu A, Ekici Y, Alemdaroglu U, Hekimoglu K, et al. (2011) When is transthoracic approach indicated in retrosternal goiters? *Ann Thorac Cardiovasc Surg* 17: 250-253.