

Small Bowel Obstruction Found in a Twin Pregnancy

Firoozeh Ahmadi^{*}, Maryam Javam and Zohreh Rashidi

Department of Reproductive Imaging, Reproductive Biomedicine Research Center, Royan Institute for Reproductive Biomedicine, ACECR, Tehran, Iran

^{*}Corresponding author: Firoozeh Ahmadi, Assistant Professor of radiology, Department of Reproductive Imaging, Reproductive Biomedicine Research Center, Royan Institute for Reproductive Biomedicine, ACECR, Tehran, Iran, Tel: +98 21 23562446; E-mail: f_ahmadi@royaninstitute.org

Rec date: Oct 15, 2015, Acc date: Oct 19, 2015, Pub date: Oct 21, 2015

Copyright: © 2015 Ahmadi F, et al. This is an open-access article distributed under the terms of the Creative Commons Attribution License, which permits unrestricted use, distribution, and reproduction in any medium, provided the original author and source are credited.

Clinical Image

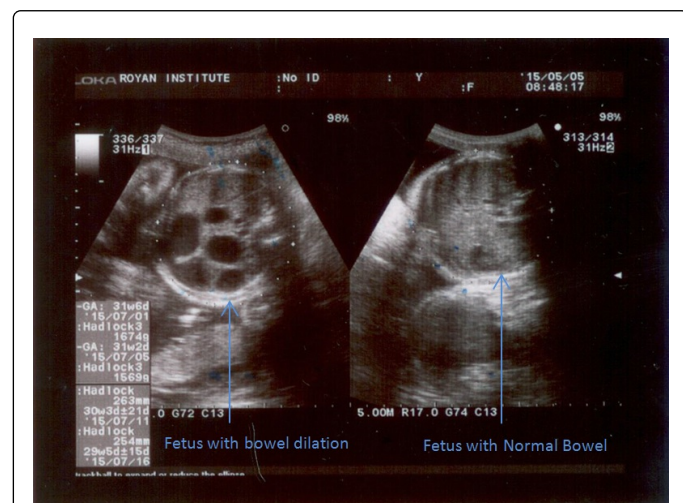


Figure 1: Dilated intestinal loops at 26th week in comparison with normal loops in other fetus.

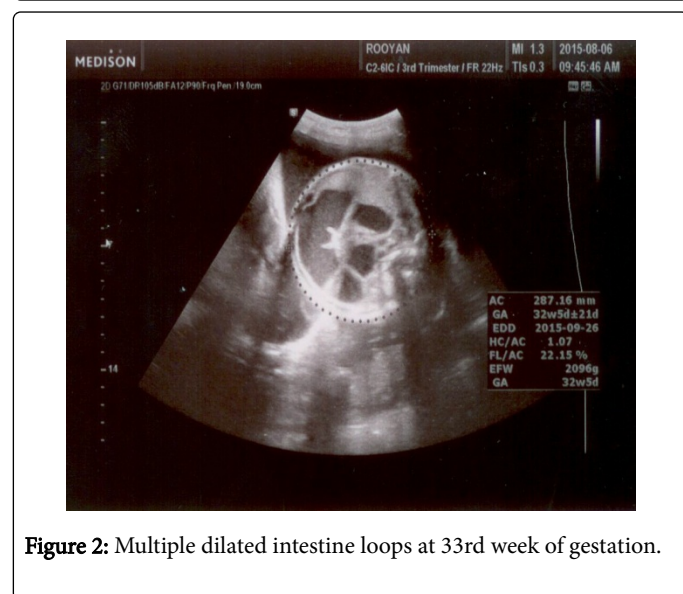


Figure 2: Multiple dilated intestine loops at 33rd week of gestation.

A 33-year old pregnant woman presented at our imaging department at Royan Institute, Tehran, Iran, to undergo ultrasound scan. She got “twin pregnancy” following Invitro-Fertilization and transferring blastocysts. Gestational age was 33weeks and 2days based on embryo transfer date. It was a dichorionic-diamniotic pregnancy.

Results of mother serum screening tests were normal in 1st and 2nd trimesters. Ultrasound screening for fetal abnormalities was also normal and no anomaly was detected in none of fetuses until 26th week of gestation. But a slightly dilated bowel loop was distinguished during sonographic evaluation of one of fetuses at 26th week, while the other fetus was normal. We assessed the patient by serial sonographies at 28th, 31st and 34th week of gestation (Figure 1).

On the last US scan at 34th week, gestational age was appraised 33-34 weeks in both fetuses based on measurement of BPD, FL and HC. According to AC diameter, fetal weigh was estimated 2200±200gr in normal fetus and 2100±200gr in fetus with bowel dilation. In transverse investigation through the fetus abdomen, multiple dilated fluid-filled loops of bowel were visualized (Figure 2). No other fetal abnormality was detected. Despite that bowel dilation and polyhydramnios are associated in some cases, the amniotic volume was normal in this fetus and deepest amniotic pocket was measured 78mm.

According to permanent progressive bowel dilation, “small bowel obstruction” was raised. The diagnosis was confirmed after birth and repair surgery was performed for her.

It worth noting that since fetal swallowing begins at 16th-17th week, bowel dilation due to atresia is recognizable only late at 2nd or 3rd trimester. Small bowel obstruction is a rare condition which occurs in just 1 out of 3000-5000 pregnancies.