

Skin Necrosis in an ICU-Patient due to Accidental Extravasation of Parenteral Nutrition Solution via a Peripheral Intravenous Catheter – A Case Report

Ozlem Ersoy*, Omer Tasargol

Department of Anesthesiology and Reanimation, Iskilip Atif Hoca Public Hospital, Iskilip, Corum, Turkey

*Corresponding author: Ozlem Ersoy, Department of Anesthesiology, Iskilip Atif Hoca Public Hospital, Iskilip, Corum, Turkey, Tel: 90-533 729 39 78; E-mail: drozlemersoy@gmail.com

Received date: January 25, 2015; Accepted date: April 08, 2015; Published date: April 13, 2015

Copyright: ©2015 Ersoy O. This is an open-access article distributed under the terms of the Creative Commons Attribution License, which permits unrestricted use, distribution, and reproduction in any medium, provided the original author and source are credited.

Abstract

Total parenteral nutrition through a peripheral venous access is a good alternative in the management of critically ill patients in the ICU who cannot be adequately fed. However, it carries an inherent risk of extravasation which results in skin and tissue necrosis. In the present report we discuss a case of accidental extravasation of peripheral parenteral nutrition solution causing serious skin necrosis. The importance of this case report lies on the high frequency of patients who need total parenteral nutrition in ICU units and that sterile dressings with Goulard's extract is a non-invasive alternative in the early period of skin lesions before needing invasive operations like debridement or/and amputation.

Introduction

Solutions that irritate the venous endothelium and vessel wall ultimately raise the risk of venous rupture when allowed to escape into the surrounding tissue [1]. For solutions that escape the vein, osmolality can also influence the degree of tissue injury. For example extravasation of hypertonic fluids such as 10% dextrose or parenteral nutrition solutions can cause skin necrosis and serious tissue damage [1,5]. Therefore these solutions should be infused through a well-functioning catheter with close observation of the catheterized extremity.

In the present case report we discuss a case of accidental extravasation of peripheral parenteral nutrition solution causing serious skin necrosis treated by elevation of the damaged extremity, topical sterile dressings, systemic glucocorticoids and antibiotherapy.

Case report

72 years old male patient who had a history of congestive heart disease and chronic peripheral venous insufficiency in both lower extremity veins, was admitted to our intensive care unit with respiratory difficulty, malnutrition and unconsciousness. Physical examination revealed tachycardia (110 bpm), low blood pressure (90/60 mmHg), tachypnea (30/min), Glasgow coma scale was 11 (Eyes: 3, Verbal:4, Motor:4) and the patient was agitated. Arterial blood gas parameters were; pH: 7,34, pO₂: 90mmHg, pCO₂: 30mmHg, HCO₃⁻: 22mEq/L, sPO₂: 91%.

While doing further investigation we decided to start parenteral nutrition instead of enteral nutrition to prevent pulmonary aspiration. Because of the expected difficulty caused by known history of chronic peripheral venous insufficiency we did not try to place a central venous catheter for only nutritional purposes. Thus parenteral nutrition solution (Kabiven Peripheral®) (pH: approx. 5,6, osmolality: approx. 830 mosm/kg water, osmolarity: approx. 750 mosmol/l) was infused with a rate of 30 ml/kg bodyweight/day through the 20 G intravenous catheter which we placed on the dorsum of the right hand. At the 4th hour of the infusion we recognized that demarcated skin

necrosis and bullous skin lesions occurred in the patient's right hand and forearm (Figures 1 and 2). After immediately discontinuing the infusion we secured an alternative venous access. In consultation with a dermatologist we started our treatment plan with sterile dressings of 2% lead sub acetate (Goulard's extract) solution 4 times a day and 20 minutes long each time, systemic glucocorticoid therapy and topical and systemic antibiotherapy. Our treatment strategy resulted in delayed complete healing which took almost 3 weeks (Figure 3).

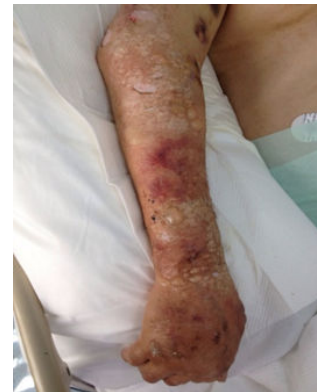

Figure 1: Demarcated skin necrosis and bullous skin lesions

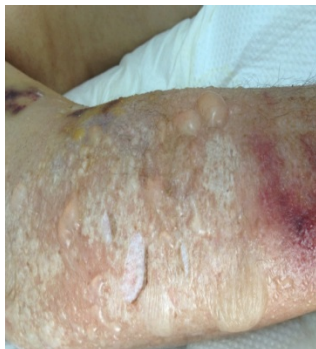

Figure 2: Demarcated skin necrosis and bullous skin lesions

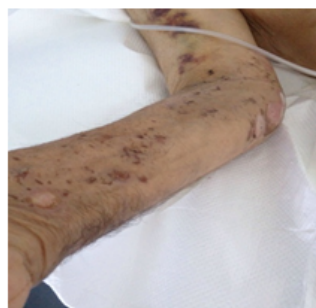


Figure 3: Complete healing of skin lesions

Discussion

Extravasation is a risk of intravenous infusion therapy. Consequences of leakage of solution into the surrounding tissue range from local irritation to amputation of an extremity. Fortunately, these adverse outcomes are preventable and identification of agents plays an

important role [6,7]. The severity of extravasation injuries is influenced by the type of the agent that extravasates, the concentration and amount of the solution in the tissue, the location of the injury and patient factors, such as age, comorbidity and immunocompetence [7]. The patient in our report presented with erythema, edema, and blistering of the right forearm. Because of patient factors such as senility, malnutrition and peripheral venous insufficiency, our treatment strategy resulted in delay of complete healing which took almost 3 weeks. Deep tissue necrosis did not occur because we recognized skin lesions in early period and started necessary treatment immediately. If extravasation occurs, immediate catheter removal and rapid decision for the treatment are important for minimizing the extravasation injuries.

Conclusion

In conclusion, extravasation of peripheral parenteral nutrition solution is an adverse complication which can result in devastating effects. If it is superficial and recognized in the early period of skin lesions, immediate catheter removal and aggressive treatment strategy can minimize further tissue injury.

References

1. Pettit J, Hughes K (1993) Intravenous extravasation: mechanisms, management, and prevention. *J Perinat Neonatal Nurs* 6: 69-78.
2. Guyton AC, Hall JE (2000) Regulation of acid-base balance. In: *Textbook of Medical Physiology* (10th edn.) W.B. Saunders Company, Philadelphia.
3. Guyton AC, Hall JE (2000) The body fluid compartments: extracellular and intracellular fluids: interstitial fluid and In: *Textbook of Medical Physiology* (10th edn.), W.B. Saunders Company, Philadelphia
4. Vesely TM, Stranz M, Masoori S, Hadaway LC (2002) The diverse and conflicting standards and practices in infusion therapy. *J Vasc Access Devices*. 7: 9-25.
5. Gault DT1 (1993) Extravasation injuries. *Br J Plast Surg* 46: 91-96.
6. Le A1, Patel S2 (2014) Extravasation of Noncytotoxic Drugs: A Review of the Literature. *Ann Pharmacother* 48: 870-886.
7. Schulmeister L (2011) Extravasation management: clinical update. *Semin Oncol Nurs* 27: 82-90