

## Salivary Gland Sialolithiasis

Daniel Guerra<sup>1</sup>, Gerardo Rivera Silva<sup>2</sup> and Héctor R. Martínez Menchaca<sup>3\*</sup>

<sup>1</sup>Department of Health Science, Monterrey Institute of Technology and Higher Education, Mexico

<sup>2</sup>Department of Health Science, University of Monterrey, Mexico

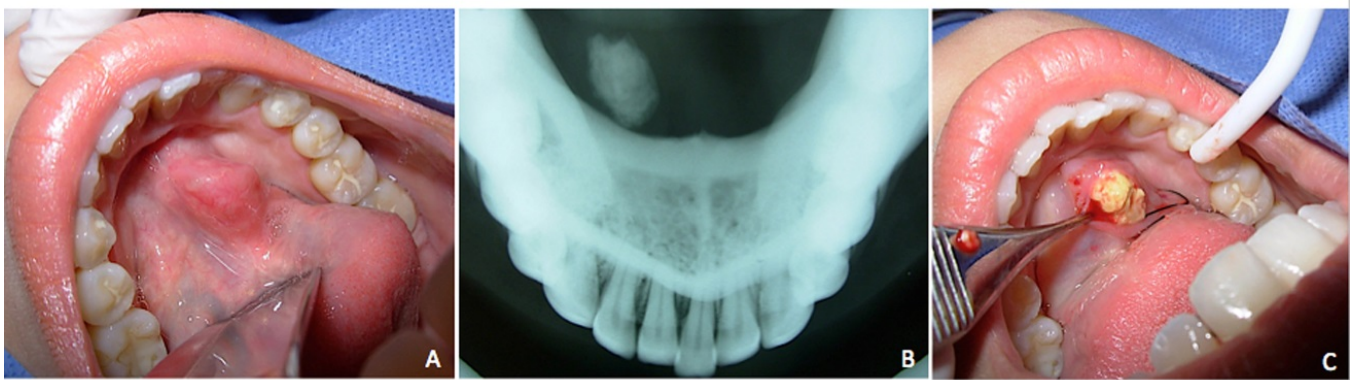
<sup>3</sup>Department of Pediatric Dentistry, University of Louisville, USA

\*Corresponding author: Hector R Martinez Menchaca, Department of Pediatric Dentistry, University of Louisville, 501 S Preston St, 40202, Louisville, KY, USA, Tel: 5028527601; Fax: 502 852 1496; E-mail: [hector.martinez@louisville.edu](mailto:hector.martinez@louisville.edu)

Rec date: Sep 22, 2015, Acc date: Sep 25, 2015, Pub date: Sep 28, 2015

Copyright: © 2015 Guerra D, et al. This is an open-access article distributed under the terms of the Creative Commons Attribution License, which permits unrestricted use, distribution, and reproduction in any medium, provided the original author and source are credited.

### Clinical Images



**Figure 1:** (A) Oral mucosa with normal appearance and a swollen and inflamed area on the right floor of the oral cavity. (B) Occlusal radiography revealed the presence of a typical radiopaque mass of a sialolith. (C) The sialolith was excised after local anesthesia.