

Ruptured Ectopic Pregnancy after Bilateral Tubal Ligation: A Case Report

Akaba GO^{1*}, Ekele BA¹, Onafowokan O¹, Nombur LI¹, Oluwole OP² and Nwana EJC²

¹Department of Obstetrics and Gynecology, University of Abuja Teaching Hospital, Gwagwalada, Abuja, Nigeria

²Department of Pathology, University of Abuja Teaching Hospital, Gwagwalada, Abuja, Nigeria

Abstract

Tubal sterilization is considered a permanent method of contraception because it is highly effective in preventing pregnancy and therefore failure is rare. The likely hood of ectopic pregnancy occurring is increased when pregnancy occurs after sterilization. In this paper, we report the case of a 38 year old para 3⁺¹, 3 alive that had bilateral tubal ligation during her third caesarean section for delivery of her last child three years prior to presentation. She presented with 10 weeks history of amenorrhoea and 6 weeks history of lower abdominal pain. She subsequently had laparotomy for left ruptured ectopic pregnancy.

Clinicians should always consider the diagnosis of ectopic pregnancy in any woman of reproductive age presenting with lower abdominal pain and amenorrhea even if she has had tubal sterilization. Women who have had bilateral tubal ligation should be counseled on the remote chance of failure and the need to present early if they have symptoms and signs suggestive of pregnancy.

Keywords: Laparotomy; Caesarean section; Pregnancy; Bilateral tubal ligation

Introduction

Female sterilization by tubal ligation is an increasingly common method of contraception, and is now the most commonly used method of fertility regulation worldwide [1,2]. It is considered a permanent form of contraception because of its low failure rate, however when there is conception it is likely to be an ectopic pregnancy which is a major cause of morbidity and mortality for women of reproductive age in the first trimester of pregnancy [3,4].

Case Report

She was a 38 year old Para 3⁺¹, 3 alive who presented with a 10 weeks history of amenorrhoea and history of 6 weeks lower abdominal pains which became generalized and persistent 2 days prior to presentation. There was no history of abnormal vaginal bleeding, dizziness or fainting attacks.

Two weeks prior to presentation, she was admitted in another hospital for one week and was managed as a case of pelvic inflammatory disease.

She has had 3 previous caesarean sections and bilateral tubal ligation was done for her during the last caesarean section which was three years prior to her presentation.

On physical examination, she was a febrile and was neither pale nor jaundiced. The respiratory rate was 18 cycles per minute and the chest was clinically clear. Her pulse rate was 88 beats per minute, regular and normal volume. The blood pressure was 100/80 mmHg.

The abdomen was full in the suprapubic area with a healed Pfannenstiel scar. There was generalized abdominal tenderness which was most marked in the left iliac fossa. There was guarding of the abdomen and rebound tenderness in the left iliac fossa. The vulva and vagina was normal, the cervix looked healthy with a multiparous cervical os. The uterus was about 10 weeks gestational size, there was tenderness in the left adnexum, the pouch of Douglas was full and there was marked cervical motion tenderness.

A pregnancy test done in the emergency room was positive and pelvic ultra sonography showed a bulky uterus with an empty cavity. There was a complex mass in the left adnexum that measured 4.4 cm by 3.8 cm. There was significant fluid collection in the pouch of Douglas.

A diagnosis of ruptured left ectopic pregnancy was made. She was counseled on the diagnosis and the need for emergency laparotomy. The packed cell volume was 33%. Intra-operative findings were haemoperitoneum of 800mls, there was a ruptured left ectopic gestation involving the distal stump of the left fallopian tube and the sac measured about 4 cm by 4 cm. There was also a dark-brown nodule which measured 1.5 cm by 1.5 cm noticed just below the ectopic gestation on the visceral peritoneum over the uterus; both the suspected endometriotic nodule and ectopic gestation were sent for histology. The proximal and distal stumps of the right fallopian tube were normal and measured about 2 cm and 4 cm respectively (Figure 1). The right ovary and left ovary were visualized and found to be normal. There were moderate pelvic adhesions. She had total salpingectomy. Her post operative packed cell volume done 48 hours later was 30%. The post operative course was uneventful. Histology of the excised ectopic gestation showed transmural rupture of the fallopian tube, myofibrous wall expansion by haemorrhage, degenerated chorionic villi, haemorrhage, fibrin, necrotic debris and mixed polymorphonuclear cells and aggregates of lymphocytes (Figure 2). While, the histology of the dark brown nodule showed endometrial gland with accompanied cellular stroma embedded in fibro collagenized connective tissue containing thick-walled vascular channels.

Discussion

In Nigeria and most developing countries, female sterilization has not been accepted as a popular method of contraception as a result of many factors such as ignorance, illiteracy, superstitious beliefs and some myths surrounding it [2]. Acceptability is however increasing among women undergoing caesarean section for indications that may

***Corresponding author:** Godwin O Akaba, Department of Obstetrics and Gynaecology, University of Abuja Teaching Hospital, Gwagwalada, Abuja, Nigeria, E-mail: docakabago@yahoo.com

Received September 23, 2013; **Accepted** October 15, 2013; **Published** October 17, 2013

Citation: Akaba GO, Ekele BA, Onafowokan O, Nombur LI, Oluwole OP, et al. (2013) Ruptured Ectopic Pregnancy after Bilateral Tubal Ligation: A Case Report. J Women's Health Care 2: 131. doi:10.4172/2167-0420.1000131

Copyright: © 2013 Akaba GO, et al. This is an open-access article distributed under the terms of the Creative Commons Attribution License, which permits unrestricted use, distribution, and reproduction in any medium, provided the original author and source are credited.

jeopardize their health in future pregnancies and in women who have completed their desired family size [1,2,5].

Although pregnancy after bilateral tubal ligation is uncommon, when it occurs it is a source of utmost concern to the patient and her attending physician because of the higher chance of an ectopic pregnancy which could be life threatening [3,6]. Among 10,685 women studied in a series, the risk of ectopic pregnancy within ten years of sterilization was about 7.3 per 1,000 procedures [7]. The likelihood of an ectopic pregnancy will vary according to the method of sterilization and the age at which the woman underwent the sterilization procedure. Our patient had bilateral tubal ligation during caesarean section probably by Pomeroy procedure as evidenced by the nature of the right proximal and distal stumps at surgery. It is also the commonest method used for tubal ligation in Nigeria [1,8]. The failure rate for the Pomeroy procedure is estimated at 0.25-2% [9]. It is widely believed that any pregnancies after tubal sterilization will generally occur during the first year or two years after the procedure. Surprisingly, failures are not limited to the first year or two, but continue to appear at each year during follow up as was the case in this patient [7,10,11].

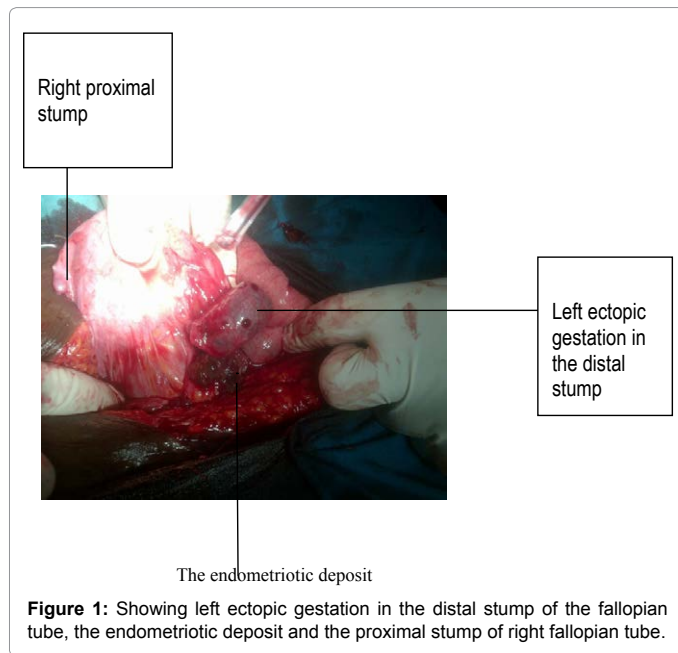


Figure 1: Showing left ectopic gestation in the distal stump of the fallopian tube, the endometriotic deposit and the proximal stump of right fallopian tube.

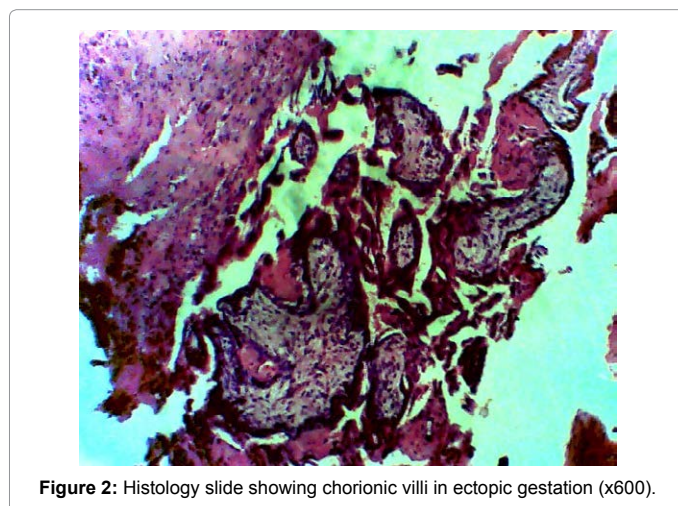


Figure 2: Histology slide showing chorionic villi in ectopic gestation (x600).

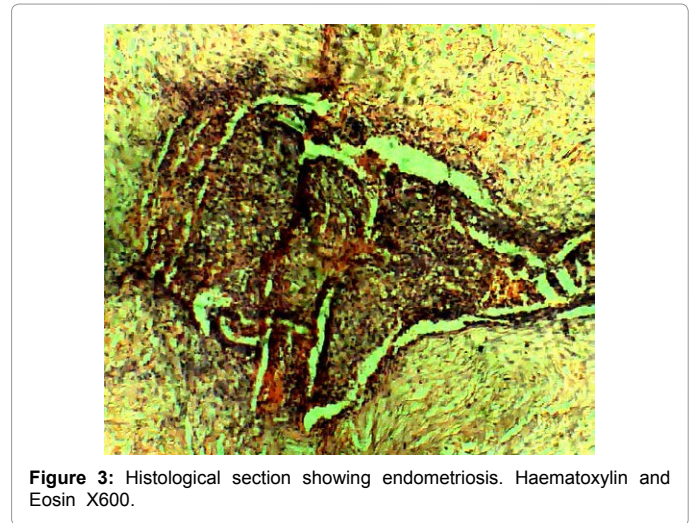


Figure 3: Histological section showing endometriosis. Haematoxylin and Eosin X600.

Diagnosis of ectopic pregnancy after bilateral tubal ligation requires a high index of suspicion so as to reduce the morbidity and mortality associated with this condition. It should therefore be considered in women of reproductive age presenting with lower abdominal pain and or amenorrhoea even if they have had tubal sterilization. In the present report she was managed earlier for one week in another hospital as a case of pelvic inflammatory disease because the index of suspicion for ectopic pregnancy was low.

Several explanations have been advanced as being responsible for ectopic pregnancy after tubal ligation which includes; tubal recanalization, formation of tubo-peritoneal fistula, luteal pregnancy, misapplication of surgery and theory of external migration of the sperm [10-12]. In the first and second instances, sperm may pass through but the fertilized ovum cannot and therefore implantation occurs classically in the distal segment [12]. It has also been suggested that in the process of recanalization there is "an abnormal reconstitution of the tubal lumen with the formation of blind pouches and slit like spaces" and that this is responsible for the greater likelihood of ectopic implantation [10,12]. The development of tubo-peritoneal fistula after tubal sterilization has also been linked to presence of endometriosis. The focal endometriosis might then be considered as a probable point for implantation [13]. When this occurs, the ectopic pregnancy is usually related to the proximal stump unlike in this patient where it was in the distal stump [13,14] (Figure 3).

Treatment of ectopic pregnancies in developing countries like Nigeria has remained largely by the surgical approach (laparotomy) due to late presentation of the patients during which the ectopic pregnancies would have ruptured with associated hemodynamic instabilities.

Therefore, ectopic pregnancy should always be considered in women of reproductive age presenting with lower abdominal pain and amenorrhoea even if they have had tubal sterilization. Women who have had bilateral tubal ligation should be counseled on the remote chance of failure and the need to present early if they have symptoms and signs suggestive of pregnancy.

References

1. Swende TZ, Hwande TS (2010) Female sterilization by tubal ligation at caesarean section in Makurdi, Nigeria. *Ann Afr Med* 9: 246-250.
2. Igberase GO, Ebeigbe PN, Umeora OU, Abedi HO (2011) Bilateral tubal ligation in a rural hospital in the Niger Delta, Nigeria. *Niger J Clin Pract* 14: 137-139.

3. Napolitano PG, Vu K, Rosa C (1996) Pregnancy after failed tubal sterilization. *J Reprod Med* 41: 609-613.
4. Musa J, Daru PH, Mutahir JT, Ujah IA (2009) Ectopic pregnancy in Jos Northern Nigeria: prevalence and impact on subsequent fertility. *Niger J Med* 18: 35-38.
5. Adesiyun AG (2007) Female sterilization by tubal ligation: a re-appraisal of factors influencing decision making in a tropical setting. *Arch Gynecol Obstet* 275: 241-244.
6. Berker B, Kabukw C, Dokmeci F (2002) Tubal Pregnancy after pomery sterilization. *Arch Gynecol Obstet* 266: 56-57.
7. Peterson HB, Xia Z, Hughes JM, Wilcox LS, Tylor LR, et al. (1997) The risk of ectopic pregnancy after tubal sterilization. U.S. Collaborative Review of Sterilization Working Group. *N Engl J Med* 336: 762-767.
8. Adetoro OO (1990) Female Surgical Contraception at the University of Ilorin Teaching Hospital, Nigeria. *Trop J Obstet Gynaecol* 2: 29-13.
9. Muhiu G, Rogo KO (1987) Ruptured tubal pregnancy following tubal sterilization. *East Afr Med J* 64: 333-336.
10. Saleh F, Shukar-u-din S (2012) Tubal ectopic Pregnancy after bilateral tubal ligation. *Journal of surgery Pakistan* 17: 38-39.
11. Ameh N, Madugu NH, Bawa US, Adelaiye MS, Akpa M (2006) Tubal ectopic pregnancy after bilateral tubal ligation: A case report. *Niger J Med* 15: 453-454.
12. Shah JP, Parulekar SV, Hinduja IN (1991) Ectopic pregnancy after tubal sterilization. *J Postgrad Med* 37: 17-20.
13. Rock JA, Parmley TH, King TM, Laufe LE, Su BS (1981) Endometriosis and the development of tuboperitoneal fistulas after tubal ligation. *Fertil Steril* 35: 16-20.
14. Cheewadhanaraks S (2004) Effect of tubal ligation on pelvic endometriosis externa in multiparous women with chronic pelvic pain. *J Med Assoc Thai* 87: 735-739.