

Rotator Cuff Tear Arthropathy: Pathophysiology, Diagnosis and Treatment

Nuri Aydin*, Okan Tok and Barış Görgün

Istanbul University Cerrahpaşa, School of Medicine, Istanbul, Turkey

*Corresponding author: Nuri Aydin, Istanbul University Cerrahpaşa, School of Medicine, Orthopaedics and Traumatology, Istanbul, Turkey, Tel: +905325986232; E-mail: nuriaydin@hotmail.com

Rec Date: Jan 25, 2014, Acc Date: Mar 22, 2014, Pub Date: Mar 28, 2014

Copyright: © 2014 Aydin N, et al. This is an open-access article distributed under the terms of the Creative Commons Attribution License, which permits unrestricted use, distribution, and reproduction in any medium, provided the original author and source are credited.

Abstract

The term rotator cuff tear arthropathy is a broad spectrum pathology but it involves common characteristic features as rotator cuff tear, leading to glenohumeral joint arthritis and superior migration of the humeral head. Although there are several factors described causing rotator cuff tear arthropathy, the exact mechanism is still unknown because the rotator cuff tear arthropathy develops in only a group of patients with chronic rotator cuff tear. The aim of this article is to review pathophysiology of rotator cuff tear arthropathy, to explain the diagnostic features and to discuss the management of the disease.

Keywords: Arthropathy; Glenohumeral joint; Articular fluid

Introduction

The term rotator cuff tear arthropathy is used to describe a broad spectrum of pathology varying from a rotator cuff tear to a destructive arthritis which had been first described by Neer in 1983 [1]. Most of the patients have several characteristics in common such as rotator cuff tear glenohumeral joint arthritis and superior migration of the humeral head [2]. Although the mechanical, nutritional and inflammatory factors are described, the exact mechanism is still unclear. This clinical condition develops only in a group of patients who suffer from chronic rotator cuff tear. Due to the indefinite nature of the disease, the management of rotator cuff tear arthropathy is rather difficult.

The aim of this article is to review the pathophysiology of the rotator cuff tear arthropathy, to describe the physical examination findings, imaging properties and to discuss the management of the disease.

Pathophysiology

The glenohumeral joint is a complex structure which has an excessive range of motion capability. Due to the lack of static stability, the biomechanics of the glenohumeral joint depend on soft tissues, and rotator cuff plays a vital role among them [3,4]. The development of the rotator cuff tear and its progress towards becoming massive in size, may resulting loss of dynamic stabilization of the joint.

There are two main theories that describe the pathophysiology of the rotator cuff tear arthropathy; cuff-tear theory and crystal-mediated theory. Crystal-mediated arthropathy theory was described by Halverson et al. in 1981. According to this theory; rotator cuff tear arthropathy originates from hydroxy-apatite crystals-induced phagocytosis causing degenerative process in glenohumeral joint [5]. Identification of hydroxyapatite and calcium phosphate crystals in disease-affected soft tissues supports the hypothesis that the rotator cuff tear arthropathy was actually an inflammatory based disorder. The disease cycle consists of crystal phagocytosis and soft tissue degeneration, induces the arthropathy and joint instability [4,6,7].

Rotator cuff tear not only plays a role at the beginning of the disease, but also a developed rotator cuff tear is a result of the inflammatory process.

On the other hand, in 1983, Neer et al. propounded the principles of the cuff-tear theory by stating that the massive rotator cuff tear had been the first step in the development of the rotator cuff tear arthropathy. However, there were mechanical and nutritional factors that lead to cuff tear to an arthropathy. Mechanically, rotator cuff tear breaks the equilibrium between the forces applied to the humeral head resulting elevation, external rotation and superior migration of the humeral head. Superior migration accelerates the further cuff destruction, causing wear in acromion and superior glenoid. As a result of the absence of neurological deficit, active elevation becomes restricted and a phenomenon called pseudo paralysis develops. Afterwards, the deterioration of the rotator cuff integrity resulting articular fluid outflow, causes a decrease in quality and quantity of the synovial fluid. The leakage to the extra articular tissues affects articular cartilage in a negative way because of the lack of the necessary nutrients. Additionally, the decrease in shoulder activity due to the developing pain as the disease progresses causes reduction in articular fluid and acceleration in cartilage degeneration [1-4].

Physical Examination

A qualified and well documented medical history provides enough data to the physician. The patient's history about the pain should be thoroughly analyzed and any exacerbating factors should be questioned. Useful information such as patient's age, activity level and occupation are essential for premediating the treatment. Any detail about the past injuries, operations and systemic disorders would also be helpful for the management of the disease. In order to understand the underlying pathologies, a comprehensive systemic examination, including the entire upper extremity and cervical region should be undertaken.

The initial physical examination starts with the inspection. If there is visible muscular atrophy at the supraspinatus and infraspinatus muscles, palpating the posterior side of the scapula is usually helpful, in order to detect the muscle atrophy. In rotator cuff tear arthropathy, super lateral migration of the humeral head can also be identified by

inspection and palpation [8]. Evaluating the range of motion reveals various different results because of the deltoid muscle compensation and daily routine activities can be tolerated by some patients. However, due to muscle weakness, capsular contracture or pain caused by the rotator cuff tear arthropathy, every patient would have a certain level of movement limitation in shoulder joint. Nevertheless, this limitation can manifest itself in a pseudo paralysis form. In addition, shoulder swelling caused by increased pressure in the sub acromial bursa, called fluid sign, may also be observed [4]. Deficiency in the external rotation will be apparent. Limitation of the external rotation indicates the contracture of the anteroposterior portion of the capsule when arm adducted and the contracture of the anteroinferior portion of the capsule when the arm is abducted. Also, testing the internal rotation of the shoulder gives us information about the contracture of the posterior capsule.

The muscle strengths should be carefully examined by comparing it to the normal side. Rotator cuff muscle examination is the first step for the diagnosis and management of the disease. Supraspinatus muscle strength can be evaluated by applying downward force by 90° in shoulder abduction, internal rotation and elbow extension. The external rotation strength can be measured with the 0° arm adduction and 90° elbow flexion for infraspinatus assessment. Gerber's lift off test [9] and Burkhart's abdominal compression test [10] are defined to evaluate the subscapular is muscle (Figure 1 and Table 1). Additionally, shoulder abduction while moving hand to the mouth demonstrates the active external rotation deficiency. Rotator cuff tear arthropathy elicits the global muscle weakness and pain with shoulder

movements frequently radiating to the arm. Decrease in muscle strength and volume can be caused by not only rotator cuff tear but also neurological disorders [11]. For this reason, cervical spine examination should be done carefully prior to the beginning of the shoulder assessment to rule out a cervical spine disorder, causing referral pain to the shoulder area.

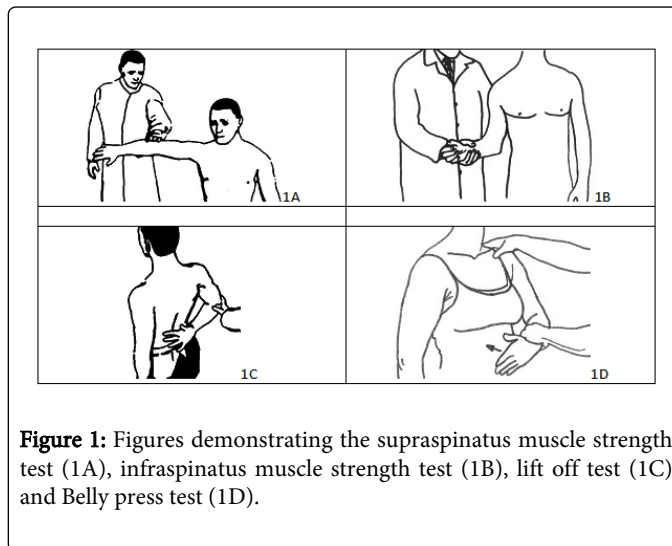


Figure 1: Figures demonstrating the supraspinatus muscle strength test (1A), infraspinatus muscle strength test (1B), lift off test (1C) and Belly press test (1D).

	Sensitivity	Specificity	Positive Predictive Value	Negative Predictive Value
Supraspinatus Muscle Strength Testa	41.1%	89.5%	88.4%	46.8%
Infraspinatus Muscle Strength Testa	41.6%	90.1%	90.6%	45.8%
Gerber's Lift Off Testb	18.8%	90.2%	50.0%	67.9%
Burkhart's Abdominal Compression Testc	76%	97%	-	-

Table 1: Diagnostic values of clinical tests for shoulder pathologies. a. Park HB, Yokota A, Gill HS, El Rassi G, McFarland EG (2005) Diagnostic Accuracy of Clinical Tests for the Different Degrees of Subacromial Impingement Syndrome. J Bone Joint Surg Am 87: 1446-1455. b. Fowler EM, Horsley IG, Rolf CG (2010) Clinical and arthroscopic findings in recreationally active patients. Sports Med Arthrosc Rehabil Ther Technol 2: 2. c. Goyal P, Hemal U, Kumar R (2010) High resolution sonographic evaluation of painful shoulder. Internet Journal of Radiology 12: 22.

Imaging

Physical examination and basic imaging methods of standard anteroposterior, axillary and scapular radiographs are often adequate for the diagnosis (Figure 2). The classical findings of arthrosis examination such as joint space narrowing, osteophytes, subchondral sclerosis and periarticular osteopenia of the shoulder joint can be seen during the imaging. Additionally, bony erosion around the greater tuberosity and proximal humerus because of the acromial contact called "femoralization" and degeneration of the coracoacromial arch and superior glenoid called "acetabularization" are characteristic findings of the rotator cuff tear arthropathy [12,13]. Due to the superior migration of the humeral head, the rotational center of the glenohumeral joint displaces superomedially.

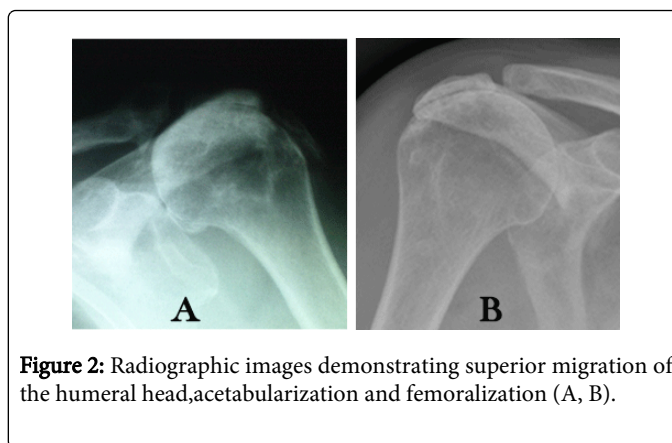


Figure 2: Radiographic images demonstrating superior migration of the humeral head, acetabularization and femoralization (A, B).

Additional imaging techniques are especially use full for operative planning and usually are not necessary for diagnostic screening.

Osseous anatomy and bone stock especially for glenoid can be evaluated better by using computed tomography (CT). The glenoid bony stock and erosion at the glenoid can be better visualized by CT. Magnetic resonance imaging (MRI) is beneficial for soft tissue evaluation, especially the rotator cuff and articular cartilage. Rotator cuff tear, fatty degeneration, retraction of the muscles and degeneration in articular cartilage care are the key aspects of treatment (Figure 3). Fluid retention which causes swelling can also be determined by MRI.

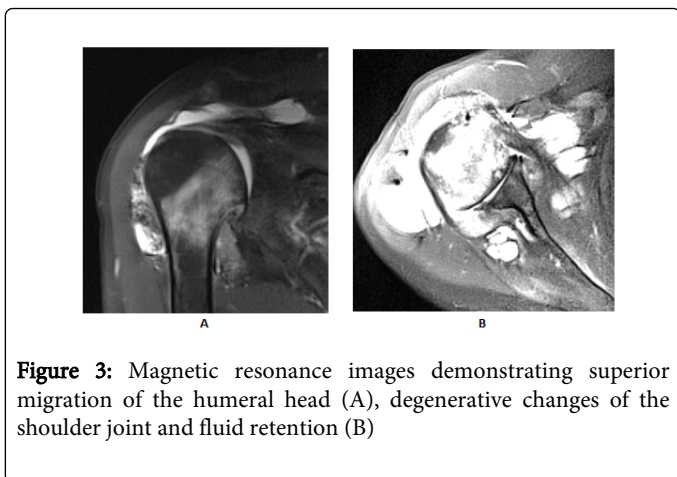


Figure 3: Magnetic resonance images demonstrating superior migration of the humeral head (A), degenerative changes of the shoulder joint and fluid retention (B)

Classification

There are two classification systems that can be used for rotator cuff tear arthropathy. The Hamada system [14] (Figure 4) is based on acromioclavicular interval (ACI) and progression of the arthropathy. There are five stages in Hamada system. In stage I, ACI is normal (>6 mm). In stage II, decrease in ACI (<5 mm) starts. In stage III, coracoacromial arch acetabularization with the decrease of ACI (<5 mm). In stage IV, narrowing of the glenohumeral joint space (IVa) and if the acetabularization is present then stage becomes IVb. In stage V, humeral collapse can be observed because of the osteonecrosis.

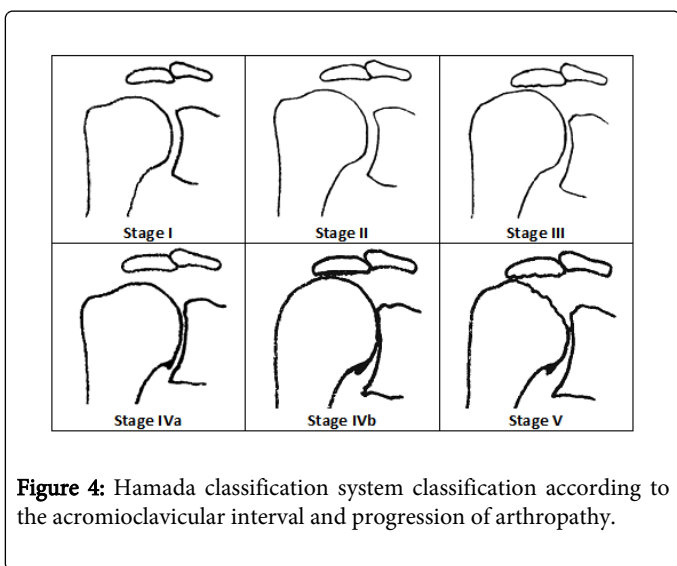


Figure 4: Hamada classification system classification according to the acromioclavicular interval and progression of arthropathy.

The See Bauer system [15] (Figure 5) is designed according to the replacement of the center of rotation due to the superior migration of

the humeral head and instability. In type IA (Centered Stable), superior migration of the humeral head is minimal, dynamic joint stabilization, coracoacromial (CA) arch acetabularization and humeral head femoralization is present. In type IB (Centered Medialized), superior migration of the humeral head is still minimal but a regression in dynamic joint stability is observed. Also, medial erosion of the glenoid accompanies the acetabularization and femoralization. In type IIA (Decentered Limited Stable), degeneration of the anterior structures manifests itself and superior translation of the humeral head becomes obvious. Additionally, dynamic stabilisation insufficiency develops, extensive aseptabularization and femoralization minimizes the CA arch stabilization and glenoid erosion progresses superomedially. In type IIB (Decentered Unstable), deficiency in anterior structures becomes apparent, anterosuperior escape of the humeral head arises, and dynamic joint stabilization and CA arch stabilization vanishes. The Seebauer classification system provides information about the severity of the rotator cuff tear arthropathy and is beneficial for operational planning. In addition, the amount and form of the erosion at the glenoid can be defined in four types according to the preoperative radiological appearance defined by Sirveaux et al. [16]. X-rays of the shoulder joint can be adequate but CT provides better anatomic visualisation and is also beneficial for glenoidal bone stock assessment. In type E0 superior migration of the humeral head is seen without erosion of the glenoid. In type E1, there is a concentric erosion of the glenoid. Type E2 is defined by an erosion of the superior part of the glenoid and in type E3 the erosion extends to the inferior part of the glenoid.

	Type IA (Centered Stable)	<ul style="list-style-type: none"> ✓ Minimal superior migration of the humeral head ✓ Coracoacromial(CA) arch acetabularization ✓ Humeral head femoralization
	Type IB (Centered Medialized)	<ul style="list-style-type: none"> ✓ Minimal superior migration of the humeral head ✓ Regression in dynamic joint stability ✓ Acetabularization and femoralization + medial erosion of the glenoid
	Type IIA (Decentered Limited Stable)	<ul style="list-style-type: none"> ✓ Obvious superior translation of the humeral head ✓ Insufficiency in dynamic stabilization ✓ Extensive aseptabularization and femoralization + glenoid erosion progresses superomedially
	Type IIB (Decentered Unstable)	<ul style="list-style-type: none"> ✓ Deficiency in anterior structures becomes apparent ✓ Anterosuperior escape of the humeral head arises ✓ Dynamic joint stabilization and CA arch stabilization vanishes

Figure 5: The Seebauer classification system provides information about the severity of the rotator cuff tear arthropathy and is beneficial for surgical planning.

Treatment

Before planning the correct treatment for the patient, it is important to focus both on the social and medical factors such as the severity of the disease, joint motion, past surgeries, activity of the patient and comorbidities. The general treatment of cuff tear arthropathy starts with conservative treatment. This includes physical therapy, analgesics and activity modification. If the patients have intact deltoid and a stable joint motion, they may have an acceptable degree of shoulder

motion [12]. The success rate of conservative treatment ranges from 33% to 82% in the literature [17]. Muscle strengthening exercises are an important part of conservative treatment of massive rotator cuff tears. Specific exercise programs recommended in the early period can prevent glenohumeral arthropathy due to rotator cuff disease [18]. Itoi et al. found that conservative treatment to be effective especially in patients with good range of motion and muscle strength at the initial evaluation [19]. Conservative treatment not only reduces pain but also strengthens rotator cuff and scapular stabilizing muscles [20]. It was also shown that conservative treatment yields satisfactory short and mid-term results. However it was shown to be less satisfactory during long term (longer than 6 years) periods of observation. If the conservative treatment fails, the surgical treatment option is often required.

No single treatment option will be appropriate for every case, and the ideal treatment for some patients may be substantially ineffective for others in different circumstances. Detailed preoperative planning is required for success and categorizing the arthritis severity as humeral or glenoid can be useful when analyzing and treating each patients reconstructive needs [21]. Glenohumeral arthrodesis, hemiarthroplasty, resection arthroplasty and total shoulder arthroplasty procedures were performed in the past [22-24].

Various arthroplasty options have been used to treat rotator cuff tear arthropathy in patients with functional deltoid muscle and intact coracoacromial arch. First arthroplasty designs were hinged or fully constrained, creating a stable fulcrum at the glenoidal side. However, due to the excessive stress between the bone and the glenoid implant leading to implant loosening and complication rates have been

reported to be as high as 87.5% [25], this design is no longer used in the treatment of rotator cuff tear arthropathy. In order to prevent the superior translation of the humerus, semi-constrained total shoulder arthroplasties were developed. But, despite the decrease in constraint, relative to the hinged design, increased stress between the glenoid implant and the bone caused early implant loosening and failure [26-28].

Total shoulder arthroplasty has also been used in the treatment of rotator cuff tear arthropathy as another treatment option, with good initial reports (Table 2) showing better outcomes compared to the constrained and semi-constrained designs. Especially in patients with reparable rotator cuff tear, it was shown that conventional total shoulder arthroplasty can reduce pain and improve functional capacity. The first report was by Neer et al. with 91% successful results in sixteen patients with rotator cuff tear arthropathy according to his "limited goals" criteria [26], after a mean of thirty months follow up period. However, in 1988, Franklin et al. reported their retrospectively evaluated results of conventional total shoulder arthroplasty in fourteen patients and showed that 50% of patients had glenoid component loosening with 30% indicating a component revision. Additionally, 15% of patients had instability and 46% had persistent pain [29]. Also, in a study by Nwakama et al. including seven patients with rotator cuff tear arthropathy treated with conventional total shoulder arthroplasty, only 14% success rates has been shown according to the "limited goals" criteria [30]. After all, conventional total shoulder arthroplasty is contraindicated for rotator cuff tear arthropathy because of the high component failure and complication rates.

Study	Patients	Follow-up (mo)	Outcome	Revision Rate (%)	Component Failure Rate (%)	Complication Rate (%)
Total Shoulder Arthroplasty						
Neer et al. [30]	16	30	91% Successful*	6%	%30	
Franklin et al. [29]	14	37	%46 pain, %15 instability	30%	50%	50%
Nwakama et al. [30]	7	63	14% successful*	29%	43%	71%
Hemiarthroplasty						
Williams et al. [31]	21	48	86% successful*	0%	0%	
Zuckerman et al. [32]	15	28	87% satisfied	0%	0%	7%
Sanchez-Sotelo et al. [33]	37	60	67% successful*	0%	0%	5%
Goldberg et al. [49]	34	44	76% successful*	0%	0%	6%
Gadea et al. [50]	43	141.9	Constant-Murley score 46,2	38.5%		18.6%
Field et al. [51]	16	13	63%	13%	0%	38%
Reverse Total Shoulder Arthroplasty						
Sirveaux et al. [16]	80	44	96% no or little pain	4%	15%	12%
Boileau et al. [39]	21	40	95% satisfied or very satisfied	0%	0%	24%

Frankle et al. [36]	60	33	68% good or excellent	12%	3%	17%
Young et al. [43]	33	38	89% good or excellent	0%	0%	8%
Nolan et al. [52]	67	24	Constant-Murley score 62	0%	0%	%23
Ji et al. [53]	42	24	American Shoulder and Elbow score 68	7%	7%	20%
Ek et al. [54]	46	93	Constant score 74	25%	15%	37.5%

Table 2: Clinical outcomes of the patients treated with arthroplasty for rotator cuff tear arthropathy. *: According to the Neer’s “limited goal criteria”

As a treatment modality of rotator cuff tear arthropathy, hemiarthroplasty remains a viable option, especially in patients with preoperative functional range of shoulder motion. Glenoid component failure risk is avoided and stability of the implant improved by not only replacing only the humeral articular surface but also using of a large humeral head to articulate with both the glenoid and acromion. In 1996, the results of hemiarthroplasty in twenty one patients were reported by Williams et al. and it is shown that 86% of the patients had successful results according to “limited goals” criteria and none of the patients had required revision surgery after a mean of forty-eight months follow up period [31]. Additionally, the results of hemiarthroplasty in fifteen patients with rotator cuff tear arthropathy evaluated by Zuckerman et al. showed that in 87% of the patients, satisfactory results were achieved after a mean of twenty-eight months postoperative follow up period [32]. However, in a study by Sanches-Sotelo et al., anterosuperior instability in seven of the thirty patients with rotator cuff tear arthropathy treated with hemiarthroplasty was reported. Also, successful results were achieved in only 67% of the patients during a five year follow up period [33]. Hemiarthroplasty may be indicated in patients with glenohumeral arthritis without pseudoparalysis. This procedure can provide good results in patients with stable shoulder and functional subscapularis which prevents anterosuperior instability [23]. However, the concern about the use of hemiarthroplasty in patients with rotator cuff tear arthropathy remains because of the risk of bony resorption of the glenoid and acromion, humeral instability especially in patients with prior acromioplasty and limited shoulder motion improvement.

In recent years, reverse total shoulder arthroplasty has become popular for the treatment of cuff tear arthropathy. Biomechanical improvements such as moving the center of rotation distally and medially to increase the deltoid function have led to increased implant stability and range of shoulder motion [34] (Figure 6). But the deltoid muscle function is very important before undertaking reverse total shoulder arthroplasty treatment. The results of the reverse total shoulder arthroplasty in eighty patients with rotator cuff tear arthropathy were presented by Sirveaux et al. and after a mean of forty-four month follow-up period, the mean Constant score was 65.6 with 96% of patients having little or no pain [16]. Furthermore, in a study presented by Young et al. it is shown that the mean American Shoulder and Elbow Surgeons (ASES) score was 70 and 89% of patients have good or excellent results at a mean of postoperative thirty-eight months [35]. Frankle et al. reviewed sixty patients treated with reverse shoulder arthroplasty and reported significant increases in the mean ASES score from 34,4 to 68,2 points, in forward elevation

from 55,0° to 105,1° and in abduction from 41,4° to 101,8° [36]. In addition, Holcomb et al. noted satisfactory results in patients with rheumatoid arthritis treated with reverse total shoulder arthroplasty [37]. On the other hand, despite these promising results, complications after reverse total shoulder arthroplasty for rotator cuff tear arthropathy such as loosening, dislocation, instability, fracture, infection, neuropraxia and scapular notching can still be seen [16,38-41]. In studies with medium to long-term follow ups, revision rates and complication rates have been shown to be as high as 26% and 71% [39,41,42]. In recent studies, by Young et al. and Leung et al. functional outcome of hemiarthroplasty was compared to the reverse total shoulder arthroplasty in patients with rotator cuff tear arthropathy and it is found that reverse total shoulder arthroplasty is superior to hemiarthroplasty [43], but the complication rates appear to be significantly higher than those after hemiarthroplasty [44]. Because of the limited salvage options for failed reverse total shoulder arthroplasty, and until long term follow-up is available we recommend that its on elderly patients should be avoided.

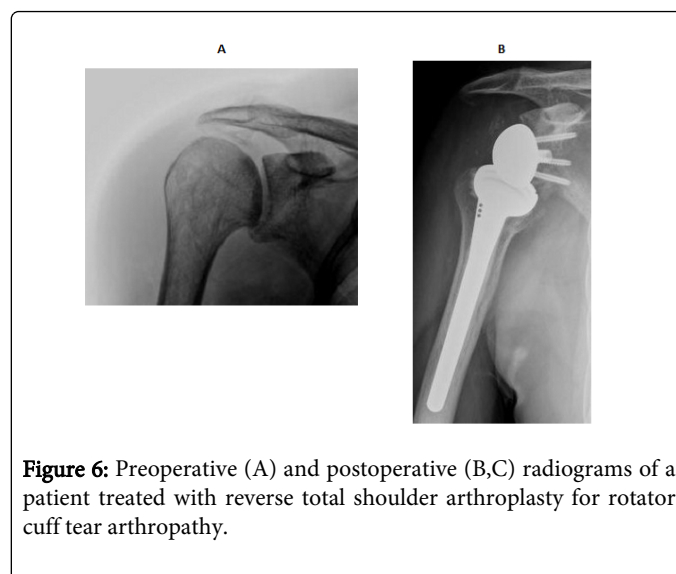


Figure 6: Preoperative (A) and postoperative (B,C) radiograms of a patient treated with reverse total shoulder arthroplasty for rotator cuff tear arthropathy.

Glenohumeral arthrodesis is a salvage procedure, only undertaken when all other surgical measures have failed. In patients with deltoid muscle deficiency the only option for pain relief is arthrodesis [4]. After the clinical use of arthroplasty, the use of glenohumeral arthrodesis has decreased in the recent years. But it is still useful in cases such as failed arthroplasty, chronic infection, severe neurological

injury and a massive rotator cuff tear in conjunction with deltoid deficiency [45]. With regard to malpositioning of the fusion, the optimum position for fixation is debatable and therefore cannot be established. For the correct position, corrective osteotomy can also be performed [46]. The ideal position of fusion is recommended as 10° to 15° of forward flexion, and 45° of internal rotation [21]. With this position the patient can comfortably reach his or her mouth, belt buckle, and contralateral shoulder. Shoulder arthrodesis with reconstruction plates has merits in that the plate can be bent easily depending on the anatomical location, there is less skin stimulation since the internal fixation used has few protrusions and adequate bone arthrodesis can be achieved [47]. Therefore, arthrodesis with a reconstruction plate is recommended by many researches [46,48]. In cases with no severe bone deficit, shoulder arthrodesis can be considered a useful method for end stage salvage.

There are several key aspect for evaluation of the patients with rotator cuff tear arthropathy and a specific treatment plan must be made for each patient. Two main key aspects are patient's age and expected activity level. It is beneficial to distinguish whether a patient's primary complaint is decrease in shoulder motion or pain. Some patients may expect a higher level of activity and a greater range of motion compared to the other patients of similar age. In such cases reverse total shoulder arthroplasty can be a more satisfying treatment choice for the patient. However, some patients may only need pain relief and such patients may be better suited for a hemiarthroplasty. Another key aspect is the presence of pseudoparalysis of the shoulder joint. Although high complication rates have been shown in the literature, a reverse total shoulder arthroplasty is often required for patients with pseudoparalysis to restore the functional motion. On the other hand, in patients with shoulder arthritis without pseudoparalysis, hemiarthroplasty can be effective especially for patients with functional subscapularis muscle and stable shoulder. Consequently, evaluating patient's age and functional expectations as well as performing a detailed clinical and radiological examination would be useful, in order to determine the appropriate treatment for a patient with rotator cuff tear arthropathy.

References

1. Neer CS 2nd, Craig EV, Fukuda H (1983) Cuff-tear arthropathy. *J Bone Joint Surg Am* 65: 1232-1244.
2. Jensen KL, Williams GR Jr, Russell IJ, Rockwood CA Jr (1999) Rotator cuff tear arthropathy. *J Bone Joint Surg Am* 81: 1312-1324.
3. Hurov J (2009) Anatomy and mechanics of the shoulder: review of current concepts. *J Hand Ther* 22: 328-342.
4. Zeman CA, Arcand MA, Cantrell JS, Skedros JG, Burkhead WZ Jr (1998) The rotator cuff-deficient arthritic shoulder: diagnosis and surgical management. *J Am Acad Orthop Surg* 6: 337-348.
5. Halverson PB, Cheung HS, McCarty DJ, Garancis J, Mandel N (1981) "Milwaukee shoulder"--association of microspheroids containing hydroxyapatite crystals, active collagenase, and neutral protease with rotator cuff defects. II. Synovial fluid studies. *Arthritis Rheum* 24: 474-483.
6. Lippitt S, Matsen F (1993) Mechanisms of glenohumeral joint stability. *Clin Orthop Relat Res* : 20-28.
7. Burkhart SS (1992) Fluoroscopic comparison of kinematic patterns in massive rotator cuff tears. A suspension bridge model. *Clin Orthop Relat Res* : 144-152.
8. Roberts CC, Ekelund AL, Renfree KJ, Liu PT, Chew FS (2007) Radiologic assessment of reverse shoulder arthroplasty. *Radiographics* 27: 223-235.
9. Gerber C, Krushell RJ (1991) Isolated rupture of the tendon of the subscapularis muscle. Clinical features in 16 cases. *J Bone Joint Surg Br* 73: 389-394.
10. Burkhart SS, Tehrany AM (2002) Arthroscopic subscapularis tendon repair: Technique and preliminary results. *Arthroscopy* 18: 454-463.
11. Snyder SJ (1993) Evaluation and treatment of the rotator cuff. *Orthop Clin North Am* 24: 173-192.
12. Ecklund KJ, Lee TQ, Tibone J, Gupta R (2007) Rotator cuff tear arthropathy. *J Am Acad Orthop Surg* 15: 340-349.
13. McFarland EG, Sanguanjit P, Tasaki A, Keyurapan E, Fishman EK, et al. (2006) The reverse shoulder prosthesis: A review of imaging features and complications. *Skeletal Radiol* 35: 488-496.
14. Hamada K, Fukuda H, Mikasa M, Kobayashi Y (1990) Roentgenographic findings in massive rotator cuff tears. A long-term observation. *Clin Orthop Relat Res* : 92-96.
15. Visotsky JL, Basamania C, Seebauer L, Rockwood CA, Jensen KL (2004) Cuff tear arthropathy: pathogenesis, classification, and algorithm for treatment. *J Bone Joint Surg Am* 86-86A Suppl 2: 35-40.
16. Sirveaux F, Favard L, Oudet D, Huquet D, Walch G, et al. (2004) Grammont inverted total shoulder arthroplasty in the treatment of glenohumeral osteoarthritis with massive rupture of the cuff. Results of a multicentre study of 80 shoulders. *J Bone Joint Surg Br* 86: 388-395.
17. Itoi E (2013) Rotator cuff tear: physical examination and conservative treatment. *J Orthop Sci* 18: 197-204.
18. Baydar M, Akalin E, El O, Gulbahar S, Bircan C, et al. (2009) The efficacy of conservative treatment in patients with full-thickness rotator cuff tears. *Rheumatol Int* 29: 623-628.
19. Itoi E, Tabata S (1992) Conservative treatment of rotator cuff tears. *Clin Orthop Relat Res* : 165-173.
20. Martin SD, Thornhill TS. Shoulder pain. In: Ruddy S, Harris ED, Sledge CB(eds) Kelley's textbook of rheumatology, (6th edn). WB Saunders, Philadelphia, pp 475-508.
21. Denard PJ, Wirth MA, Orfaly RM (2011) Management of glenohumeral arthritis in the young adult. *J Bone Joint Surg Am* 93: 885-892.
22. Scalise JJ, Ianotti JP (2008) Glenohumeral arthrodesis after failed prosthetic shoulder arthroplasty. *J Bone Joint Surg Am* 90: 70-77.
23. Nam D, Maak TG, Raphael BS, Kepler CK, Cross MB, et al. (2012) Rotator cuff tear arthropathy: evaluation, diagnosis, and treatment: AAOS exhibit selection. *J Bone Joint Surg Am* 94: e34.
24. Collins DN, Harryman DT 2nd (1997) Arthroplasty for arthritis and rotator cuff deficiency. *Orthop Clin North Am* 28: 225-239.
25. Post M (1987) Constrained arthroplasty of the shoulder. *Orthop Clin North Am* 18: 455-462.
26. Neer CS 2nd, Watson KC, Stanton FJ (1982) Recent experience in total shoulder replacement. *J Bone Joint Surg Am* 64: 319-337.
27. Orr TE, Carter DR, Schurman DJ (1988) Stress analyses of glenoid component designs. *Clin Orthop Relat Res* : 217-224.
28. Amstutz HC, Thomas BJ, Kabo JM, Jinnah RH, Dorey FJ (1988) The Dana total shoulder arthroplasty. *J Bone Joint Surg Am* 70: 1174-1182.
29. Franklin JL, Barrett WP, Jackins SE, Matsen FA 3rd (1988) Glenoid loosening in total shoulder arthroplasty. Association with rotator cuff deficiency. *J Arthroplasty* 3: 39-46.
30. Nwakama AC, Cofield RH, Kavanagh BF, Loehr JF (2000) Semiconstrained total shoulder arthroplasty for glenohumeral arthritis and massive rotator cuff tearing. *J Shoulder Elbow Surg* 9: 302-307.
31. Williams GR Jr, Rockwood CA Jr (1996) Hemiarthroplasty in rotator cuff-deficient shoulders. *J Shoulder Elbow Surg* 5: 362-367.
32. Zuckerman JD, Scott AJ, Gallagher MA (2000) Hemiarthroplasty for cuff tear arthropathy. *J Shoulder Elbow Surg* 9: 169-172.
33. Sanchez-Sotelo J, Cofield RH, Rowland CM (2001) Shoulder hemiarthroplasty for glenohumeral arthritis associated with severe rotator cuff deficiency. *J Bone Joint Surg Am* 83-83A: 1814-22.
34. Boileau P, Watkinson D, Hatzidakis AM, Hovorka I (2006) Neer Award 2005: The Grammont reverse shoulder prosthesis: results in cuff tear

- arthritis, fracture sequelae, and revision arthroplasty. *J Shoulder Elbow Surg* 15: 527-540.
35. Young SW, Everts NM, Ball CM, Astley TM, Poon PC (2009) The SMR reverse shoulder prosthesis in the treatment of cuff-deficient shoulder conditions. *J Shoulder Elbow Surg* 18: 622-626.
 36. Frankle M, Levy JC, Pupello D, Siegal S, Saleem A, et al. (2006) The reverse shoulder prosthesis for glenohumeral arthritis associated with severe rotator cuff deficiency. A minimum two-year follow-up study of sixty patients. Surgical technique. *J Bone Joint Surg Am* 88: 178-90.
 37. Holcomb JO, Hebert DJ, Mighell MA, Dunning PE, Pupello DR, et al. (2010) Reverse shoulder arthroplasty in patients with rheumatoid arthritis. *J Shoulder Elbow Surg* 19: 1076-1084.
 38. Gerber C, Pennington SD, Nyffeler RW (2009) Reverse total shoulder arthroplasty. *J Am Acad Orthop Surg* 17: 284-295.
 39. Boileau P, Watkinson D (2007) Reverse total shoulder arthroplasty for cuff tear arthropathy. In: Zukerman J, editor. *Advanced reconstruction shoulder*. Rosemont, IL:AAOS 579-90.
 40. Middernacht B, De Wilde L, Molé D, Favard L, Debeer P (2008) Glenosphere disengagement: a potentially serious default in reverse shoulder surgery. *Clin Orthop Relat Res* 466: 892-898.
 41. Werner CM, Steinmann PA, Gilbert M, Gerber C (2005) Treatment of painful pseudoparesis due to irreparable rotator cuff dysfunction with the Delta III reverse-ball-and-socket total shoulder prosthesis. *J Bone Joint Surg Am* 87: 1476-1486.
 42. Walch G, Wall B, Mottier F (2006) Complications and revision of the reverse prosthesis, a multicenter study of 457 cases. In: Walch G, Boileau P, Mole D, Favard L, Levigne C, Sirveaux F, editors. *Reverse shoulder arthroplasty: clinical results, complications, revision*. Montpellier, France: Sauramps Medical 335-52.
 43. Young SW, Zhu M, Walker CG, Poon PC (2013) Comparison of functional outcomes of reverse shoulder arthroplasty with those of hemiarthroplasty in the treatment of cuff-tear arthropathy: a matched-pair analysis. *J Bone Joint Surg Am* 95: 910-915.
 44. Leung B, Horodyski M, Struk AM, Wright TW (2012) Functional outcome of hemiarthroplasty compared with reverse total shoulder arthroplasty in the treatment of rotator cuff tear arthropathy. *J Shoulder Elbow Surg* 21: 319-323.
 45. Clare DJ, Wirth MA, Groh GI, Rockwood CA Jr (2001) Shoulder arthrodesis. *J Bone Joint Surg Am* 83-83A: 593-600.
 46. Groh GI, Williams GR, Jarman RN, Rockwood CA Jr (1997) Treatment of complications of shoulder arthrodesis. *J Bone Joint Surg Am* 79: 881-887.
 47. Chun JM, Byeon HK (2009) Shoulder arthrodesis with a reconstruction plate. *Int Orthop* 33: 1025-1030.
 48. Richards RR, Sherman RM, Hudson AR, Waddell JP (1988) Shoulder arthrodesis using a pelvic-reconstruction plate. A report of eleven cases. *J Bone Joint Surg Am* 70: 416-421.
 49. Goldberg SS, Bell JE, Kim HJ, Bak SF, Levine WN, et al. (2008) Hemiarthroplasty for the rotator cuff-deficient shoulder. *J Bone Joint Surg Am* 90: 554-559.
 50. Gadea F, Alami G, Pape G, Boileau P, Favard L (2012) Shoulder hemiarthroplasty: outcomes and long-term survival analysis according to etiology. *Orthop Traumatol Surg Res* 98: 659-665.
 51. Field LD, Dines DM, Zabinski SJ, Warren RF (1997) Hemiarthroplasty of the shoulder for rotator cuff arthropathy. *J Shoulder Elbow Surg* 6: 18-23.
 52. Nolan BM, Ankerson E, Wiater JM (2011) Reverse total shoulder arthroplasty improves function in cuff tear arthropathy. *Clin Orthop Relat Res* 469: 2476-2482.
 53. Ji JH, Jeong JY, Song HS, Ok JH, Yang SJ, et al. (2013) Early clinical results of reverse total shoulder arthroplasty in the Korean population. *J Shoulder Elbow Surg* 22: 1102-1107.
 54. Ek ET, Neukom L, Catanzaro S, Gerber C (2013) Reverse total shoulder arthroplasty for massive irreparable rotator cuff tears in patients younger than 65 years old: results after five to fifteen years. *J Shoulder Elbow Surg* 22: 1199-1208.