

Right Phrenic Nerve Palsy Post Coronary Artery Bypass Grafting (CABG) without Harvesting Right Internal Mammary Artery (RIMA): A Rare and Unexpected Complication

Mohamed A Alassal^{1,2,3*}, Nouf F Baker¹, Ayman M Shaalan^{1,2}, Sumanth N Raghunayakula³, Eman Elwakeel⁴, Hany Elrakhawy² and Mohamed F Ibrahim¹

¹King Salman Heart Center, King Fahd Medical City, Riyadh, Saudi Arabia

²Cardiothoracic Surgery Department, Benha University, Egypt

³PAAMCC, Arar, Saudi Arabia

⁴Benha University, Anatomy and Embryology Department, Egypt

*Corresponding author: Mohamed Abdulwahab Alassal, King Salman Heart Center, King Fahd Medical City, Riyadh, Saudi Arabia, Tel: +966112889999, +966543178563; Email: dmohamedabdelwahab@gmail.com

Received date: Sep 20, 2015; Accepted date: Oct 26, 2015; Published date: Oct 30, 2015

Copyright: ©2015 Alassal MA, et al. This is an open-access article distributed under the terms of the Creative Commons Attribution License, which permits unrestricted use, distribution, and reproduction in any medium, provided the original author and source are credited.

Introduction

Phrenic nerve palsy has many causes, and can be caused by lesions anywhere along its course, as it travels from the neck to pierce the diaphragm. The epidemiology will therefore match that of the underlying etiology [1].

Most of the cases are idiopathic or even thought to be post viral. Common causes include: tumors like bronchogenic carcinoma or neuroblastoma, trauma like post thoracic or neck surgeries or penetrating injuries, neuromuscular diseases, inflammation, direct compression from aortic aneurysm or cervical osteophytes, toxins like some spider or lizard toxins, alcoholic neuropathy, or endocrinal causes like hypothyroidism or diabetes mellitus (diabetic autonomic neuropathy) which enhances and exaggerates the effect of the other factors [2-4].

It is known that the incidence of phrenic nerve injury post open heart surgery is about 10% due to its close relation to the pericardium and to the mammary artery. This makes it, especially the left one, very liable to injury due to direct trauma of the nerve itself or its blood supply during left internal mammary artery (LIMA) harvesting, thermal injury due to local ice or cold saline on the heart or direct cautery trauma, or over traction of the pericardium during heart exposure [4-6].

Diaphragmatic paralysis is a relatively common disease. In many cases, it is mildly or not symptomatic. Therefore, it is often undiagnosed or underappreciated. However, in some situations diaphragmatic paralysis causes severe symptoms (such as severe orthopnea and dyspnea) that must direct to the appropriate work up. Diagnosis in most cases should be confirmed by the sniff test with additional supportive tests such as upright and supine lung function, X-ray fluoroscopy and respiratory muscle forces. Correct diagnosis prevents unnecessary work up and facilitates recognition of various diseases; some of them are treatable (such as inflammatory or endocrine diseases) and enhances work up for comorbidities, such as sleep abnormalities. In many patients no specific therapy is needed and in up to a quarter of them, paralysis or symptoms will improve spontaneously. The other may need nocturnal ventilator assist. In selected cases diaphragmatic plication or pacing should be considered [6,7]. Bilateral phrenic nerve injury may lead to ventilator dependence, whereas unilateral injury may decrease pulmonary function, resulting in reduction in physical capacity [8].

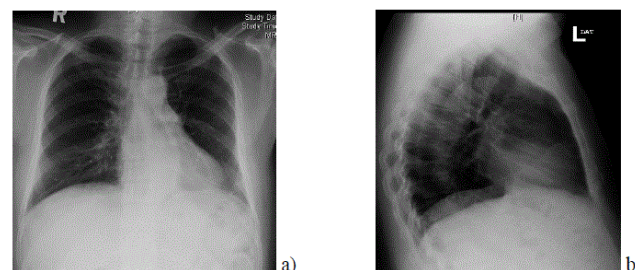


Figure 1: Preoperative CXR. (a) Postero-anterior and (b) lateral views, showing normal diaphragmatic level on both sides.

Almost all literature about phrenic nerve injury post “CABG using LIMA as a graft” were talking about left phrenic nerve injury and left hemi-diaphragmatic paralysis which could be a common complication post CABG [7-9].

Our case is a 55-years-old obese male, with BMI 35.2. He has a known history of heavy cigarette smoking, dyslipidemia, hypertension and diabetes mellitus on insulin since 20 years. He had inferior wall myocardial infarction and a coronary angiography showed severe triple vessel disease, so after consensus he was advised for CABG.

Preoperative routine work up was done, including chest X-ray (CXR) which was unremarkable (Figure 1). Transthoracic echocardiography (TTE) showed left ventricular ejection fraction of 45-50%, multiple regional wall motion abnormalities, no valve lesions, diastolic dysfunction grade II, no pericardial effusion, normal RV dimensions and functions.

Operation: Conventional CABG X4 grafts was done for him on pump using double stage single venous cannula with mild hypothermia 32 Co: LIMA to LAD, saphenous vein graft (SVG) to posterior descending artery (PDA), SVG to obtuse marginal (OM1) and SVG to diagonal artery.

He tolerated the surgery well and shifted to intensive care unit (ICU) in a stable condition. In the ICU, he remained stable, was weaned from the ventilator and extubated next day morning. He was shifted to cardiac surgery ward to complete his routine postoperative course which was unremarkable, except for unexplained dyspnoea on mild exertion and shortness of breath (SOB) grade II to III. Pre-

discharge laboratory results and echocardiography could not detect any reason for his SOB, but his post-operative CXR showed significantly higher right diaphragmatic copula (Figure 2a).

Initially, he was diagnosed as right lower lobe atelectasis or collapse for chest physiotherapy and more ambulation and discharged home with an appointment as an outpatient to the pulmonologist for further evaluation and possible management. After discharge, he had progressive dyspnea grade III to IV without any improvement. The right diaphragmatic copula in CXR was raised even higher. Computerized tomography (CT) chest showed elevated right hemi-diaphragm, without sub-diaphragmatic masses or collection. Pulmonary function tests revealed restrictive type of lung dysfunction. Further evaluation by electrophysiological nerve conduction study was done, which showed electro diagnostic evidence of right phrenic neuropathy of axonal type, with normal left phrenic nerve study (Table 1 and Figure 3).

After confirming the diagnosis of right phrenic nerve palsy, thoracic surgery consultation was sought for possible diaphragmatic plication or pacing; but, the patient refused surgery and preferred conservative management in the form of chest physiotherapy and medical treatment.

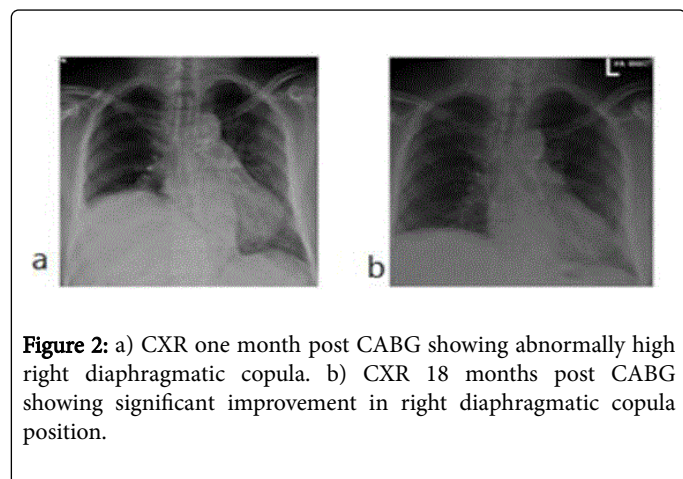


Figure 2: a) CXR one month post CABG showing abnormally high right diaphragmatic copula. b) CXR 18 months post CABG showing significant improvement in right diaphragmatic copula position.

After 18 months, he started to improve and his dyspnea changed from grade III-IV to grade I-II with better CXR, which showed lower level of right diaphragmatic copula (Figure 2b).

Discussion

The diagnosis of phrenic nerve injury and diaphragmatic paralysis always represents a continuous challenge because the symptoms usually are misinterpreted with other cardiac causes of SOB like congestive heart failure, recurrent pulmonary embolism, or other non-cardiac or general causes like anemia, psychological disorders or respiratory diseases [9,10].

The literature dealing with phrenic nerve injury post CABG advocated that left phrenic nerve damage is much more frequent than right, and in the study by Canbaz et al., they found that in all the cases post CABG the injured nerves were the left ones [11]. However, both the left and right nerves have been equally exposed to cardiopulmonary bypass and systemic hypothermia, suggesting that the hypothermic cardiopulmonary bypass is not in itself the cause for the damage. It is known that the left ventricle is the major target for myocardial protection in open heart surgery. During cardiac surgeries,

topical cooling is frequently oriented to the left ventricle, when we apply ice slush around the left ventricle and in to the left portion of the pericardial cavity. For this reason, the left phrenic nerve thermal injury is more frequent than the right phrenic nerve, which is frequently preserved from cold injury [2,6,9,11].

Although as in our case, we did not harvest RIMA as a graft, and we did not use ice slush or cold saline, we assume that most probably the right phrenic nerve injury happened during central venous line insertion; as the patient was obese with a short fatty neck. And this was nearly similar to cases documented in non-cardiac surgeries where the right phrenic nerve was directly injured by a needle during injection of central venous line [4,5,10].

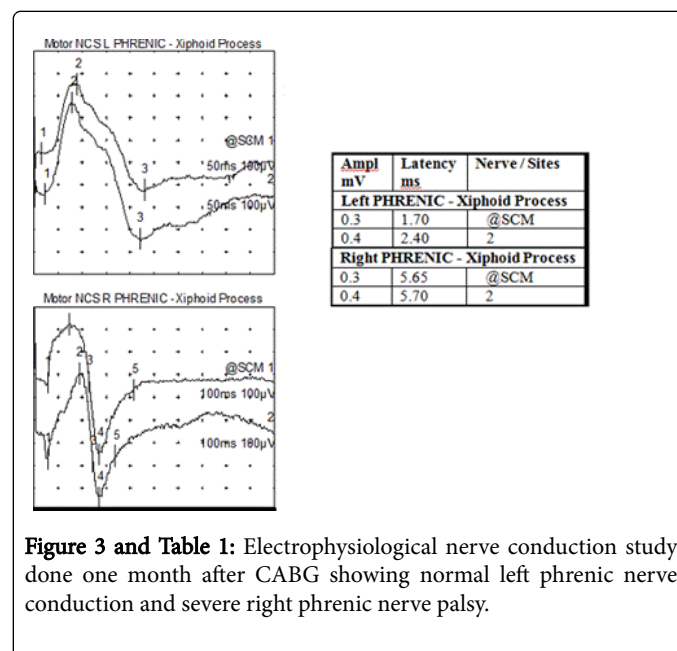


Figure 3 and Table 1: Electrophysiological nerve conduction study done one month after CABG showing normal left phrenic nerve conduction and severe right phrenic nerve palsy.

Most of the literature confirmed that the elevated diaphragm on CXR and diaphragmatic motion on ultrasound are valuable methods for assessing phrenic nerve injury, but the best diagnostic method is electrophysiological nerve conduction study [5,10], and this was how we have confirmed the diagnosis in our case.

In our case, nerve conduction study (NCS) after one month, and follow-up study after 18 months post-operatively showed significant improvement (Figure 3) and the CXR showed lower right diaphragmatic copula than before without surgical intervention (Figure 2b). This is in contrary to a study done by Kaufman and his coauthors, and another study by Canbaz [10-12], which has emphasized the need for early surgical intervention in such cases in the form of diaphragmatic plication or diaphragmatic pacing.

Conclusion

- Our case is unique, to the best our knowledge, because it is the 1st “documented case” with right phrenic nerve injury and right diaphragmatic paralysis “post CABG surgery”, without using RIMA as a conduit, and without using ice slush or cold saline
- Right phrenic nerve palsy could happen post CABG and may be exaggerated in diabetic patients (who already suffer from diabetic neuropathy), presented by nonspecific symptoms requiring more

specific investigations, especially electrophysiological and nerve conduction studies

- Ultrasound guided central venous line insertion is highly recommended specially in obese patients
- Conservative management in cases of unilateral diaphragmatic paralysis post CABG is practical and effective and spontaneous recovery can take up to 2 years especially if a progressive generalized neuropathic process is not present

References

1. Yatin M, Mayank V, Ajmer S, Naresh T (2008) Incidence and management of diaphragmatic palsy in patients after cardiac surgery. *Indian J Crit Care Med* 12: 91-95.
2. Stojkovic T, De seze J, Hurtevent JF, Fourrier F, Vermersch P (2003) Phrenic nerve palsy as a feature of chronic inflammatory demyelinating polyradiculoneuropathy. *Muscle Nerve* 27: 497-499.
3. Ferguson MK (2007) *Difficult decisions in thoracic surgery, an evidence-based approach*. Springer Verlag ISBN: 1846283841.
4. Takasaki Y, Arai T (2001) Transient right phrenic nerve palsy associated with central venous catheterization. *Br J Anaesth* 87: 510-511.
5. Rigg A, Hughes P, Lopez A, Filshie J, Cunningham D, et al. (1997) Right phrenic nerve palsy as a complication of indwelling central venous catheters. *Thorax* 52: 831-833.
6. Maish MS (2010) The diaphragm. *Surg Clin North Am* 90: 955-968.
7. Han KY, Bang HJ (2015) Exercise therapy for a patient with persistent dyspnea after combined traumatic diaphragmatic rupture and phrenic nerve injury. *PM R* 7: 214-217.
8. Crausman RS, Summerhill EM, McCool FD (2009) Idiopathic Diaphragmatic Paralysis: Bell's palsy of the Diaphragm? *Lung* 187: 153-157.
9. Shields TW, LoCicero J, Ponn RB (2005) *General thoracic surgery*. Lippincott Williams & Wilkins. ISBN: 078173889X.
10. Matthew R, Kaufman MD, Andrew I, Elkwood MD, Michael I, et al. (2013) Surgical Treatment of Permanent Diaphragm Paralysis after Interscalene Nerve Block for Shoulder Surgery. *Anesthesiology* 119: 250-252.
11. Canbaz S, Turgut N, Halici U, Balci K, Ege T, et al. (2004) Electrophysiological evaluation of phrenic nerve injury during cardiac surgery-a prospective, controlled, clinical study. *BMC Surg* 4: 2.
12. Kaufman MR, Elkwood AI, Colicchio AR, CeCe J, Jarrahy R, et al. (2014) Functional restoration of diaphragmatic paralysis: an evaluation of phrenic nerve reconstruction. *Ann Thorac Surg* 97: 260-266.