

## Renal Hilum Study for Anomalous Vasculature

Kamal Singh\*, Priyanka Parmar, Aarti Rohilla, Namrata Katoch, Kamalpreet Kaur, Jyoti Rohilla and Usha Verma

Department of Anatomy, Pt. B. D. Sharma PG Institute of Medical Sciences, Rohtak, India

\*Corresponding author: Kamal Singh, Department of Anatomy, Pt. B. D. Sharma Post Graduate Institute of Medical Sciences, Rohtak, Haryana, India, Tel: +91-9812531007; E-mail: drkamalanatomy@gmail.com

Rec date: June 13, 2015; Acc date: July 6, 2016; Pub date: July 13, 2016

Copyright: © 2016 Singh K, et al. This is an open-access article distributed under the terms of the Creative Commons Attribution License, which permits unrestricted use, distribution, and reproduction in any medium, provided the original author and source are credited.

### Abstract

The knowledge of variations of blood vessels of kidney is important during operative and diagnostic procedures. The present study contributes in making the clinicians aware of possible variations in renal vascular pedicle. 48 kidney specimens were studied for renal vessels in the Department of Anatomy, Pt. B. D. Sharma PGIMS, Rohtak. Out of 48 specimens, two kidneys were found to have anomalous vasculature. One kidney (Right Side) was observed to have triple renal veins along with an accessory renal artery. One other kidney (Left Side) exhibited triple renal artery. The study is being carried out till date and is planned for an extensive research for another few years to review and to collect more data in this perspective.

**Keywords:** Vasculature; Kidney; Variation

### Introduction

The Kidney is a retroperitoneal organ and is supplied by single renal artery and drained by single vein [1]. Renal arteries arise from lateral aspect of abdominal aorta and enter the kidneys through hilum. Renal veins are also bilateral and drain into inferior vena cava. Left renal vein is longer than right one because inferior vena cava is placed more on the right side of the body [2]. For this reason the left kidney is the preferred side for live donor nephrectomy [3].

The medial border of kidney presents a hilar concavity. From before backwards, structures passing through the hilum are - renal vein, renal artery and pelvis of ureter. In addition, renal lymphatics, nerves and perinephric fat also traverse through it [4].

Variations of renal vessels are frequently observed but variations in renal arterial pattern are more common as compared to venous pattern. Accessory renal artery usually arises from aorta and is the most common variation. Rarely, it takes origin from coeliac or superior mesenteric or from common iliac arteries. It develops as a result of persistent embryonic lateral splanchnic arteries [5]. Additional renal veins may be found infrequently on the right side (5%) [6]. Several variations such as double renal veins, triple renal veins, renal collar, retro aortic renal veins have been reported [1,3,7].

The knowledge of renal vasculature variations is of paramount importance to anatomists and clinicians also during various surgical procedures. A number of radiological studies related to renal vasculature have been carried out till date but cadaveric studies are scanty. Moreover open visualization is always better introspection than any of the closed procedure. Keeping this in view, the present study was undertaken.

### Material and Methods

The present study was conducted in 48 adult cadaveric kidneys in 24 cadavers during undergraduate students teaching in the Department of Anatomy, Pt. B. D. Sharma PGIMS, Rohtak for three consecutive years.

Kidney along with its blood supply was carefully dissected. Thereafter, the relationships of structures present in hilum along with any variations present were noted. The study is still being carried out.

### Observations

Two kidneys out of 48 specimens displayed variations associated with vessels. In all the specimens, the normal relationship of renal vessels and ureter was preserved. The renal vessels were in front of renal pelvis. The arrangement of structures at hilum from anterior to posterior was as follows: Vein, Artery and Pelvis (Ureter).

Anomalies	Incidence	%
In Renal Vein	1/48	2.083%
In Renal Artery	2/48	4.167%
Co-existence	1/48	2.083%

**Table 1:** Incidence of anomalous renal vessels.

Anomalous renal veins were seen in 2.083% cases whereas renal artery variations were observed in 4.167% of cases. 2.083% cases showed co-existing renal arterial and venous anomalies (Table 1).

Side	Frequency	%
Right Kidney	2/48	4.167%
Left Kidney	1/48	2.083%

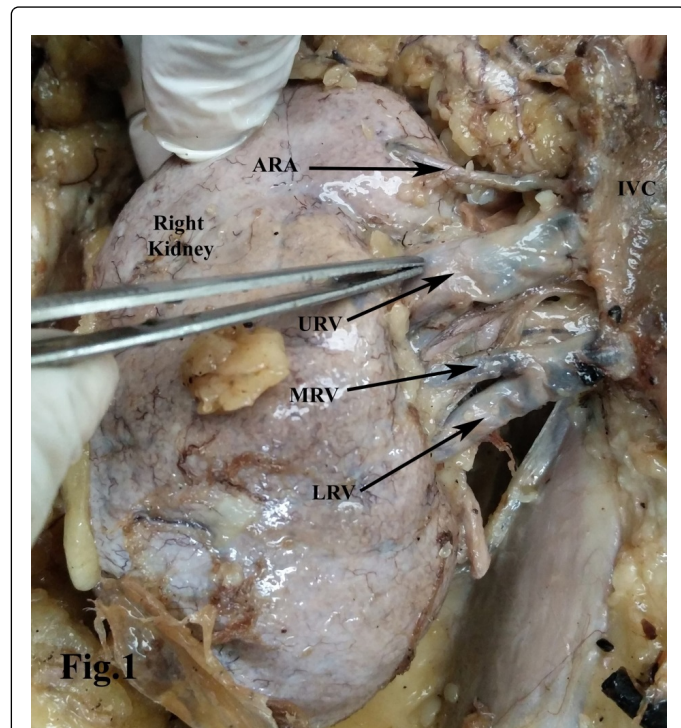
**Table 2:** Sidewise frequency of anomalous renal vessels.

Anomalous renal vessels were predominantly observed more on right side (4.167%) as compared to left side (2.083%) (Table 2).

### Specimen-I

One kidney (right side) showed three renal veins namely upper, middle and lower. Upper right renal vein emerged from upper part of

hilum, passed superomedially to drain into inferior vena cava. Middle and lower right renal veins unite together and then passed medially to drain into inferior vena cava. All these veins passed anterior to ureter. An accessory right renal artery was also observed in the same specimen. It took origin from abdominal aorta and reached its upper pole (Figure 1).



**Figure 1:** Right Kidney In Situ showing: Inferior Vena Cava (IVC), Additional Renal Artery (ARA), Upper Renal Vein (URV), Middle Renal Vein (MRV), Lower Renal Vein (LRV).

## Specimen-II

Another kidney (left side) was observed to have three renal arteries namely upper, middle and lower. Main renal artery along with additional arteries took origin from abdominal aorta. Upper renal artery was seen overriding and obliquely crossing the middle renal artery. All the three arteries enter the kidney through hilum (Figure 2).

## Discussion

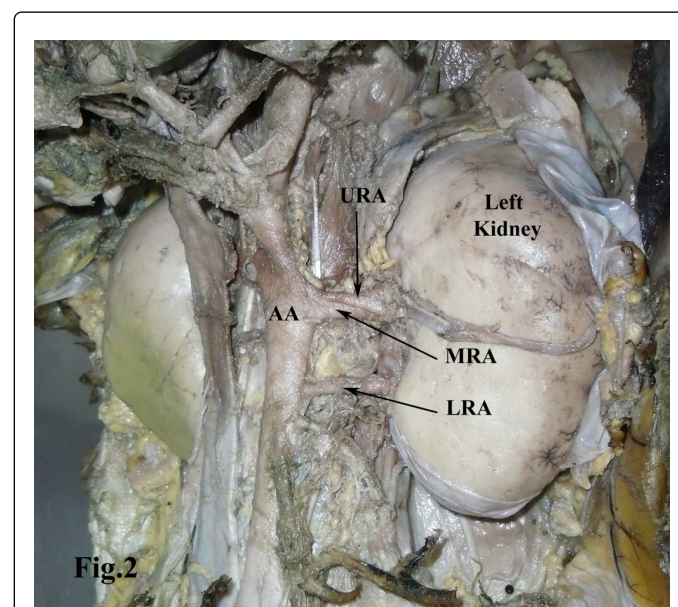
Kidneys develop in the pelvic cavity initially and ascend to lumbar region during further development. Renal arteries arise as lateral splanchnic branches from the dorsal aorta, common iliac and internal iliac arteries during embryonic life. As kidneys ascend the caudally placed renal arteries degenerate whereas new cranial branches arise to supply the developing kidneys. Arterial supply thus shifts from common iliac artery to abdominal aorta. Lateral splanchnic arteries when persist during embryonic development leads to presence of additional renal arteries.

During the development of inferior vena cava, three pairs of parallel longitudinal venous channels develop namely posterior-cardinal, sub-cardinal and supra-cardinal veins. The latter two form dorsal and ventral anastomotic channels in the beginning, later on dorsal channels

regress and ventral channel persists resulting in the formation of renal veins [8].

Various studies had been carried out on renal vessels till date. Raghu Jetti [9] and Vaghela et al. [10] studied the length of renal vein and thus differed from our study as this parameter was not taken into account in the present study.

A high degree of variations is exhibited by renal vessels especially arteries [11]. Present study also showed high incidence (4.167%) of renal arterial variations in comparison to 2.083% incidence of variations of renal veins.



**Figure 2:** Left Kidney In Situ showing: Abdominal Aorta (AA), Upper Renal Artery (URA), Middle Renal Artery (MRA), Lower Renal Artery (LRA).

Numerous case reports had been documented about these variations by many authors. Nayak [12] reported renal veins variations to be more common on right side than left. Sampio and Passos [13] reported additional renal veins to be 3.3% on right side and 2.6% on left. On the similar context, the present study reported triple renal vein on right side. Fernandes et al. [14] and Mishra et al. [1] also reported three renal veins draining the right kidney and this finding is similar to our finding.

Supernumerary renal arteries had been reported by Pick and Anson [15] in 32.25% of kidneys. Kaneko et al. [16] reported additional renal artery in 2.4% of cadavers on the right and 1.8% on the left side in 190 cadavers. Satyapal et al. [17] reported additional renal arteries on right side in 18.6% and in 27.6% cases on left side in his study of 1244 pairs of kidneys. Edman [18] stated additional arteries incidence in the range of 8.7% to 75.7% which can cause obstruction leading to hydronephrosis. Additional renal arteries incidence was 4.167% in our study. The renal vessels and ureter relationship was preserved in all the specimens in our study. The present study thus was not in accordance with these studies. The possible reason for variability in incidence might be due to difference in the sample size taken into account.

Renal vessels variations thus, have a major implication in surgeries and transplant and this necessitates the need of examining renal hilum prior to any surgical procedure.

## Conclusion

Additional renal arteries and renal veins develop due to persistence of lateral splanchnic arteries and ventral anastomotic channel between subcardinal and supracardinal veins respectively. The renal vasculature anomalies when go unnoticed may pose risk to life during surgeries. Thus, possibility of hilar vessels variations holds importance for radiologists, surgeons and anatomist also. The present study will help in enhancing our knowledge related to gross anatomy as well as will further enrich the literature data.

## The Conflict of Interest

The authors state that they have no conflict of interest with the institution.

## References

1. Mishra GP, Bhatnagar S, Singh B (2014) Unilateral Triple Renal Veins And Bilateral Double Renal Arteries- An Unique Case Report. *Int J Anat Res* 2: 239-41.
2. Mir NS, Hassan AU, Rangrez R, Hamid S, Sabia, et al. (2008) Bilateral Duplication Of Renal Vessels: Anatomical, Medical And Surgical Perspective. *Int J Health Sci* 2: 179-185.
3. Parimala NBS, Chandrika PV, Reddy SM (2015) A Study Of Anomalies Of Left Renal Vein. *Int J Anat Res* 3: 1381-86.
4. Datta AK (2010) The Urinary System. In: *Essentials of Human Anatomy (Thorax and Abdomen)*, 9th edition, Current Books International. Kolkata pp: 295.
5. Standring S (2008) Kidney & Ureter: Vascular Supply and Lymphatic Drainage. In: *Gray's Anatomy. The Anatomical Basis of Clinical Practice (40th edn.)*. Edinburg: Churchill Livingstone Elsevier pp: 1231.
6. Satyapal KS, Kalideen JM, Haffejee AA, Singh B, Robbs JV (1999) Left Renal Vein Variations. *Surg Radiol Anat* 21: 77-81.
7. Majumdar S, Majumdar S, Roy H, Ghoshal AK (2013) A case of bilateral double renal veins. *Int J Anat Var* 6: 61-63.
8. Girdhar S, Sharma V, Gupta OP, Singh A, Babu CSR (2015) Triple Right Renal Veins And Bilateral Multiple Renal Arteries—A Case Report. *J Anat Sci* 23: 10-13.
9. Jetti R, Jevoor PS, Vollala VR, Potu BK, Ravishankar MV, et al. (2008) Multiple variations of the urogenital vascular system in a single cadaver: a case report. *Cases Journal* 1: 344.
10. Vaghela BP, Parmar AM, Trivedi BD (2013). Study of Presence of Accessory Renal Vein & Length Of Renal Vein In 100 Human Kidneys. *Indian J of Appl Res* 3: 144-145.
11. Krishnasamy N, Rao KGM, Somayaji SN, Koshy S (2010) An Unusual Case Of Unilateral Additional Right Renal Artery and Vein. *Int J of Anat Vari* 3: 9-11.
12. Nayak BS (2008) Multiple Variations of The Right Renal Vessels. *Singapore Med J* 49: E1535.
13. Sampaio FJ, Passos MA (1992) Renal Arteries: Anatomic Study For Surgical and Radiological Practice. *Surg Radiol Anat* 14: 1137.
14. Fernandes RMP, Conte FHP, Favorito LA, Figueiredo MA, Babinski MA (2005) Triple Right Renal Vein: An Uncommon Variation. *Int J Morphol* 23: 231-233.
15. Pick JW, Anson BJ (1940) The Renal Vascular Pedicle. An Anatomical Study of 430 Body halves. *J Urol* 44: 411-434.
16. Kaneko N, Kobayashi Y, Okada Y (2008) Anatomic Variations of The Renal Vessels Pertinent To Transperitoneal Vascular Control In The Management of Trauma. *Surgery* 143: 616-622.
17. Satyapal KS, Kalideen JM, Singh B, Haffejee AA, Robbs JV (2003) Why We Use The Donor Left Kidney In Live Related Transplantation. *S Afr J Surg* 41: 24-26.
18. Edman G (1954) Accessory vessels of the kidney and their diagnosis in hydronephrosis. *Acta Radiol* 42: 26-32.