

Qualitative Evaluation of Changes *In Vivo* After Interproximal Enamel Reduction

Panagiotis Michail Kanoupakis¹, Milena Dimitrova Peneva², Valentin Yordanov Moutaftchiev³

¹ Candidate Ph.D, Department of Orthodontics, Faculty of Dental Medicine, Medical University, Sofia, Bulgaria. ² Ph.D., D.M.D. Professor, Department of Paediatric Dentistry, Faculty of Dental Medicine, Medical University, Sofia, Bulgaria. ³ Ph.D., D.M.D. Professor, Department of Orthodontics, Faculty of Dental Medicine, Medical University, Sofia, Bulgaria.

Abstract

Aim: To use a laser fluorescence device to assess the qualitative changes in interproximal enamel after enamel reduction (interproximal stripping). **Methods:** Fifty-three patients (32 females and 21 males) with an average age of 15.6 years took part in the investigation. Five hundred and thirty-five tooth surfaces of upper and lower anterior teeth were reassessed at three days, ten days, and one month after enamel reduction using a laser fluorescence method (DIAGNOdent pen). Remineralisation was promoted by the application of fluoride gel and control of oral hygiene. **Results:** The results showed that there is no risk for developing caries after stripping in cases where intact enamel surfaces registered values of between 0 and 3 when measured with the laser fluorescence method used in this study. Enamel reduction appeared to be appropriate even for surfaces with initial demineralisation of the outer enamel, with values between 4 and 6, because after fluoride application the enamel status returned to within a normal range (0-3). **Conclusion:** The results from this study demonstrate that with correct diagnosis, as well as selection of intact or even slightly demineralised enamel surfaces, successful implementation of enamel reduction within enamel is possible. This technique, precisely planned, correctly executed, and followed by remineralisation procedures, eliminates the risk of enamel demineralisation.

Key Words: Interproximal Enamel Reduction, Laser Fluorescence Method, DIAGNOdent Pen, Remineralisation

Introduction

Interproximal enamel reduction is a method in orthodontics for the removal of minimal amounts of enamel from the approximal tooth surfaces [1-4].

This method is appropriate and applicable for patients with crowded anterior teeth, crowding of the dental arches, problems with the morphology and/or size of the dental crowns, and also for the elimination of the “black triangles” to improve smile aesthetics [5-8]. Interproximal enamel reduction, when performed appropriately and correctly, creates wide enough contact surfaces, which may improve stability after orthodontic treatment [1,3].

Excessive reduction of the enamel can lead to hypersensitivity and irreversible damages of the dental pulp [2,6]. The approximal tooth surfaces are zones with active formation of plaque biofilm [9-11] due to stagnation under the interdental contact-points, which are difficult areas to self-cleanse

and brush. The plaque biofilm is also a factor in caries development [12-14].

Therefore, it is important to establish whether there is enamel damage on interdental surfaces before performing enamel reduction and whether there is further aggravation following enamel reduction. It has been accepted that enamel reduction should be performed on patients with very good oral hygiene and low caries risk [15-17]. It is commonly held that stripping of the lower incisors should not be more than 0.5 mm [18-21] of each approximal tooth surface [22]. It is very important to promote remineralisation of the enamel in order to guarantee the success of this technique [22-25].

The assessment of the degree of surface demineralisation, if any, and an examination of the status of the enamel after its partial removal are crucial [26-29]. Visual methods for determining the initial demineralisation and the remineralisation

Corresponding author: Dr. Panagiotis Kanoupakis, Department of Orthodontics, Faculty of Dental Medicine, 1431, St. Georgi Sofiiski Blvd, 1, Medical University, Sofia, Bulgaria; e-mail: panagiotis@abv.bg

after treatment are difficult to apply to approximal tooth surfaces. During the past years, instruments for this type of diagnosis have been developed and used mainly *in vitro*, based on different principles such as laser fluorescence devices QLF (quantitative light-induced fluorescence) [30,31] and DIAGNOdent [31-34], ultrasound ULS [35], and measurement of electrical conductivity ECM (electrical conductivity method) [33].

The DIAGNOdent pen (Kavo Dental GmbH, Biberach, Germany) has proved to be one of the most practical instruments for this purpose, as it includes an approximal flat-tip probe for detection of initial enamel demineralisation on approximal tooth surfaces [34-36].

Aim

The aim of this study was to assess the status of enamel approximal surfaces *in vivo* with the help of a laser fluorescence device, before and after enamel reduction, and its subsequent remineralisation.

Methods

A convenience sample of 53 patients (aged between 12 and 24 years) was collected out of 110 patients who had been treated orthodontically by postgraduate students over an 18-24-month period in the Department of Orthodontics, Faculty of Dental Medicine, Medical University of Sofia, Bulgaria.

The patients came from different regions of Bulgaria and, with their parents' consent where appropriate, agreed to participate in the study after receiving verbal and written information. Ethical permission to conduct the study was obtained from the Ethics Committee of the Medical University of Sofia. One calibrated orthodontist collected and performed all the measurements and readings.

Criteria for patients' selection included optimal alignment of anterior teeth during their orthodontic treatment with brackets and, also, no prior stripping procedures on these teeth. All patients had good oral hygiene with an average plaque score of 0.56 before enamel reduction.

The follow-up period for all patients who had been assessed with the DIAGNOdent pen was one month after enamel reduction. Twenty-seven patients were available nine months after enamel reduction and were assessed again after this period.

Assessment of enamel status

The diagnostic laser fluorescence (LF) measurements were carried out with a DIAGNOdent pen. The DIAGNOdent pen is a mobile laser device

caries detector allowing reading values from 0-99. The main unit generates laser light with a wavelength of $\lambda=655\text{nm}$, which is absorbed by both organic and inorganic tooth structure and re-emitted as fluorescence within the red and infrared region. The underlying mechanism is that demineralised tissue emits stronger fluorescence than intact tissue in the red and infrared part of the spectrum. Thus, the fluorescence from a demineralised region greater than that from intact tissue is expressed as a higher numerical read-out by the device.

Before using the DIAGNOdent pen, the enamel status of the upper and lower anterior teeth was determined visually. First, the device was calibrated using a ceramic standard, provided by the manufacturer. Its reference value (e.g., C58) was engraved into its upper surface. The measurements were performed after thorough drying with compressed air, and a reference value from intact buccal and accessible enamel surface. Polishing with professional toothpaste was avoided because it affects the fluorescence. Thereafter, the tapered tip was moved along the proximal surfaces, slightly tilted and rotated along its own axis to pick up the area where the demineralisation was most advanced. Three measurements were performed between the incisal edges of two adjacent teeth and papilla's peak. The measuring site was the location giving the highest recording, corresponding to the deepest part of the demineralised area.

For interpretation of the results, the diagnostic scale based on the examination of intact and altered enamel previously performed in Bulgaria [10,11] was used. It had involved the use of a clinical visual study, DIAGNOdent and the histologic validation of the results (*Table 1*).

Table 1. Diagnostic scale of carious lesions

DIAGNO-dent value	Histologic validation	Clinical diagnosis
0-3	No change	Intact enamel
4-6	Early changes on enamel surface	D1a
7-15	Changes in outer half of enamel	D1b
15-20	Changes up to enamel-dentine junction	D2
Above 21	Dentine caries	D3

The measurements for the qualitative assessment of enamel with the DIAGNOdent pen were performed before and immediately after enamel reduction, and then on the third and tenth days and one month after enamel reduction. For 27 patients, there was an additional measurement after nine months.

Performing enamel reduction

After carrying out the diagnostic measurements and planning the amount and location of the enamel reduction on casts, this procedure was performed clinically. If fixed appliances were present, the wire was removed from the brackets in order to gain access to the approximal surfaces. If necessary, rubber separators or open-coil springs were placed to create an opening between two adjacent teeth. If the teeth were not separated, a diamond-coated metal strip (Komet, Rock Hill, SC, USA) was used to make the initial reduction. The size of the interdental opening was equal to the thickness of the strip, which was between 0.08 mm with extra-fine grains (15 µm), 0.10 mm with medium-fine coat grains (30 µm), and 0.13 mm with the roughest grains (45 µm).

Then, with the help of a double-coated perforated diamond separator (Komet) with a diameter of 18 mm or 22 mm and diamond coat of 3 mm wide and 0.15 mm thick, a reduction of a minimal amount of enamel (0.10-0.25 mm) was made by moving it along the axis of two adjacent teeth. In teeth with triangular crown morphology, more enamel was removed from the incisal edge of the tooth and less from the middle and gingival thirds, whereas in oval-shaped teeth more was removed from the middle third, so that almost parallel approximal surfaces were achieved.

Initially, minimal enamel reduction was performed (range between 0.10-0.20 mm). An additional enamel reduction procedure was applied on 22 of the total 535 surfaces (up to 0.5 mm maximally) until final tooth alignment.

A diamond flame-shaped bur was used to polish and shape a final oval form to the entrance between the approximal surfaces and the labial and lingual surfaces.

The approximal surfaces were then polished with a Komet perforated or non-perforated diamond metal strip, with a rough, middle-fine, and fine polish paper band and polishing discs (Sof-Lex, 3M Espe, St Paul, MN, USA).

At every patient appointment, the amount of

enamel reduction at each of the six anterior teeth was assessed. This was measured with a mechanical thickness gauge which consisted of several lamellae of different thickness: 0.05 mm, 0.10 mm, 0.15 mm, 0.20 mm, 0.25 mm, 0.30 mm, 0.40 mm, 0.50 mm, 0.60 mm, 0.70 mm, 0.80 mm, 0.90 mm and 1 mm. It was perpendicular to the dental arch and with an angle of 90° towards the labial surfaces of two adjacent teeth. The gauge was inserted into the interdental space without resistance and without moving the two teeth apart.

After interdental enamel reduction and polishing, with the help of a brush or a cotton pad, fluoride-gel was applied to the dried stripped surfaces (Duraphat, Colgate, Pharbil Waltrop GmbH, Germany) (1 ml of the gel containing 50 mg NaF, which is equal to 22.6 mg fluoride) until there was a homogeneous layer on the tooth. Tooth surfaces turned yellow, which was helpful for control of the application. This gel can be applied to a tooth again after three months, except in cases where some hypersensitivity occurs on the tooth, in which case it can be applied two or three times a week [10,11]. In order not to remove the gel, patients were instructed not to consume hard food or drinks and not to brush their teeth for four to six hours after application. They were also recommended to brush their teeth with a desensitising toothpaste (Sensodyne; GlaxoSmithKline, Brentford, UK) with higher fluoride content (calcium fluoride and NaF, 1400ppm) for three months after enamel reduction.

Statistical methods

The resulting data were entered into statistical software (Statistical Package for Social Sciences, Windows Version 15.0; SPSS Inc, Chicago, USA). Fischer's exact test was used for statistical analysis of the research results and non-parametric McNemar's test for the categorised clinical scores. The level of significance was set to 5%. Excel Version 2003 (Microsoft Corporation, Redmond, WA, USA) was used for the graphic design.

Results

The initial measurements with the DIAGNOdent pen before enamel reduction were at a total of 535 surfaces; of these, 394 (73.6%) recorded values between 0 and 3, 127 (23.7%) values between 4 and 6, and only 14 surfaces had values between 7 and 15, which showed that only in limited cases (2.7%) were changes in the outer half of the enamel observed (*Table 2*). Results after enamel reduction

and final polishing of the treated dental surfaces are presented in *Table 2* and *Figure 1*.

There was a statistically insignificant decrease in the number of the dental surfaces with values between 0 and 3, falling from 394 to 384. During the investigation, only 10 out of 127 dental surfaces (7.9%) with values of 4 to 6 (early outer surface alteration) maintained the same value, whereas the other 117 dental surfaces (92.1%), with an initial value of 4 to 6, recorded values of intact enamel (0-3), which showed a statistical decrease of the cases with initial demineralisation.

It is important to note that 14 surfaces which showed values of DIAGNOdent 7-15 before enamel reduction (initial changes on the outer enamel layer) improved their status after the procedure, as nine surfaces registered values of 0 to 3 and the other five surfaces values of 4-6 (*Table 2*).

Three days after enamel reduction, 381 of 394 healthy enamel surfaces (value 0-3 before enamel

reduction) remained within this range but only 13 of them (3.3%) showed values 4-6 (i.e., initial changes of enamel), which may be explained by the deterioration of oral hygiene in these cases.

On the other hand, there was a significant reduction in the number of surfaces that showed values between 4 and 6 before enamel reduction; that is, a decrease from 127 to 118. Three days after enamel reduction, these already showed a normal reaction (0-3) and only in nine cases (7%) did the value remain at 4-6. It is of particular importance that out of 14 surfaces (2.7% of total surfaces) with initial changes in the outer enamel layer, three days after stripping 12 (85.7%) registered values of 0-3 and only two (14.3%) registered values between 4-6. On the day 3, damages in the outer half of the enamel (7-15 values) were not found in any of the three groups of surfaces.

The quality of the enamel was measured again ten days after enamel reduction. The data are pre-

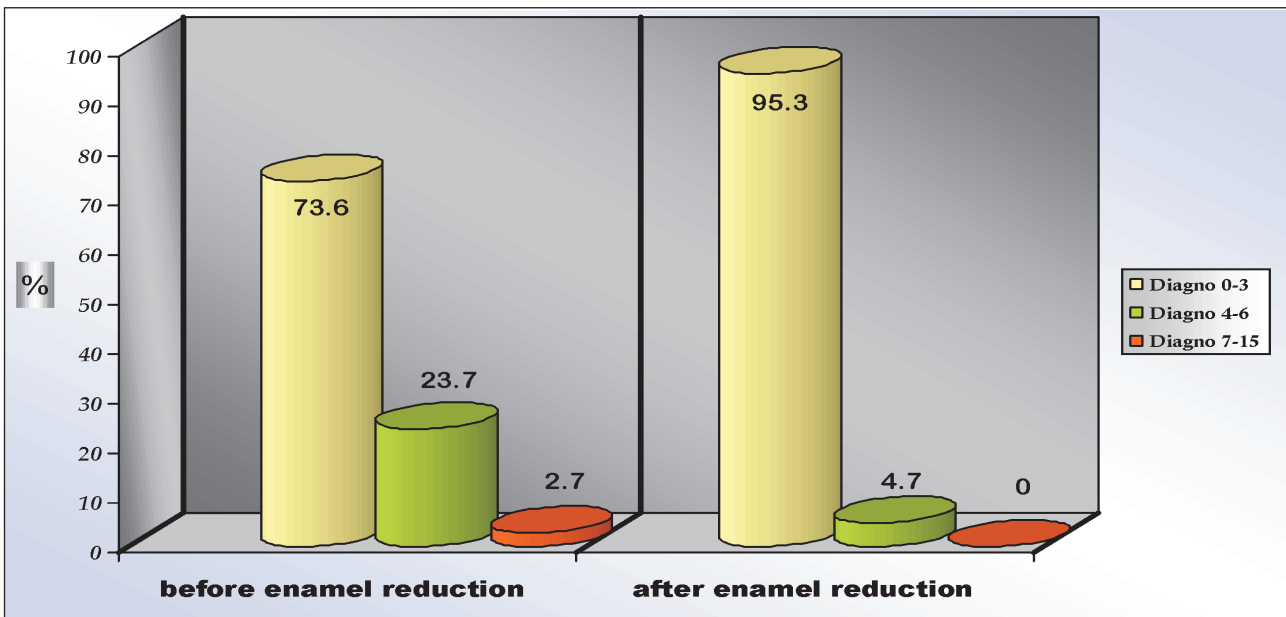


Figure 1. Percentage distribution of dental surfaces by DIAGNOdent values before and after enamel reduction.

Table 2. Comparison of DIAGNOdent values before and after enamel reduction

Time of measurement DIAGNOdent values	Before enamel reduction		After enamel reduction					
	Number surfaces	%	0-3	%	4-6	%	7-15	%
0-3	394	73.6%	384	97.5%	10	2.5%	0	0%
4-6	127*	23.7%	117	92.1%	10*	7.9%	0	0%
7-15	14**	2.7%	9	64.3%	5**	35.7%	0	0%
Total number surfaces	535	100%	510	95.3%	25	4.7%	0	0%

* Statistical significance $P < 0.05$; ** Statistical significance $P < 0.01$; *** Statistical significance $P < 0.001$

Table 3. Comparison of DIAGNOdent values before enamel reduction and 3 days later

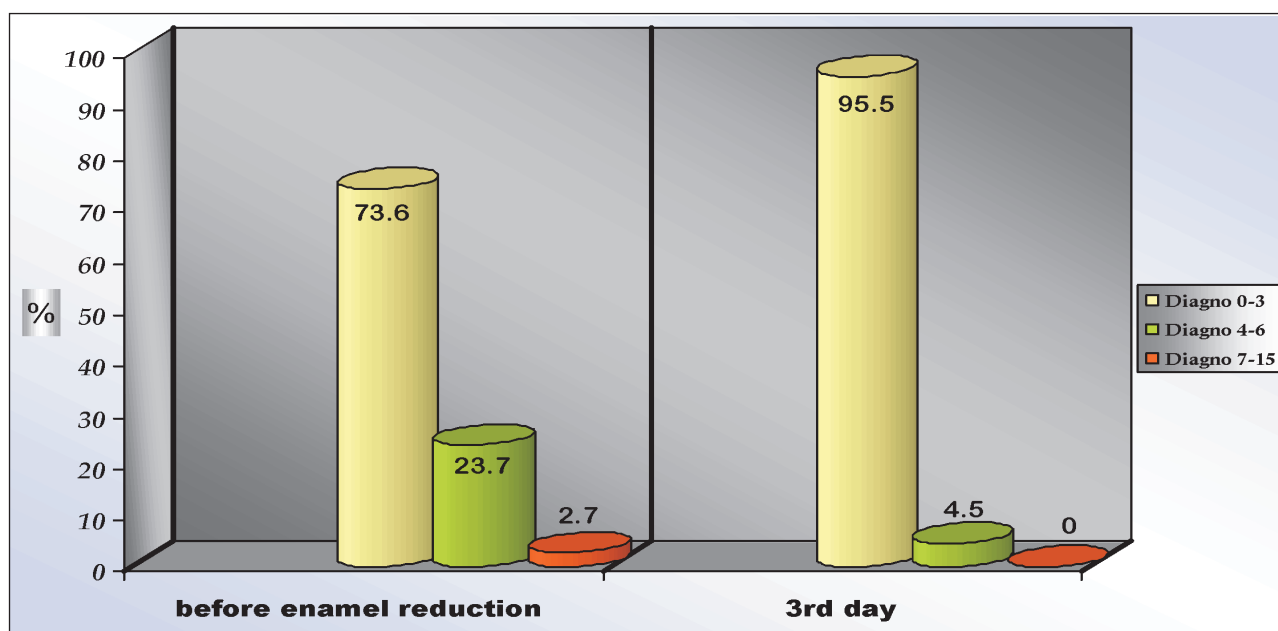
Time of measurement DIAGNOdent values	Before enamel reduction		3rd day					
	Number surfaces	%	0-3	%	4-6	%	7-15	%
0-3	394	73.6%	381	96.7%	13	3.3%	0	0%
4-6	127**	23.7%	118	92.9%	9**	7.1%	0	0%
7-15	14**	2.7%	12	85.7%	2	14.3%	0**	0%
Total number surfaces	535	100%	511	95.5%	24	4.5%	0	0%

* Statistical significance $P<0.05$; ** Statistical significance $P<0.01$; *** Statistical significance $P<0.001$

Table 4. Comparison of DIAGNOdent values before enamel reduction and 10 days later

Time of measurement DIAGNOdent values	Before enamel reduction		10th day					
	Number surfaces	%	0-3	%	4-6	%	7-15	%
0-3	394	73.6%	384	97.4%	10	2.6%	0	0%
4-6	127**	23.7%	121	95.3%	6**	4.7%	0	0%
7-15	14**	2.7%	12	85.7%	2	14.3%	0**	0%
Total number surfaces	535	100%	517	96.6%	18	3.4%	0	0%

* Statistical significance $P<0.05$; ** Statistical significance $P<0.01$; *** Statistical significance $P<0.001$

**Figure 2.** Percentage distribution of dental surfaces by DIAGNOdent values before enamel reduction and 3 days later.

sented in *Table 4* and *Figure 3*. The results showed a slight increase of surfaces which presented with values of 0-3 before enamel reduction compared with those recorded on day 3 (from 381 to 384) and normalised surfaces that showed initial demineralisation (4-6) from 118 to 121. Out of nine surfaces

with values 4-6 on the third day, three of them on the tenth day were observed to have values equal to intact enamel (0-3).

The comparison between the values of the surfaces before enamel reduction and one month after the procedure are at *Table 5* and *Figure 4*.

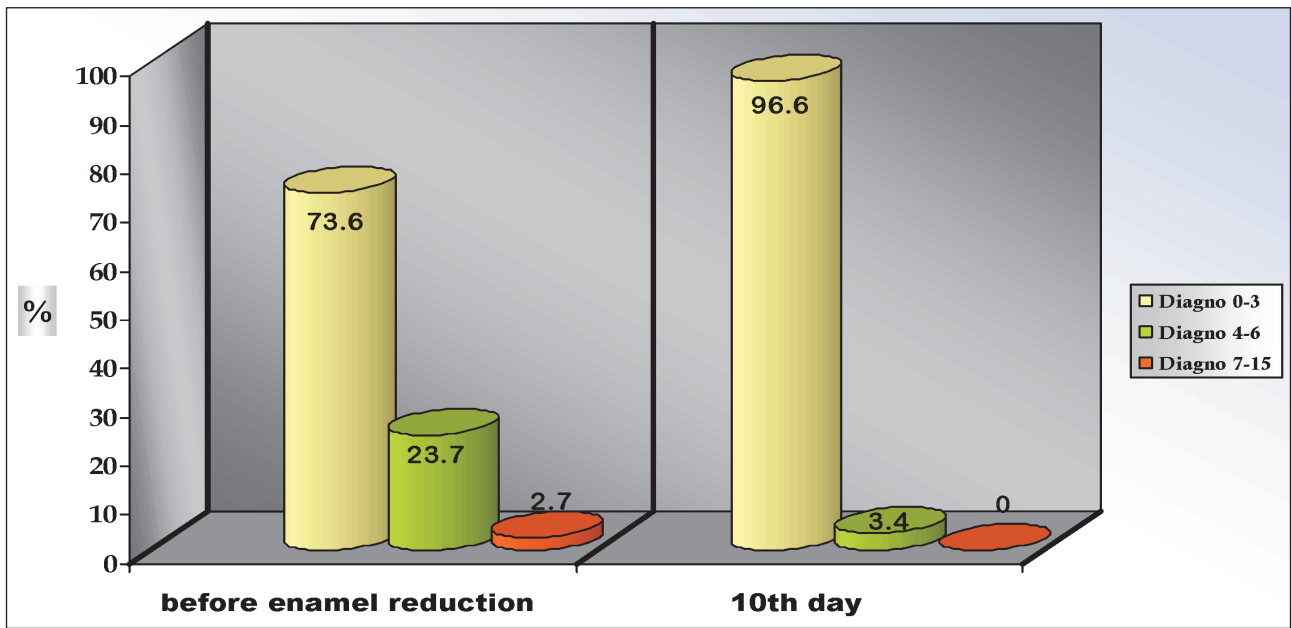


Figure 3. Percentage distribution of dental surfaces by DIAGNOdent values before enamel reduction and 10 days later.

Table 5. Comparison of DIAGNOdent values before enamel reduction and 1 month later

Time of measurement DIAGNOdent values	Before enamel reduction		1 month after enamel reduction					
	Number surfaces	%	0-3	%	4-6	%	7-15	%
0-3	394	73.6%	383	97.2%	11	2.8%	0	0%
4-6	127	23.7%	118	92.9%	9	7.1%	0	0%
7-15	14**	2.7%	11	78.6%	3	21.4%	0**	0%
Total number surfaces	535	100%	512	95.7%	23	4.3%	0	0%

* Statistical significance $P < 0.05$; ** Statistical significance $P < 0.01$; *** Statistical significance $P < 0.001$

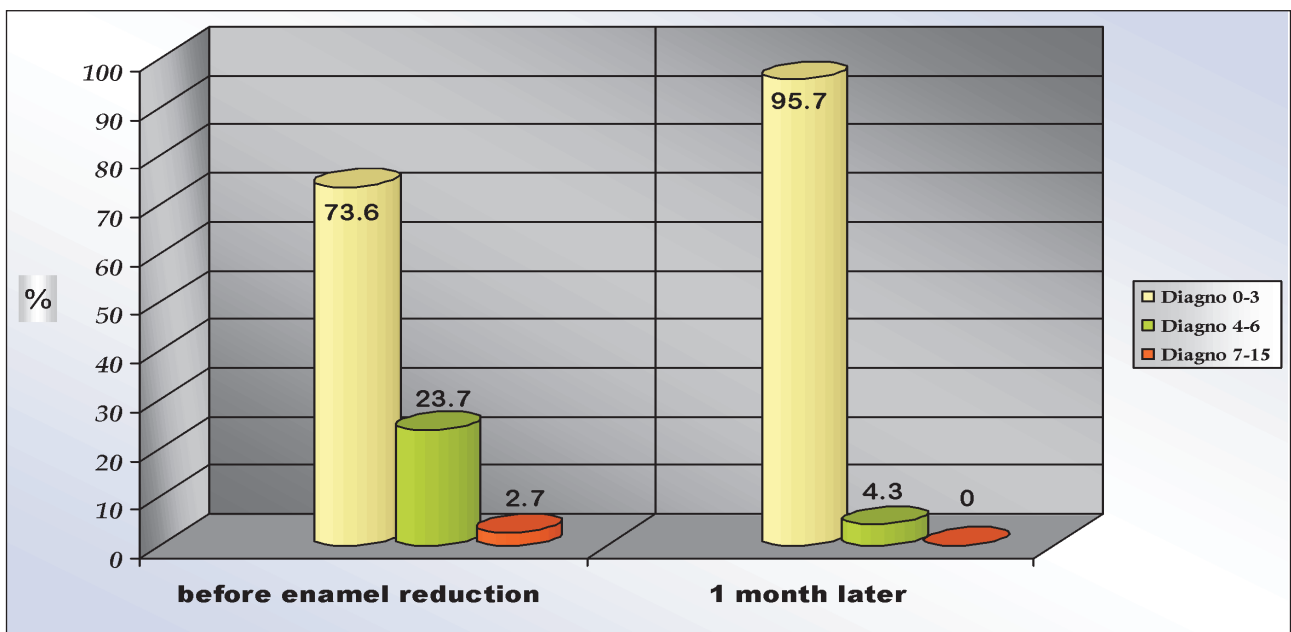


Figure 4. Percentage distribution of dental surfaces by DIAGNOdent values before enamel reduction and 1 month later.

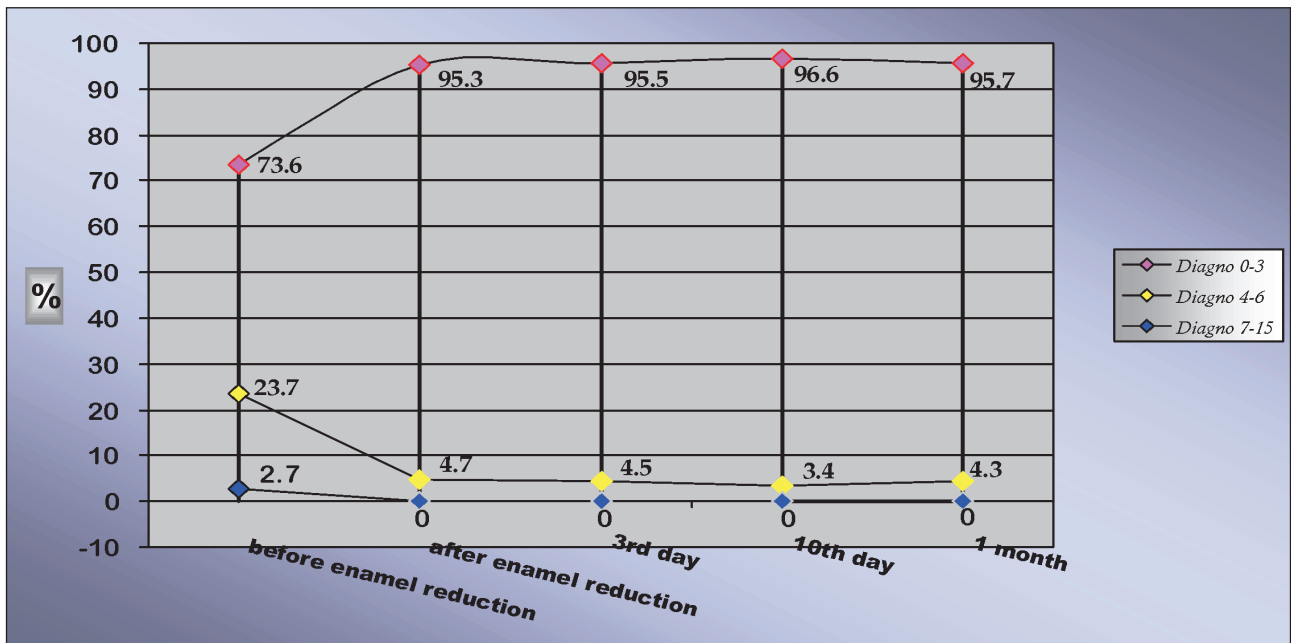


Figure 5. Percentage tracing of DIAGNOdent enamel status for 1 month after enamel reduction.

Table 6. Longitudinal 9-month follow-up of enamel changes after enamel reduction

Time of measurement DIAGNO values	Before enamel reduction	After enamel reduction	3rd day	10th day	1 month	9 months after enamel reduction
0-3	216	269	272	276	274	282
4-6	65	22	19	15	17	9
7-15	10	0	0	0	0	0
Total	291	291	291	291	291	291

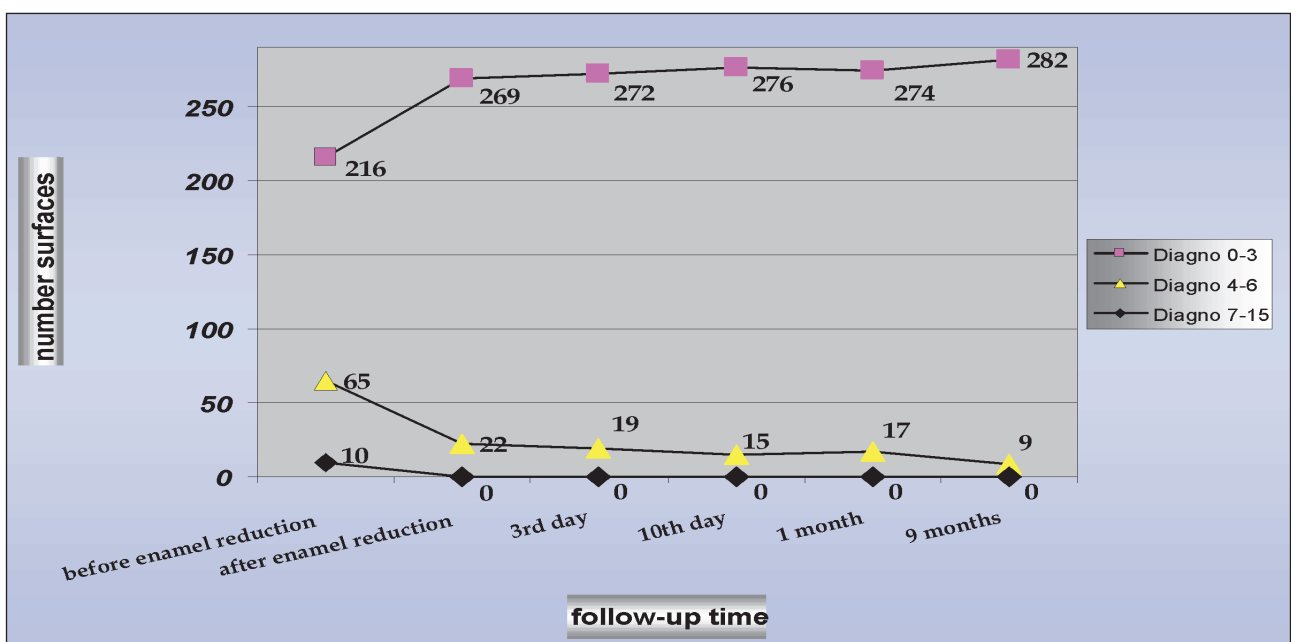


Figure 6. Longitudinal 9-month follow-up of enamel changes on 291 surfaces after enamel reduction.

Compared to the tenth day after enamel reduction, five previously intact surfaces were observed with values equal to initial enamel changes (4-6). This can be attributed to deterioration of oral hygiene in these patients.

A longitudinal nine-month follow-up study of the results was carried out. It included only 27 of the original sample of 53 patients. They were the patients who managed to come to the additional nine-month appointment. Two hundred and ninety-one stripped surfaces of a total 535 were observed. Data from these 27 patients are presented in *Table 6* and *Figure 6*.

After nine months, only nine enamel surfaces registered scores of 4-6. The rest all registered 0 to 3 (*Table 6* and *Figure 6*). Five of these nine surfaces originally registered 0-3. Of the 65 surfaces that originally registered values of 4-6, 61 gave values of 0-3 after nine months and only four surfaces remained at values of 4-6 (initial enamel change). All 10 surfaces that showed changes in the outer half of enamel (value 7-15) before initial measurements improved over the nine months and gave intact enamel (values 0-3), which may be explained by remineralising procedures and well-maintained oral hygiene by the patients.

Discussion

As far as the authors are aware, this was the first *in vivo* study that has been performed to investigate, with the help of a laser fluorescence device DIAGNOdent pen, the relationship between the qualitative changes of enamel after enamel reduction, and to evaluate the remineralisation process that occurs in enamel surfaces after enamel reduction has been performed.

Previous studies [31,34] have suggested that DIAGNOdent can be used for detecting caries and initial demineralisation on the occlusal or approximal tooth surfaces. Some of these studies [33,37] have been *in vitro* and none of them has assessed *in vivo* the quality of the enamel before and after enamel reduction. There are no previously published data or studies of approximal surfaces of anterior teeth with DIAGNOdent *in vivo* in order to evaluate enamel changes.

DIAGNOdent is known to be influenced by plaque and calculus, saliva bacteria and body temperature. Nevertheless, it is one of the most objective devices for qualitative enamel assessment. It was therefore used in the current study.

Clinically, working with the DIAGNOdent pen

and recording the values was quick and easy to perform and was well accepted by the patients. The study can be criticised for not dividing the results by gender and the simplistic visual methods that were used to diagnose initially intact or damaged enamel. Control groups were not used in this study because of the difficulty of having in a single mouth one side with stripped surfaces and one side without enamel reduction. It was unfortunate that not all patients could be followed up for the period of nine months. However, the resulting data have provided a promising indication of the effect of enamel reduction on intact or even initially damaged enamel when this procedure is performed.

Two studies [38,39] have shown that enamel reduction can increase the susceptibility of proximal enamel surfaces to demineralisation and lead to greater plaque retention and increased risk of secondary caries because of residual furrows on the enamel surface compared with non-treated enamel surfaces [2,40-45].

Results immediately after enamel reduction showed that in cases of initial reversible lesions in the outer enamel surface, enamel reduction removed the demineralised section of the enamel and although generally less-mineralised enamel remained on the surface, there remained a more mineralised area [46,47]. Therefore, in these cases it can be claimed that appropriately performed enamel reduction has a positive effect on enamel. On the third and tenth days after enamel reduction, there was a slight but not statistically significant increase in the number of surfaces that registered values (0-3) and a decrease in the number of surfaces showing initial enamel changes (4-6). Surfaces with values that equated to damage in the outer half of the enamel were not found. The follow-up study recordings taken after nine months showed that 282 of 291 surfaces with initial changes before enamel reduction could be considered as healthy after properly performed enamel reduction.

The study indicated that performing enamel reduction is appropriate for intact approximal tooth surfaces or even in those with initial enamel demineralisation. Enamel reduction can be successfully implemented in early carious lesions within the outer half of the enamel. Such lesions demand more intensive and periodical remineralisation by applying fluoride gel, if tooth sensitivity continues longer. Systematic oral hygiene checks were carried out after enamel reduction in order to motivate

and follow-up the oral hygiene in patients with stripped teeth. In a future study, it would be worthwhile to assess the connection between the oral hygiene and the remineralisation after enamel reduction, as well as its relation to tooth sensitivity.

Conclusions

The results of the current study indicate that:

- The DIAGNOdent pen can be used for the objective clinical assessment of the dental enamel status before and after performing interproximal enamel reduction.
- Most (95.3%) of the stripped surfaces registered DIAGNOdent values of 0-3 (as intact enamel) after interproximal enamel reduction.
- After reduction, surfaces with initial demineralisation registered values as intact enamel.
- Oral hygiene control and remineralisation procedures are needed to maintain the enamel status in a healthy range after interproximal enamel reduction

The results from this study demonstrate that

with correct diagnosis, as well as selection of intact or even slightly demineralised enamel surfaces, successful implementation of enamel reduction within enamel is possible. This technique, precisely planned, correctly executed and followed by remineralisation procedures, eliminates the risk of enamel demineralisation.

Acknowledgements

This study received support through Research Grant 2008 from the Medical University of Sofia.

Contribution of each author

- PMK performed the clinical examinations and measurements.
- MDP tested DIAGNOdent pen and modified a diagnostic scale for enamel histologic changes.
- PMK and VYM planned the study and wrote the paper.

Statement of conflict of interests

As far as the authors are aware, there is no conflict of interests.

References

1. Hudson AL. A study of the effects of mesiodistal reduction of mandibular anterior teeth. *American Journal of Orthodontics* 1956; **42**: 615-624
2. Joseph VP, Rossouw PE, Basson NJ. Orthodontic microabrasive reproximation. *American Journal of Orthodontics and Dentofacial Orthopedics* 1992; **102**: 351-359.
3. Rossouw PE, Tortorella A. A pilot investigation of enamel reduction procedures. *Journal of the Canadian Dental Association* 2003; **69**: 384-388.
4. Sheridan JJ. The updated air-rotor stripping (ARS) manual. New Orleans, LA: Raintree Essix; 1999.
5. Paskow H. Self-alignment following interproximal stripping. *American Journal of Orthodontics* 1970; **58**: 240-249
6. Pinheiro MLRM. Interproximal enamel reduction. *World Journal of Orthodontics* 2002; **3**: 223-232
7. Tuverson, DL. Anterior interocclusal relations part I. *American Journal of Orthodontics* 1980; **78**: 361-370
8. Zhong M, Jost-Brinkmann PG, Radlanski RJ, Miethke RR. SEM evaluation of a new technique for interdental stripping. *Journal of Clinical Orthodontics* 1999; **33**: 286-291.
9. Peneva M, Tzolova E, Kabakchieva R, Rashkova M. Prevention of oral disease. Ed. "East-West"; 2007. p. 232.
10. Peneva M. Crossing between operational and non-operational preventive treatment. Author's summary of dissertation, Sofia: 2008, p.64
11. Peneva. M. Dental decay in 21st century. Ed. "East-West"; 2008. p. 290.
12. Kapur KK, Fischer E, Manly RS. Effect of surface alteration on the permeability of enamel to a lactate buffer. *Journal of Dental Research* 1961; **40**: 1174-1182.
13. Sullivan HR. The solubility of enamel surfaces. *Journal of Dental Research* 1954; **33**: 504-510.
14. Wisth PJ, Nord A. Caries experience in orthodontically treated individuals. *The Angle Orthodontist* 1977; **47**: 59-64.
15. Jarjoura K, Gagnon G, Nieberg L. Caries risk after interproximal enamel reduction. *American Journal of Orthodontics and Dentofacial Orthopedics* 2006; **130**: 26-30.
16. Mizrahi E. Enamel demineralization following orthodontic treatment. *American Journal of Orthodontics* 1982; **82**: 62-67.
17. Radlanski RJ, Jager A, Schwestka R, Bertzbach F. Plaque accumulation caused by interdental stripping. *American Journal of Orthodontics and Dentofacial Orthopedics* 1988; **94**: 416-420.
18. Harris EF, Hicks JD. A radiographic assessment of enamel thickness in human maxillary incisors. *Archives of Oral Biology* 1998; **43**: 825-831.
19. Rogers GA, Wagner MJ. Protection of stripped enamel surfaces with topical fluoride applications. *American Journal of Orthodontics* 1969; **56**: 551-559.
20. Shillingbourg HT, Grace CS. Thickness of enamel and dentin. *Journal of South California Dental Association* 1993; **41**: 33-54
21. Stroud JL, English J, Buschang PH. Enamel thickness of the posterior dentition: its implication for nonextraction treatment. *The Angle Orthodontist* 1998; **68**: 141-146.
22. Sheridan JJ, Ledoux PM. Air-rotor stripping and proximal sealants—an SEM evaluation. *Journal of Clinical Orthodontics* 1989; **23**: 790-794

23. El-Mangoury NH, Moussa MM, Mostafa YA, Girgis AS. *In-vivo* remineralization after air-rotor stripping. *Journal of Clinical Orthodontics* 1991; **25**: 75-78.
24. Zachrisson BU. Fluoride application procedures in orthodontic practice, current concepts. *The Angle Orthodontist* 1975; **45**: 72-81.
25. Zahradnik RT. Modification by salivary pellicles of *in vitro* enamel remineralization. *Journal of Dental Research* 1979; **58**: 2066-2073.
26. Isaac, S., et al. Solubility rate and natural fluoride content of surface and subsurface enamel. *Journal of Dental Research* 1958; **37**: 254-263.
27. Twesme DA, Air-rotor stripping and enamel demineralization *in vitro*. *American Journal of Orthodontics and Dentofacial Orthopedics* 1994; **105**: 142-151.
28. Xue J, Li W, Swain MV. *In vitro* demineralization of human enamel natural and abraded surfaces: A micromechanical and SEM investigation. *Journal of Dentistry*; **37**: 264-272.
29. Zahradnik RT, Moreno EC, Burke EJ. Effect of salivary pellicle on enamel subsurface demineralization *in vitro*. *Journal of Dental Research* 1976; **55**: 664-670.
30. Bader JD, Shugars DA. A systematic review of the performance of a laser fluorescence device for detecting caries. *Journal of the American Dental Association* 2004; **135**: 1413-1426.
31. Hibst R, Paulus R, Lussi A. Detection of occlusal caries by laser fluorescence: Basic and clinical investigations. *Medical Laser Application* 2001; **16**: 205-213.
32. Andersson A, Skold-Larsson K, Petersson L, Twetman S. Measurement of enamel lesion regression with a laser fluorescence device (DIAGNOdent): a pilot study. *Orthodontics* 2004; **1**: 201-205.
33. Bamzahim M, Shi X-Q, Angmar-Mnsson B. Occlusal caries detection and quantification by DIAGNOdent and Electronic Caries monitor: *in vitro* comparison. *Acta Odontologica Scandinavica* 2002; **60**: 360-364.
34. Lussi A, Hibst R, Paulus R. DIAGNOdent: an optical method for caries detection, *Journal of Dental Research* 2004; **83** (Spec Iss): 80-83.
35. Tagtekin DA, Ozyoney G, Basseren M, Ando M, Hayran O, Alpar R, et al. Caries detection with DIAGNOdent and ultrasound. *Oral Surgery, Oral Medicine, Oral Pathology, Oral Radiology and Endodontology* 2008; **106**: 729-735.
36. Shi X-Q, Tranæus S, Angmar-Mnsson B. Validation of DIAGNOdent for quantification of smooth-surface caries: an *in vitro* study. *Acta Odontologica Scandinavica* 2001; **59**: 74-78.
37. Shi X-Q, Welander U, Angmar-Mnsson B. Occlusal caries detection with KaVo DIAGNOdent and radiography: An *in vitro* comparison. *Caries Research* 2000; **34**: 151-157.
38. Lucchese A, Porcu F, Dolci F. Effects of various stripping techniques on surface enamel. *Journal of Clinical Orthodontics* 2001; **35**: 691-695.
39. Piacentini C, Giuseppe S. A scanning electron microscopy comparison of enamel polishing methods after air-rotor stripping. *American Journal of Orthodontics and Dentofacial Orthopedics* 1996; **109**: 57-63.
40. Arman A, Cehrell SB, Ozel E, Arhun N, Cetinsahin A, Soyman M. Qualitative and quantitative evaluation of enamel after various stripping methods. *American Journal of Orthodontics and Dentofacial Orthopedics* 2006; **130**: e.7-e.14.
41. Crain G, Sheridan JJ. Susceptibility to caries and periodontal disease after air-rotor stripping. *Journal of Clinical Orthodontics* 1990; **24**: 84-85.
42. Mikulewicz M, Szymkowski J, Matthews-Bezozowska T. SEM and profilometric evaluation of enamel surface after air-rotor stripping—an *in vitro* study. *Acta of Bioengineering and Biomechanics* 2007; **9**: 11-17.
43. Radlanski RJ, Jager A, Zimmer B. Morphology of interdentially stripped enamel one year after treatment. *Journal of Clinical Orthodontics* 1989; **23**: 748-750
44. Zachrisson BU, Nyoygaard L, Mobarak K. Dental health assessed more than 10 years after interproximal enamel reduction of mandibular anterior teeth. *American Journal of Orthodontics and Dentofacial Orthopedics* 2007; **113**: 162-169.
45. Zachrisson BU. Actual damage to teeth and periodontal tissues with mesiodistal enamel reduction (“stripping”). *World Journal of Orthodontics* 2004; **5**: 178-183.
46. Kanoupakis P, Moutaftchiev V. Enamel changes after stripping and enamel remineralization (literature review). *Orthodontic Review* 2008; **10**: 17-20.
47. Kanoupakis P, Peneva M, Moutaftchiev V. Objective clinical assesment of remineralization after stripping with laser fluorescence (preliminary research). *Orthodontic Review* 2009; **11**: 6-13.