

Prinzmetal or Vasospastic Angina in a Young Woman: An Under-Diagnosed Pathology

Mingou JS¹, Dioum M², Ndiaye MB¹, Zabalawi A³, Delaunay R³, Payot L³, Ndao SCT¹, Aw F¹, Diack B⁴, Diao M¹, Kane A⁴ and Ba SA¹

¹Cardiology Department, Aristide Le Dantec Hospital University, Dakar, Senegal

²Cardiology Department, Fann Hospital University, Dakar, Senegal

³Cardiology Department, Yves Le Foll Hospital, Saint Brieuc, France

⁴Cardiology Department, Hoggy Hospital University, Dakar, Senegal

*Corresponding author: Dioum M, Cardiology Department, Fann Hospital University, Dakar, Senegal, Tel: +00221776551883; E-mail: momar.dioum@yahoo.fr

Received date: March 08, 2017; Accepted date: May 10, 2017; Published date: May 15, 2017

Copyright: © 2017 Mingou JS, et al. This is an open-access article distributed under the terms of the Creative Commons Attribution License, which permits unrestricted use, distribution, and reproduction in any medium, provided the original author and source are credited.

Abstract

Vasospastic angina is considered rare but its prevalence is probably underestimated, especially in the case of atheromatous coronary lesions. Its diagnosis remains important because of its poor prognosis and its therapeutic features. We report a clinical case illustrating the issue of vasospastic angina's diagnosis. Diagnostic ways such as coronary spasm challenge tests must be adapted to the evolution of the techniques and the use of coronary angiography nowadays, in particular the preferential use of the radial pathway especially in women with a smaller radial caliber compared to men.

Clinical Case

We report through this clinical observation the issue of the diagnosis of vasospastic angina or Prinzmetal's angina (VSA).

Mrs. GV, 41 years old, had as a cardiovascular risk factor an active smoking at the rate of 15 packs-year and a family history of coronary heart disease. She was admitted to the emergency department for a stable angina evolving for three weeks with episodes at rest.

Biology noted an elevation of ultra-sensitive troponins to 220 ng/l. The electrocardiogram was normal, echocardiography noted moderate hypokinesis of left ventricle contractility in apical anterior, apex and anterior territories.

The coronary angiography performed by right radial artery access with a 5 french catheter concluded to intermediate coronary lesions at 50% in the distal part of the left main coronary artery (LMCA), encompassing the origin of the left circumflex artery (LCA) and left anterior descending artery or LAD (Classification Medina 1-0-0), and a lesion of 50% in the distal portion of the middle right coronary artery or RCA (Figures 1 and 2).

The measurement of the coronary reserve by Fractional Flow Reserve [FFR] towards the three axes was respectively 0.82 to the LAD, 0.83 to the circumflex artery and 0.92 to the right coronary artery.

Drug therapy including beta-blockers, aspirin, clopidogrel, statins and a nitroglycerin transdermal patch was initiated. The patient was advised on the need for good control of cardiovascular risk factors, specially smoking cessation.

Three days later, she presented a new recurrence of identical chest pain that occurred at rest for 10 minutes, leading her back to the emergency room.

At rest, the electrocardiogram showed electrical modifications like repolarization disorders of biphasic T-type in V1 and V2 precordial

leads; getting normal on the following electrocardiograms. Troponins were increased to 327 ng/l.

The control coronary angiography performed again by the right radial artery access without injection of vasodilator, did not find an evaluative lesion. The methylergometrine testing was positive with the reappearance of chest pain, T-wave negativity in V1 lead (Figure 3) and spastic occlusion of the proximal LAD (Figure 4), regressive after intra-coronary injection of 3 milligrams of isosorbide dinitrate (Figures 5 and 6).

Discussion

VSA is considered rare in Europe (1 to 1.5% of patients treated for angina) [1,2] and in the United States where it is on the National Institute of Health list of rare diseases.

Its prevalence would be much higher in Japan and ethnic or genetic factors were mentioned to explain this particularity [3].

The pathophysiological mechanisms are complex. It corresponds to acute transmural myocardial ischemia through transient occlusion of an epicardial vessel due to severe spasm (reduction of 80% of the arterial caliber). The origin of the spasm is still unclear, several phenomena are possible (endothelial dysfunction, platelet aggregation, minor vasoconstriction, segmental hyperactivity, alterations of atherosclerotic plaques), and currently hyper stimulation of parasympathetic activity is suggested [4].

Coronary spasm is a common cause of acute coronary syndrome. The prevalence of VSA in a known coronary patient is probably underestimated. Bertrand et al. [5] found a coronary spasm in 13.8% of patients with mixed angina, more often encountered in our practice, while Hamilton et al. emphasized that in 1999, only six tests of ergonovine provocations were carried out for 1,240 coronary explorations [6]. Lanza et al. reported a diagnosis delay of more than six months in more than 30% of the cases in 2007, in a prospective

series of 202 patients with VSA, and concluded that its diagnosis was too frequently neglected with a risk of cardiac events [2].

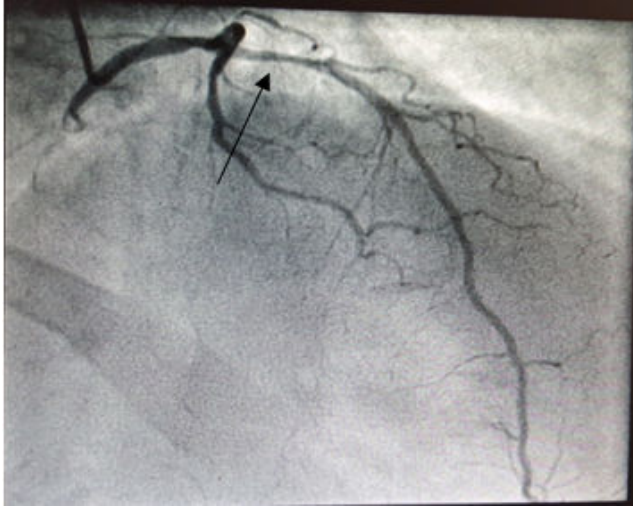


Figure 1: Intermediate lesion of the distal left anterior descending (LAD) artery.

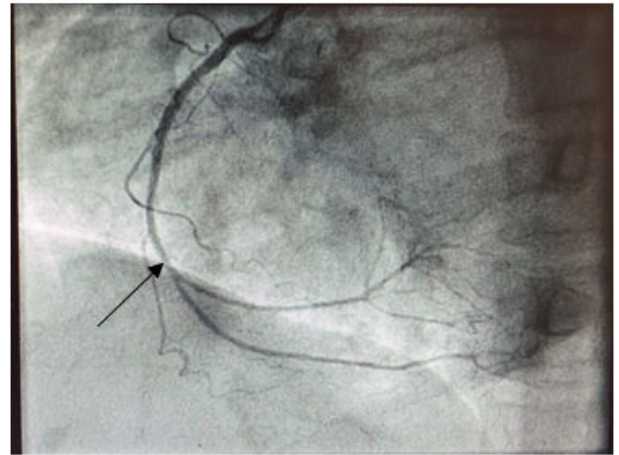


Figure 2: Intermediate lesion of the middle right coronary artery (RCA).

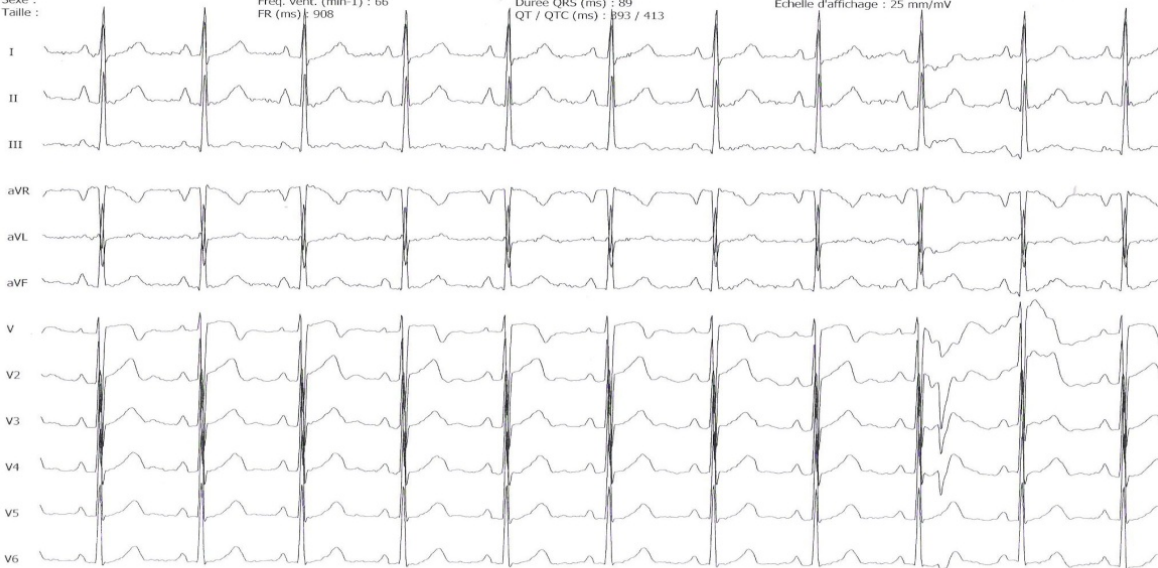
GRESSIER, VIRGINIE
02/05/2016 11:49:52
QS

Age :
Sexe :
Taille :

Poids :
Fréq. vent. (min-1) : 66
FR (ms) : 908

P-R (ms) : 183
Durée QRS (ms) : 89
QT / QTC (ms) : 393 / 413

Vitesse d'affichage : 25 mm/s
Echelle d'affichage : 25 mm/mV



Mac-Lab v6.5
GE Medical Systems

Figure 3: Electrical modifications of the T waves to the type of negativity in V1 three minutes after intravenous injection of methylergometrine.

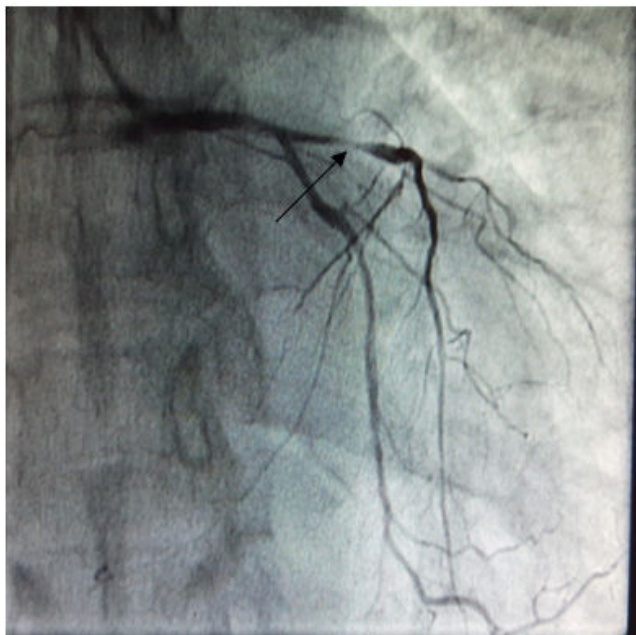


Figure 4: Subocclusion lesion of the left anterior descending artery after intravenous injection of isosorbide dinitrate.

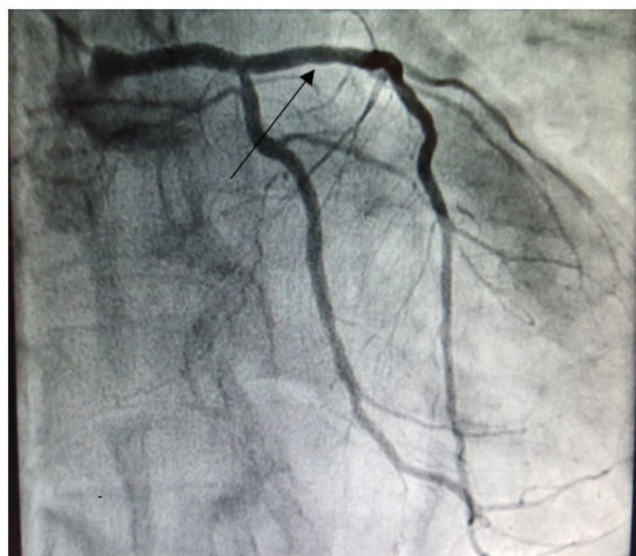

Figure 5: Raising the spasm after intra-coronary injection of 3 milligrams of isosorbide dinitrate. The diagnosis of Prinzmetal angina was selected.

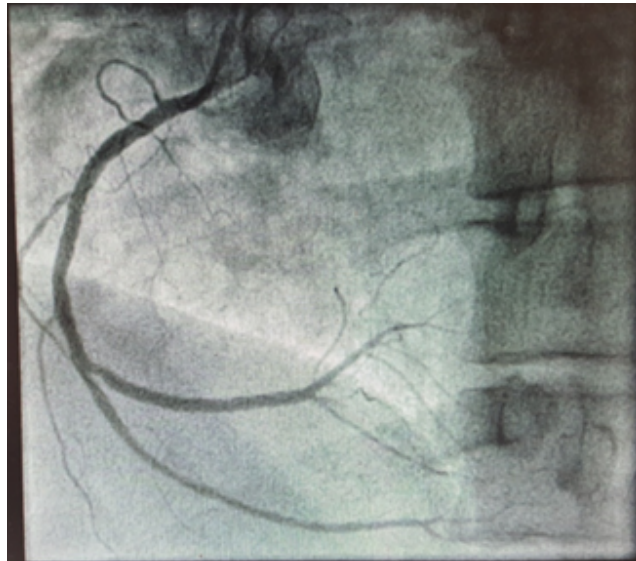


Figure 6: The beta-blocker treatment was stopped in favor of a calcium antagonist with anti-spastic aim associated with a nitrated derivate with a good clinical evolution.

Angiographic tests [7] have the advantage of documenting the physiopathological mechanism of VSA with a presentation comparable to spontaneous episodes [8] and to perform an intra-coronary injection of nitrated derivatives, allowing rapid treatment of the coronary spasm.

However, there is no clear correlation between the electrocardiographic signs observed and the angiographic data. The only angiographic differential diagnosis is the mechanical spasm at the end of the probe. The vasodilators have proved their effectiveness; they improve the prognosis in the short and long term. The refractory spasm in this patient was lifted by intra-coronary injection of vasodilators during the examination.

In 2011, the number of provocation tests of coronary artery spasm, all done by the femoral route, remains comparable or so 1.2% of coronary angiographies with 93% radial access. The preponderant use of that one is not the explanation of the rarity of these tests in our practices but contributes to it and poses several problems. The first explanation is the use of verapamil injected into the radial artery to prevent radial spasm while the use is to suspend the vasodilator treatments (calcium channel blockers and nitrated derivatives) 48 hours before the tests. However, we use a low dose of verapamil (2.5 mg) and its effect is local with little systemic effect [9]. The second explanation is the risk of radial spasm occurring in 5-13% of the diagnostic or interventional procedures despite the use of vasodilators injected into the radial artery [10], even more so in women who have a caliber of the radial artery of smaller size compared to men.

In our case, we preferred not to inject a vasodilator into the radial artery as not to distort the test.

Lee et al. [11] reported a series of 174 provocation tests by ergonovine intra-coronary by radial artery access with a 5 French catheter without the use of vasodilator.

The ergonovine was injected at the dose of 10 then 20 micrograms (depending on the response) in the left coronary main artery and 10 micrograms (possibly renewed) in the right coronary artery. A procedural failure was found only in 4% of cases (six patients), by radial spasm in three patients and without severe cardiac event. These results with in particular only 2% severe spasm and the safety of this protocol must be confirmed [11].

The European guidelines recommend the use of ergonovine intracoronary without precision as to the protocol to be followed and with only one criterion of positivity (angiographic) [12]. The publication of Lablanche et al. for the GACI (Groupe Athérome coronaire et cardiologie interventionnelle=Group coronary atheroma and interventional cardiology) had the great merit of reintroducing the spasm provocation tests in our diagnostic arsenal, after a stoppage due to several serious complications in ergonovine tests reported in the literature, with a defined protocol [4].

The treatment of VSA is primarily medical. Smoking cessation is the basic hygiene-dietary measure in the case of an associated atheromatous disorder but also because of its effect causing or favoring spasm, with smoking being an independent predictive factor of spasm during the test [13]. Calcium channel blockers are the first-line drug therapy for vasospastic by their relaxing effect on arterial and antispastic smooth muscle cells. They improve survival [14] and their prescription is a recommendation, both European and Japanese, class I.

The most commonly used calcium channel blockers are verapamil (240-480 mg/day) diltiazem (120-360 mg/day) with a variable individual effect leading to a change of molecule in the event of failure. However, resistance to calcium channel blockers is frequent [15], which may require the combination of nitrate derivatives or equivalents.

The place of revascularization by surgery or angioplasty is limited. A revascularization by angioplasty has been reported by several authors [16-19], not regulating the problem of endothelial dysfunction but having a mechanical action limiting spasm in the case of an authenticated culprit segment. The results on small numbers show a recurrence of VSA in other segments in 10 to 30% of the cases to which is added an equivalent rate of restenosis.

Coronary angioplasty can therefore have a place in the vasospastic angina's treatment but it is limited to patients with symptoms refractory to a maximum medical treatment and with a localized spasm.

As instable angina, the prognosis of VSA is indeed related to the importance of the atheromatous lesions associated with, for Walling et al. [14], a five-year survival of 95% of patients with one-vessel coronary artery disease and 77% of patients with multi-vessel coronary artery disease. This reinforces the value of the coronary angiographic evaluation of these patients during which a provoked spasm test could be performed.

Conclusion

Vasospastic angina or Prinzmetal's angina is a rare presentation of angina in young women and most often is under diagnosed.

Spasm provocation tests are ways of diagnosing vasospastic angina and assessing its prognosis.

Improved diagnostic management of vasospastic angina would allow a specific adaptation of the treatment of these patients according to the current recommendations, and to improve their prognosis.

References

1. Crea F, Lanza GA (2011) New light on a forgotten disease: vasospastic angina. *J Am Coll Cardiol* 58: 1238-1240.
2. Lanza GA, Sestito A, Sgueglia GA, Infusino F, Manolfi M, et al. (2007) Current clinical features, diagnostic assessment and prognostic determinants of patients with variant angina. *Int J Cardiol* 118: 41-47.
3. Beltrame JF, Sasayama S, Maseri A (1999) Racial heterogeneity in coronary artery vasomotor reactivity: differences between Japanese and caucasian patients. *J Am Coll Cardiol* 6: 1442-1452.
4. Vandergoten P, Benit E, Dendale P (1999) Prinzmetal's variant angina: three case reports and a review of the literature. *Acta Cardiol* 54: 71-76.
5. Bertrand ME, LaBlanche JM, Tilmant PY, Thieuleux FA, Delforge MR, et al. (1982) Frequency of provoked coronary arterial spasm in 1089 consecutive patients undergoing coronary arteriography. *Circulation* 65: 1299-1306.
6. Hamilton KK, Pepine CJ (2000) A renaissance of provocative testing for coronary spasm? *J Am Coll Cardiol* 35: 1857-1859.
7. Song JK, Lee SJ, Kang DH, Cheong SS, Hong MK, et al. (1996) Ergonovine echocardiography as a screening test for diagnosis of vasospastic angina before coronary angiography. *J Am Coll Cardiol* 27: 1156-1161.
8. Curry RC Jr, Pepine CJ, Sabom MB, Conti CR (1979) Similarities of ergonovine-induced and spontaneous attacks of variant angina. *Circulation* 59: 307-312.
9. Feng L, Fitzsimmons BF, Young WL, Berman MF, Lin E, et al. (2002) Intraarterially administered verapamil as adjunct therapy for cerebral vasospasm: safety and 2-year experience. *AJNR Am J Neuroradiol* 23: 1284-1290.
10. Varenne O, Salengro E, Cohen R (2010) How to prevent and manage radial artery spasm during coronary interventions. *Trans-radial approach for cardiovascular interventions. ESMeditations* 28: 361-370
11. Lee KJ, Lee SH, Hong KP, Park JE, Seo JD, et al. (2005) Feasibility and safety of the transradial approach for the intracoronary spasm provocation test. *Catheter Cardiovasc Interv* 65: 240-246.
12. Fox K, Garcia MA, Ardissino D, Buszman P, Camici PG, et al. (2006) The Task Force on the management of stable angina pectoris of the European Society of Cardiology. Guidelines on the management of stable angina pectoris. *Eur Heart J* 27: 1341-1381.
13. Harding MB, Leithe ME, Mark DB, Nelson CL, Harrison JK, et al. (1992) Ergonovine maleate testing during cardiac catheterization: a 10-year perspective in 3,447 patients without significant coronary artery disease or Prinzmetal's variant angina. *J Am Coll Cardiol* 20: 107-111.
14. Walling A, Waters DD, Miller DD, Roy D, Pelletier GB, et al. (1987) Long-term prognosis of patients with variant angina. *Circulation* 76: 990-997.
15. Sueda S, Kohno H, Fukuda H, Watanabe K, Ochi N, et al. (2003) Limitations of medical therapy in patients with pure coronary spastic angina. *Chest* 123: 380-386.
16. Hajloui N, Tarragano F, Raisky P (2010) Angor spastique réfractaire au traitement médical traité par angioplastie avec mise en place d'un stent. À propos d'un cas et revue de la littérature. *Ann Cardiol Angeiol* 59: 103-106.
17. Gaspardone A, Tomai F, Versaci F (1999) Coronary artery stent placement in patients with variant angina refractory to medical treatment. *Am J Cardiol* 84: 96-98.
18. Khatri S, Webb JG, Carere RG, Dodek A (2002) Stenting for coronary artery spasm. *Catheter Cardiovasc Interv* 56: 16-20.
19. Sussman EJ, Goldberg S, Poll DS (1981) Surgical therapy of variant angina associated with nonobstructive coronary disease. *Ann Intern Med* 94: 771-774.