

Pattern of Origin of Anterior Inferior Cerebellar Artery in a Black Kenyan Population

Julius A Ogeng'o*, Musa Misiani, Beda O Olabu and Martin I Inyimili

Department of Human Anatomy, University of Nairobi, Nairobi, Kenya

*Corresponding author: Julius Ogeng'o, Department of Human Anatomy, University of Nairobi, Kenya, Tel: +254720837592; E-mail: jogengo@uonbi.ac.ke

Rec date: Jul 10, 2014; Acc date: Aug 31, 2014; Pub date: Sep 02, 2014

Copyright: © 2014 Ogeng'o JA, et al. This is an open-access article distributed under the terms of the Creative Commons Attribution License, which permits unrestricted use, distribution, and reproduction in any medium, provided the original author and source are credited.

Abstract

Background: Pattern of origin of anterior inferior artery is important in interpretation of posterior circulatory stroke and during posterior cranial fossa surgery for aneurysms, arteriovenous malformations, tumors, posterior cerebral revascularization, and in diagnostic as well as interventional neuroradiology. The pattern displays ethnic variation but data from African populations are scanty. This study therefore aimed to describe the pattern of origin of anterior cerebellar artery in a black Kenyan population.

Materials and Methods: One hundred and seventy three [99 male: 74 female] basilar arteries from adult formalin fixed brains were studied at Department of Human Anatomy, University of Nairobi, Kenya. Site and pattern of origin of anterior inferior cerebellar arteries were recorded. Data were analyzed by SPSS version 17.0 for Windows, and presented in a table and macrographs.

Results: Anterior inferior cerebellar artery arose directly from basilar artery in 138 (79.8%), as common trunk with labyrinthine artery in 24 (13.9%), from vertebral and labyrinthine arteries in 3% cases each.

Conclusion: In about 14% cases, anterior inferior cerebellar and labyrinthine arteries arise as common trunks from basilar artery. These proportions differ with those in prevailing literature from Caucasian and oriental populations. Extra care should therefore be exercised during surgery and neuroradiology in the posterior cranial fossa, and in interpretation of signs of posterior circulation stroke. Pre-operative ultrasound evaluation of the vascular bed is recommended.

Keywords: Anterior inferior cerebellar artery; Origin; African

Introduction

Anterior inferior cerebellar artery (AICA) usually arises from the caudal third of the basilar artery and supplies the inner ear, facial and vestibulocochlea nerves, lateral pons, middle cerebellar peduncle and anterior cerebellum [1-3]. Several variations in origin have been described [4,5]. Knowledge of these variations is important in interpreting features of its occlusion which comprise a broad spectrum of signs and symptoms of audiovestibular dysfunction, facial weakness, facial sensory loss, Hornes's syndrome, limb and gait ataxia [3,6-8]. Pattern of origin of AICA is also important to minimize risks of inadvertent damage during surgery in the posterior cranial fossa for aneurysms, arteriovenous malformations, tumors, epilepsy surgery, posterior temporal lobectomies and posterior cerebral revascularization [9-11]. This is because of its intimate relationship with trigeminal nerve and acoustic - facial complex at the cerebellopontine angle [5,10]. Further, it is essential during diagnostic and interventional neuroradiology for avoiding incorrect diagnosis, explaining unusual presentation of posterior circulatory stroke, possible implications of surgery and interventional procedures [12,13]. The patterns of origin display ethnic variations [14]. Data from black populations are, however, scanty and absent altogether for the Kenyan one. This study therefore investigated the pattern of origin of the AICA in a black Kenyan population.

Materials and Methods

One hundred and seventy three (99 male, 74 female; age range 20-79 years) basilar arteries from adult formalin-fixed brains were examined at the Department of Human Anatomy, University of Nairobi, Kenya. Arachnoid mater was gently peeled off the base of brain to expose the vertebrobasilar arterial system. The Anterior inferior cerebellar artery was identified as that which coursed posterolaterally ventral to abducent, facial and vestibulocochlea nerves to the anteroinferior surface of the lateral aspect of cerebellum. Arteries were defined as common trunks if their branches were of almost equal diameter on macroscopic examination. Where one branch was smaller, the larger one was considered the parent. Their site and pattern of origin were then recorded. Photographs of representative patterns were taken using a high resolution digital camera. Respective origins of the arteries were coded and entered the statistical programme for Social Scientists version 17.0 for windows. The data were analysed for frequencies. Student t-test was used to calculate statistical difference between left and right and between male and female at 95% confidence interval where p value of ≤ 0.05 was taken to be significant.

Results

This artery arose directly from basilar artery in 138 (79.8%) of cases (Figure 1A). In the remaining cases, it arose from a common trunk with labyrinthine artery (Figure 1B) in 24 (13.9%), vertebral artery

(Figure 1C) in 6 (3.4%) and labyrinthine artery (Figure 1B) in 5(2.9%) cases (Table 1).

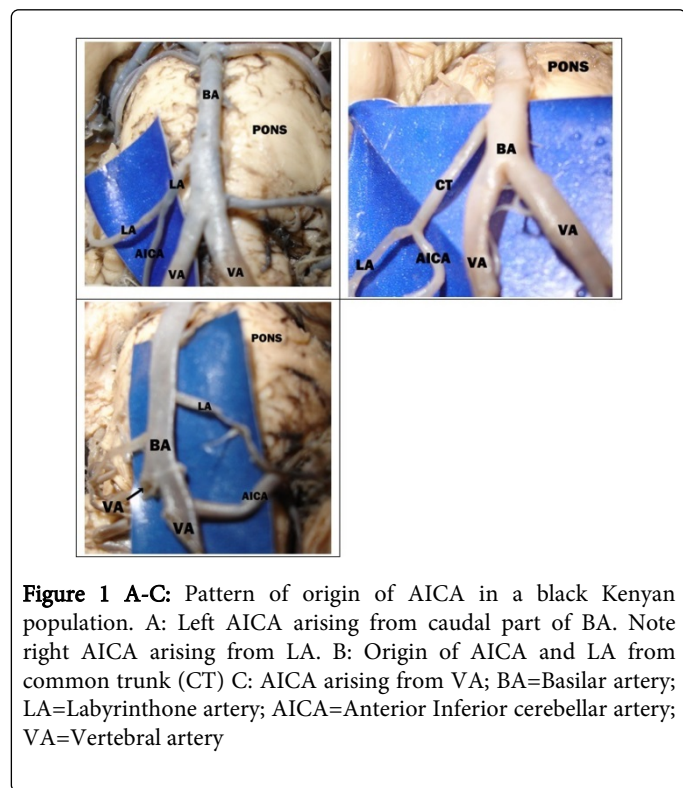


Figure 1 A-C: Pattern of origin of AICA in a black Kenyan population. A: Left AICA arising from caudal part of BA. Note right AICA arising from LA. B: Origin of AICA and LA from common trunk (CT) C: AICA arising from VA; BA=Basilar artery; LA=Labyrinthine artery; AICA=Anterior Inferior cerebellar artery; VA=Vertebral artery

Origin	Frequency	(%)
Basilar artery	138	(79.8)
Common trunk with LA	24	(13.9)
Vertebral artery	06	(3.4)
Labyrinthine artery	05	(2.9)
Total	173	(100)

LA=Labyrinthine artery

Table 1: pattern of origin of AICA in a black Kenyan population

Discussion

The AICA usually arises from the basilar artery as a single trunk, [15,16]. Observations of the current study reveal that it arose directly from the basilar artery in only 79.8% of the cases. This is lower than 98.1% among Koreans [17] and 100% among Germans [1], but higher than 56% in a Japanese population [18] (Table 2).

Although these variations may be due to methodology, they also suggest population variations. The predominant origin of AICA from the BA is consistent with reports that the most common mechanism of AICA infarction is formation of atheroma or thrombus in the BA blocking the orifice of AICA [19]. This implies that as BA atherosclerosis gains prominence in developing countries of Africa, for example, AICA infarction will also increase.

A remarkable finding of the present study is the high proportion (13.9%) of common trunk with LA and 2.9% origin from LA. These

findings are important in interpretation of effects of occlusion of AICA or LA. Occlusion of AICA may result in brainstem, cerebellar and neurological deficits characterized by vertigo, nausea, vomiting, facial paralysis, ipsilateral deafness, sensorimotor deficits, cerebellar ataxia, nystagmus, Horner's syndrome, hemisensory loss of pain and temperature [8,19,20]. They are also important in management of the aneurysms. For example, ruptured distal aneurysm poses marked neurological risks [21].

Author	Population	Mode of origin (%)				
		Basilar	Vertebra l	SCA	Common AICA - LA trunk	LA
Kim et al. [17]	Korean	98.1	1.9	-	-	-
Inui et al. [18]	Japanese	56	-	-	-	-
Paeneczky [1]	German	100	-	-	-	-
Current study, 2011	Kenyan	79.8	3.4	-	13.9	2.9

Table 2: Pattern of origin of AICA in various populations

The AICA arose from vertebral artery in 3.4% of cases. This is only scarcely reported [4,22]. In these cases, stenosis, hypoplasia or dissection of VA may cause AICA territory infarction/syndrome [23]. Accordingly, for the black Kenyan population, VA hypoplasia or atherosclerosis should be considered a differential diagnosis in cases of AICA syndrome. Pertinent to this suggestion is the observation that the main cause of AICA stroke is either BA or VA atherosclerotic disease [19].

These diverse patterns of origin support existence of population variations [24,25], and are important in the presentation of AICA aneurysm [26] and infarcts [21,27]. Further, surgeons and intervention neuroradiologists need to be aware of this diversity in sites of origin for AICA as they plan approach to posterior cranial fossa, cerebellopontine angle and while performing gasserian ganglion blocks [13].

Conclusion

Anterior inferior cerebellar artery arises as common trunks with labyrinthine arteries in over 13% and from vertebral artery in 3.4% and labyrinthine artery in 2.9% cases. These patterns differ with those in prevailing literature from Caucasian and oriental populations. Extra care should therefore be exercised during surgery in the posterior cranial fossa, and interpretation of signs of posterior circulation stroke. Pre-operative ultrasound, CT angiography evaluation of the vascular bed is recommended.

Acknowledgements

We are grateful to Mr. Acleus Murunga and Jacob Gimongo for collecting samples, Ms Catherine Chinga and Antonina Odock – Opiko for typing the manuscript.

References

1. Perneczky A (1981) Anterior inferior cerebellar artery. Anatomy, clinical aspects and micro-neurosurgery. *Fort schr med* 99: 511 – 514.
2. Amarenco P, Hauw JJ (1990) Cerebellar infarction in the territory of the anterior and inferior cerebellar artery. A clinicopathological study of 20 cases. *Brain* 113 : 139-155.
3. Amarenco P, Rosengart A, DeWitt LD, Pessin MS, Caplan LR (1993) Anterior inferior cerebellar artery territory infarcts. Mechanisms and clinical features. *Arch Neurol* 50: 154-161.
4. Takahashi M, Wilson G, Hanafee W (1968) The anterior inferior cerebellar artery: Its radiographic anatomy and significance in the diagnosis of extra-axial tumors of the posterior fossa. *Radiology* 90: 281-287.
5. Habibi Z, Meybodi AT, Maleki F, Tabatabai AF (2011) Superior and anterior inferior cerebellar arteries and their relationship with cerebellopontine angle cranial nerves revisited in the light of cranial cephalometric indexes: A cadaveric study. *Turkish neurosurgery* 21: 504-515.
6. Lee H, Sohn SI, Jung DK, Cho YW, Lim JG, et al. (2002) Sudden deafness and anterior inferior cerebellar artery infarction. *Stroke* 33: 2807-2812.
7. Son EJ, Bang JH, Kang JG (2007) Anterior inferior cerebellar artery infarction presenting with sudden hearing loss and vertigo. *Laryngoscope* 117: 556-558.
8. Lee H, Kim JS, Chung EJ, Yi HA, Chung IS, et al. (2009) Infarction in the territory of anterior inferior cerebellar artery: spectrum of audiovestibular loss. *Stroke* 40: 3745-3751.
9. Uchino A, Sawada A, Takase Y, Kudo S (2003) Variations of the superior cerebellar artery. *MR angiographic demonstration* 21: 235-238.
10. Pai BS, Varma RG, Kulkarni RN, Nirmala S, Manjnath LC, et al. (2007) Microsurgical anatomy of the posterior circulation. *Neurol India* 55: 31-41.
11. Zador Z, Lu DC, Arnold CM, Lawton MT (2010) Deep bypasses to the distal posterior circulation: anatomical and clinical comparison of pretemporal and subtemporal approaches. *Neurosurgery* 66: 92-100.
12. Bulsara KR, Zomorodi A, Provensale JM (2007) Anatomic variant of the posterior cerebral artery. *Am J Roentgen* 188: W395-W395.
13. Bykowski J, Jahan R, Pakbaz RS (2011) Variant carotid origin of left anterior inferior cerebellar artery mimicking infarct on angiography. *J Neurointerv Surg* 3: 279-281.
14. Gillilan LA (1972) Anatomy and Embryology of the arterial system of the brain stem and cerebellum. In: *Handbook of clinical Neurology* eds Vinken IJ, Bryn G. vol 2 North Holland; Amsterdam.
15. Rhoton Al Jr. (2000) The Cerebellar Arteries *Neurosurgery* 47: S29-S68.
16. Padmavathi G (2000) Study of basilar artery in Human cadavers. MD thesis, Rajiv Gandhi University.
17. Kim HN, Kim YH, Park IY, Kim GR, Chung IH (1990) Variability of the surgical anatomy of the neurovascular complex of the cerebellopontine angle. *Ann Otol Rhinol Laryngol* 99: 288-296.
18. Inui H, Kikuoka M, Fujita N, Yoshii I (1992) Three dimensional analysis of arteriography in human posterior circulation (Preliminary report). *Nippon Jubinkoka Gakkai Kaiho* 95: 1206-1215.
19. Kumral E, Kisabay A, Atac C (2006) Lesion patterns and etiology of ischaemia in the anterior inferior cerebellar artery territory involvement: a clinical-diffuse weighted – MRI study. *Eur J Neurol* 13: 395-401.
20. Peluso JP, Van Rooij WJ, Sluzewski M, Beute GN (2007) Distal aneurysms of cerebellar arteries: Incidence, clinical presentation, and outcome of endovascular parent occlusion. *Am J Neuroradiol* 28: 1573-1578.
21. Santillan A, Gobin YP, Petsalides A, Riina HA, Rosengart A, et al. (2011) Endovascular management of distal anterior inferior cerebellar artery aneurysms: Report of two cases and review of literature. *Surg Neurol Int* 2: 95-98.
22. Von MitterWallner F (1955) Variations statische untersuchungen an den basalen Hirngefassen. *Acta anat* 24: 51-57.
23. Kuronuma Y, Suzuki R, Inoue Y, Miyashita F, Toyoda K (2013) Anterior inferior cerebellar artery territorial infarction caused by vertebral artery dissection. *Cerebrovasc Dis* 35: 592.
24. Sugita M, Masutani H, Moriguchi M, Matsunaga K, Nakai Y (1991) Distribution of arteries from brain stem to inner ear around internal auditory canal. *Acta Oto-Laryngologica* 111: 42-52.
25. Scoleri P, Widner SA, Cass SP (2001) An anatomic variant of the anterior inferior cerebellar artery in a patient with Ménière's disease. *Otol Neurotol* 22: 519-525.
26. Kamiya K, Nagai H, Koide K, Yamashita N, Shimazu N (1994) Peripheral anterior inferior cerebellar artery aneurysms. *Surg Neurol* 42: 46-51.
27. Requer J, Lorenzo JL, Pou A (1998) The anterior inferior cerebellar artery infarcts: a clinical magnetic resonance imaging study. *Acta Neurologica scandinavica* 97: 225-230.