

Osteomyelitis of the Pubic Symphysis as a Complication of Bladder Neck Suspension Procedure with Use of Bone Anchors: A Case Report

Tomoaki Koakutsu^{1*}, Masanori Kawamura², Ko Takada³ and Eiji Itoi¹

¹Department of Orthopaedic Surgery, Tohoku University Hospital, Sendai, Japan

²Department of Orthopedic surgery, Iwate Prefectural Central Hospital, Morioka, Japan

³Department Urology, Iwate Prefectural Central Hospital, Morioka, Japan

Abstract

Bladder neck suspension procedure using bone anchors in the pubic bone is employed as the standard treatment for stress urinary incontinence. A 76-year-old woman who had an osteomyelitis of the pubic symphysis following this procedure is presented. She complained of lower abdomen, suprapubic, and left groin pain after she had received an operation for urinary incontinence. The pain persisted and gradually led to gait disturbance. Hematology showed mild inflammation, plain radiograph and computed tomography of the pelvis revealed osteomyelitis of the pubic symphysis and retropubic abscess. Bone anchors and the attached suture material were removed, necrotic bone was curetted. After the surgery, her pain decreased and urinary incontinence remained improved. Osteomyelitis of the pubic bone is uncommon entity that must be recognized in elderly women who received an operation for stress urinary incontinence.

Keywords: Osteomyelitis; Pubic bone; Stress urinary incontinence

Introduction

Osteomyelitis of the pubic bone is a rarely described entity [1,2]. Most cases are preceded by urological or gynecological surgery [2,3]. Bladder neck suspension procedure using bone anchors in the pubic bone is a commonly performed procedure for the treatment of stress urinary incontinence which is the most common form of urinary incontinence in women [4-6]. As this procedure is a transvaginal surgery, it has been reported to be less invasive and causes a lower incidence of complications, and it is employed as the standard treatment. We report on a case that had a osteomyelitis of the pubic symphysis after this procedure successfully treated operatively.

Case Report

A 76-year-old woman with a history of stress urinary incontinence had received an operation at the other hospital. She complained of lower abdomen, suprapubic, and left groin pain 1 month after the surgery. The pain persisted and gradually led to gait disturbance, she was seen at our hospital 3 years after the surgery.

She showed antalgic gait, and her pain caused unstable one-foot standing. Physical examination revealed tenderness over the pubic symphysis. The range of motion of the bilateral hip joints was normal. Hematology showed White Blood Cell (WBC) count of 9,650/ μ l, C Reactive Protein (CRP) level of 1.14 mg/dl, and Erythrocyte Sedimentation Rates (ESR) of 44 mm/1 hour and 77 mm/2 hours, suggesting mild inflammation. General urinalysis showed normal findings.

Anteroposterior plain radiograph of the pubis demonstrated 2 bone screws in place, bone sclerosis and irregularity of the margins of the pubic bone (Figure 1). Contrast enhancement Computed Tomography (CT) of the pelvis showed that a mass only whose margin was enhanced, was adjacent to the anterior wall of the bladder (Figure 2a). At the pubic symphysis, bone destruction was observed (Figure 2b). A diagnosis of osteomyelitis of the pubic symphysis with retropubic abscess was made.

She was admitted to our hospital and received operation. The operation was jointly performed by orthopaedic surgeons and urologists. In the supine position, the pubic symphysis and the Rezius' prevesical cavity were exposed via an anterior approach. The bone anchors were fixed only loosely to the necrotic bone. Bone biopsies

were performed, and the samples were sent for culture and pathological analysis. The bone anchors and the attached suture material were removed. The necrotic bone was curetted to sound bleeding bone with care not to destroy the ligamentous complex. Soft tissue debridement

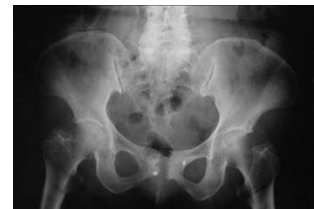

Figure 1: Anteroposterior plain radiograph of the pubis demonstrated 2 bone screws in place, bone sclerosis and irregularity of the margins of the pubic bone.

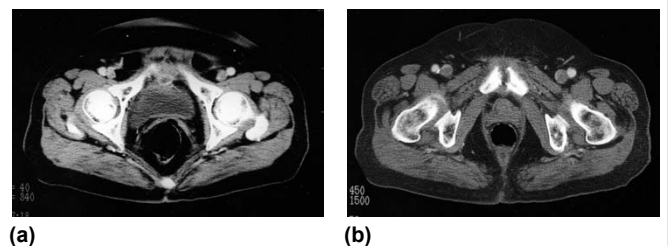


Figure 2: Contrast enhancement computerized tomography of the pelvis demonstrated retropubic abscess (a) and bone destruction at the pubic symphysis (b).

*Corresponding author: Tomoaki Koakutsu, Department of Orthopaedic Surgery, Tohoku University Hospital, 1-1 Seiryomachi, Aoba-ku, Sendai 980-8574, Japan, Tel: +81-22-717-7245; Fax: +81-22-717-7248; E-mail: koakutsu@med.tohoku.ac.jp

Received March 04, 2013; Accepted May 21, 2013; Published May 31, 2013

Citation: Koakutsu T, Kawamura M, Takada K, Itoi E (2013) Osteomyelitis of the Pubic Symphysis as a Complication of Bladder Neck Suspension Procedure with Use of Bone Anchors: A Case Report. *Rheumatol Curr Res* S16: 002. doi:10.4172/2161-1149.S16-002

Copyright: © 2013 Koakutsu T, et al. This is an open-access article distributed under the terms of the Creative Commons Attribution License, which permits unrestricted use, distribution, and reproduction in any medium, provided the original author and source are credited.

and irrigation were performed, and the wound was closed using a drain tube.

Pathological findings revealed bone tissues including the sequestrum, and granulation with outgrowth of fibrous connective tissues. In the stoma, infiltration of inflammatory cells, including lymphocytes and plasma cells, was observed (Figure 3). These findings were compatible with chronic osteomyelitis. *Staphylococcus epidermidis* grew on culture of the pubic symphysis obtained from open biopsy specimens, suggesting that it was the responsible pathogen.

After the surgery, she was treated with antibiotics. At the time of discharge, her pain decreased. At the 5-years follow-up observation, she was doing well and had no symptoms. Hematology did not show recurrent inflammation. Radiographs showed no further erosion of bone (Figure 4). Urinary incontinence remained improved over the original postoperative condition.

Discussion

Osteomyelitis of the pubic bone is a rarely described entity. It accounts for less than 1% of all cases of hematogenous osteomyelitis [1]. The etiologies of pubic osteomyelitis include hematogenous, traumatic, and iatrogenic (after urological or gynecological surgery) factors, and the influence of other adjacent infection foci (e.g., prostate abscess). Rothenthal et al. reported that 27 out of 28 patients with pubic osteomyelitis developed this disorder following a major gynecological or urological surgical procedure; and in 24 out of these 27 patients, technical complications (wound infection or disruption, or a bladder perforation) were observed [2]. In our patient, according to the operative report and discussion with her previous doctor, there were no intraoperative complications or signs of postoperative infection.

In the department of urology, the bladder neck suspension procedure using bone anchors in the pubic bone is a commonly performed procedure for stress urinary incontinence which is the

most common form of urinary incontinence in women [4-6]. As this procedure is transvaginal surgery and the bone anchors can also be established percutaneously, this procedure has been reported to be less invasive and causes a lower incidence of complications than usual laparotomy. Postoperative complications are reported to include urinary retention, suprapubic pain, erosion and infection of sutures [7-11]. In the literatures of describing the treatment results in a large number of patients, the development of pubic osteomyelitis is rarely reported. This disorder is considered to be a rare complication. Benderev and Sirls et al. employed the bladder neck suspension using bone anchors in the pubic bone in more than 150 patients and in 102 patients, respectively; and reported that none of the patients developed pubic osteomyelitis [4,6]. Leach and Appell performed this procedure in 125 patients, and removal of the bone anchor was required owing to infection in only 1 patient, and the other 1 patient required drainage of a pelvic abscess related to suprapubic catheter placement, but the development of osteomyelitis is unclear [5]. Goldberg et al. reported that the estimated incidence of osteomyelitis after bone anchored bladder neck suspension was 1.3% (3 patients out of 225 patients) [10].

Matkov et al. assumed that infection in their case might be due to a lapse in sterile technique, since the wound was infected with skin flora [8]. Enzler et al. assumed that this procedure may increase the risk of osteomyelitis as the screw-suture complex passes through the vaginal lumen before being anchored into the bone [7]. Graham et al. reported 9 cases of pubic osteomyelitis following bladder neck surgery using bone anchors, and in 8 cases the bone anchors were placed by a vaginal route [11]. In this procedure, as artificial materials remain in the body, strict adherence to sterile technique, preoperative wound brushing, intravaginal scrubbing, and preoperative/postoperative administration of antibiotics might be important to prevent osteomyelitis.

Since many of the patients with stress urinary incontinence are elderly people, the numbers of patients undergoing this procedure will increase as elderly population increases. Osteomyelitis of the pubic bone should be recognized in elderly women who received an operation for urinary incontinence.

Conflict of Interest

No funding was received for this work and the authors have no conflict of interest to declare.

References

1. del Busto R, Quinn EL, Fisher EJ, Madhavan T (1982) Osteomyelitis of the the pubis. Report of seven cases. *JAMA* 248: 1498-1500.
2. Rosenthal RE, Spickard WA, Markham RD, Rhamy RK (1982) Osteomyelitis of the symphysis pubis: A separate disease from osteitis pubis. Report of three cases and review of the literature. *J Bone Joint Surg Am* 64: 123-128.
3. Burns JR, Gregory JG (1977) Osteomyelitis of the pubic symphysis after urologic surgery. *J Urol* 118: 803-805.
4. Benderev TV (1994) A modified percutaneous outpatient bladder neck suspension system. *J Urol* 152: 2316-2320.
5. Leach GE, Appell R (1996) Percutaneous bladder neck suspension. *Urol Clin North Am* 23: 511-516.
6. Sirls LT, Keoleian CM, Korman HJ, Kirkemo AK (1995) The effect of study methodology on reported success rates of the modified Pereyra bladder neck suspension. *J Urol* 154: 1732-1735.
7. Enzler M, Agins HJ, Kogan M, Kudurna J, Sand P, et al. (1999) Osteomyelitis of the pubis following suspension of the neck of the bladder with use of bone anchors. A report of four cases. *J Bone Joint Surg Am* 81: 1736-1740.
8. Matkov TG, Hejna MJ, Coogan CL (1998) Osteomyelitis as a complication of vesica percutaneous bladder neck suspension. *J Urol*. 160: 1427.
9. Bihrlle W 3rd, Tarantino AF (1990) Complication of retropubic bladder neck suspension. *Urology* 35: 213-214.

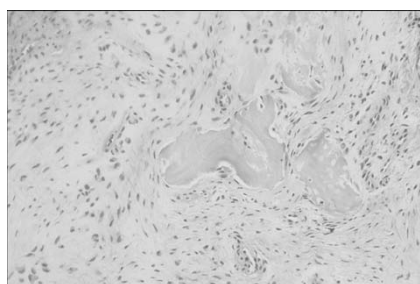


Figure 3: Histopathological findings on open biopsy of the pubic bone (hematoxylin and eosin, x40).

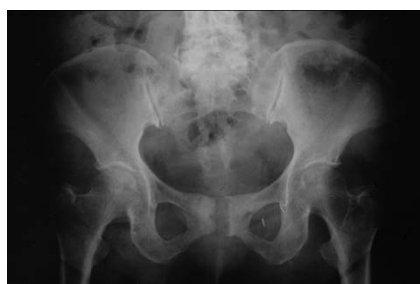

Figure 4 Anteroposterior plain radiograph of the pelvis at the 5-years follow-up observation showed no further erosion of bone.

-
10. Goldberg RP, Tchetgen MB, Sand PK, Koduri S, Rackley R, et al. (2004) Incidence of pubic osteomyelitis after bladder neck suspension using bone anchors. *Urology* 63: 704-708.
11. Graham CW, Dmochowski RR, Faerber GJ, Clemens JQ, Westney OL (2002) Pubic osteomyelitis following bladder neck surgery using bone anchors: a report of 9 cases. *J Urol* 168: 2055-2057.

This article was originally published in a special issue, **Orthopedics and Rheumatology: Case Reports** handled by Editor. Dr. Evan Silverio Vista, St. Luke's Medical Center and College of Medicine Manila, Philippines