

Obstructed Hemivagina and Ipsilateral Renal Agenesis with Uterus Didelphys: A Case of Neonatal Diagnosis

Fatma Trabelsi*, Habib Bouthour, Samer Bustame, Asma Jabloun, Ahlem Bezzine, Rabiaa Ben Abdallah and Nejib Kaabar

Department of Pediatric Surgery, Habib Thameur Hospital, Tunis El Manar University, Tunisia

Abstract

The syndrome of obstructed hemivagina and ipsilateral renal anomaly is known as Herlyn-Werner-Wunderlich syndrome or more recently, by the acronym OHVIRA. This congenital anomaly is rare. We report a case of a new born admitted because of intrauterine retardation and after explorations, she diagnosed to have OHVIRA syndrome. She underwent endoscopic resection.

Keywords: Neonatal; Hemivagina; OHVIRA syndrome; Pregnancy

Introduction

The syndrome of obstructed hemivagina and ipsilateral renal anomaly is known as Herlyn-Werner-Wunderlich syndrome or more recently, by the acronym OHVIRA. It consists of defective lateral fusion of the caudal portions of the müllerian ducts during weeks 8 to 12 of pregnancy and also includes abnormalities linked to non-absorption of the septum at 20th weeks of gestation. Unilateral renal agenesis occurs when one or both ureteral buds fail to form or degenerate, and the metanephric blastema therefore does not differentiate into nephrons [1]. This congenital anomaly is rare. It could present with lower abdominal pain, severe dysmenorrhea, a pelvic or vaginal mass, abnormal vaginal discharge, acute retention of urine, fever or vomiting. The particularity of our observation that is was fortunately diagnosed in a newborn. We report our new case and we also review the literature on OHVIRA syndrome.

Case Report

A one day old female newborn was admitted to neonatal care unit because of intra uterine growth retardation.

Her mother had unfavorable socio economic conditions. She had good follow up with gynecologist in the hospital. Pregnancy was uneventful and prenatal ultrasound showed no abnormalities. The child was born vaginally without incident. Neonatal examination showed very low birth weight with facial dysmorphism. The rest of the exam was normal. The patient underwent biological and radiological examination for intrauterine growth retardation.

Transabdominal ultrasound showed uterus malformation with two hemi matrices, retention in the left hemivagina and agenesis of the left kidney. The magnetic resonance imaging had confirmed the malformation. It showed two hemiuterus, two uterus cervix and two hemivagina. The right hemivagina was blind making a rounded mass of fluid signal extended of 14 × 17 mm (Figures 1). There were no abnormalities of the left hemivagina. The right kidney was agenetic. The child was operated at the age of three month. She had a vaginal endoscopy showing the presence of permeable vagina with a normal uterus cervix. There was a bulge in the right side wall of the vagina (Figure 2). We are realized the resection of the side wall allowing the evacuation of a clear liquid. There are so two hemivagina with two uterus cervix. The right hemivagina was blind and now it is drained into the left hemivagina (Figure 3). We are completed by a urinary endoscopy showing the presence of one left ureteral meatus. The evolution was

favorable. Patient was discharged after one day post-operative. The ultrasound realized after three month showed no abnormalities.

Discussion

OHVIRA is a rare congenital anomaly constituting 10% of all Mullerian duct abnormalities. The incidence of uterus didelphys, related to OHVIRA, is approximately 1/ 2000 to 1/ 28000, and it is accompanied by unilateral renal agenesis in 43% of cases [2]. The pathogenesis of OHVIRA syndrome has been related to embryologic arrest during 8th week of gestation that ultimately affects the Mullerian and metanephric ducts [3]. Generally, the paramesonephric ducts appear at 44-48 days of gestation as longitudinal invaginations of the surface epithelium along the mesonephric ridge lateral to mesonephric ducts [4]. An early failure of the metanephric diverticulum to develop

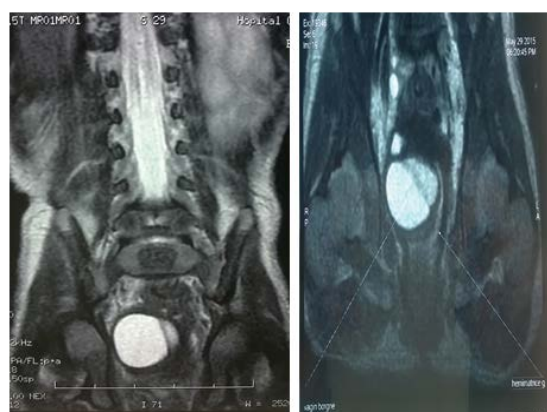

Figure 1: Magnetic resonance image showing hyperintense fluid collection in the right uterine cavity.

*Corresponding author: Fatma Trabelsi, Department of Gynecology and Obstetrics, Ez-Zitouna University, Tunis, Tunisia, Tel: +21622466833; Fax: +21671135000; E-mail: fattoum_t@live.fr

Received April 06, 2016; Accepted May 12, 2016; Published May 19, 2016

Citation: Trabelsi F, Bouthour H, Bustame S, Jabloun A, Bezzine A, et al. (2016) Obstructed Hemivagina and Ipsilateral Renal Agenesis with Uterus Didelphys: A Case of Neonatal Diagnosis. Gynecol Obstet (Sunnyvale) 6: 377. doi:10.4172/2161-0932.1000377

Copyright: © 2016 Trabelsi F, et al. This is an open-access article distributed under the terms of the Creative Commons Attribution License, which permits unrestricted use, distribution, and reproduction in any medium, provided the original author and source are credited.

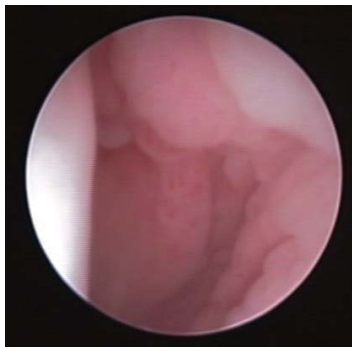


Figure 2: Bulge in the right side wall of the vagina shown by endoscopy.

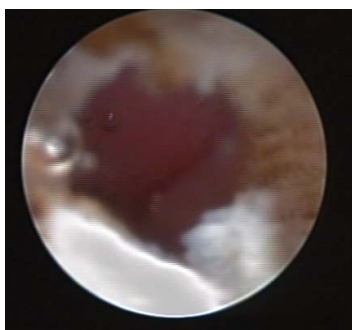

Figure 3: The right wall of the vagina after section.

(at 5 weeks) from the mesonephric duct results in agenesis of the ureteric bud, which leads to agenesis of the ipsilateral ureter and kidney [5].

Patients with a double uterus with OHVIRA can generally be categorized into three diagnostic groups: group 1 patients having complete unilateral vaginal obstruction without uterine communication; Group 2 patients having an incomplete unilateral vaginal obstruction without uterine communication; and group 3 patients having complete vaginal obstruction with a laterally communicating double uterus [6]. Our case belongs to group 1.

Renal agenesis is the most common anomaly seen in OHVIRA syndrome, but there have been case reports of cystic renal dysplasia, duplication of the collecting system, and ectopic ureters. Most often, as well as in this case, the renal anomalies are located on the right side. If a patient has renal agenesis, there is >50% chance, that they will also have a Mullerian anomaly. Therefore, it is important to examine the entire urogenital system when urinary anomaly is present [3-7].

The most common symptom associated with OHVIRA syndrome includes cyclical pelvic pain that starts shortly after beginning menarche and is associated with dysmenorrhea. This pain is due to the buildup of hematocolpos from retained menstrual blood in the obstructed vagina [8]. OHVIRA may present as abnormal vaginal discharge, infertility, vomiting, and fever. In some reported cases, symptomatology consisted on urinary retention which was the consequence of the compression of the urinary bladder by the hydrocolpos in the obstructed hemivagina. Rarely, it may be diagnosed in the prenatal and newborn period due to renal agenesis or muco- or hydrocolpos [9].

In our case, the diagnosis was made fortunately thanks to pelvic ultrasonography realized to explore intra uterine growth retardation in a new born.

When OHVIRA syndrome is suspected, the first exploration realized is pelvic ultrasonography. It is a non-invasive, cheap and widely available imaging technique that helps in the accurate and immediate diagnosis of this condition. However, it depends highly on the expertise of the operator. It can be difficult to differentiate a hematometra with thin, stretched myometrium from hemorrhagic adnexal masses [10]. Magnetic resonance imaging (MRI) is the gold standard for diagnosis with higher sensitivity in detecting the uterine morphology and the continuity of the vagina when compared to ultrasonography [11]. MRI can accurately depict the uterine contour, shape of uterine cavity and associated cervical and vaginal anomalies. These details are very important in the classification of Müllerian duct anomalies and in surgical planning. In addition, MRI can characterize the contents of obstructed cavities and detect any coexisting renal or urethral abnormalities.

The treatment for OHVIRA syndrome is obviously surgical. It consists on the resection of the vaginal septum in order to relieve the obstructed hemivagina. Some teams opt for treatment in two stages. In the initial surgery, they reduce the hematocolpos and in the second, they respect the excess septum after a period of wound-healing and vaginal remodeling. Hysteroscopic resection of the septum under transabdominal guidance has also been reported in order to preserve the hymenal integrity [12]. Rarely, as in our case, resection of the vaginal septum may not be possible to relieve the hematometrocolpos or recurrent vaginal stenosis may develop and these cases may mandate a unilateral hysterectomy [13].

Complications of surgery are not rare. Stenosis, recurrence of hematometra and infection are possible necessitating a second operation. To overcome this possibility, different treatment modalities have been tried to reduce the need of a second operation and minimize the risk of postoperative re-obstruction such as the use of vaginal molds, dilators and coated tracheobronchial stent [14].

Uterus didelphys with an imperforate hemivagina is the least common abnormality of the Mullerian ducts, but has the best prognosis in terms of alleviation of symptoms and future fertility of these patients. In the longer-term, they are able to conceive, but they are at greater risk for premature delivery. In some cases, infertility can be an issue in these patients, because endometriosis and pelvic adhesions can result from retrograde blood flow if this syndrome is not recognized [15]. For this reason, the management should be fast once the diagnosis is confirmed.

Conclusion

In summary, OHVIRA is a rare congenital anomaly. As it was in our reported case, early diagnosis by ultrasound and MRI leads to early approach to the obstructed hemivagina and resection of vaginal septum at neonatal age.

References

1. Wu WC, Chang WC, Yeh LS, Yang TC (2007) Didelphic uterus and obstructive hemivagina with ipsilateral renal agenesis complicated by pyocolpos. *Taiwan J Obstet Gynecol* 46: 295-298.
2. De Vescovo R, Battisti S, Di Paola V, Piccolo CL, Cazzato RL, et al. (2012) Herlyn-Werner-Wunderlich syndrome: MRI findings, radiological guide (two cases and literature review) and differential diagnosis. *BMC Med Imaging*.
3. Vercellini P, Daguati R, Somigliana E, Vigano P, Lanzani A, et al. (2007) Asymmetric lateral distribution of obstructed hemivagina and renal agenesis in women with uterus didelphys: institutional case series and systematic literature review. *Fertil Steril* 87: 719-724.
4. Carlson BM (1999) Urogenital system. In: *Human embryology and developmental biology* (2nd edn.) St. Louis: Mosby, USA.
5. Bajaj SK, Misra R, Thukral BB, Gupta R (2012) OHVIRA: Uterus didelphys,

- blind hemivagina and ipsilateral renal agenesis: Advantage MRI. *J Hum Reprod Sci* 5: 67-70.
6. Lin TB, Hsieh MF, Han SC, Chin WL, Hsueh YL (2013) Obstructed hemivagina and ipsilateral renal anomaly with uterus didelphys and vaginal discharge. *Taiwanese Journal of ObsT & Gynec* 52: 593-596.
 7. Shavell VI, Montgomery SE, Johnson SC, Diamond MP, Berman JM (2009) Complete septate uterus, obstructed hemivagina, and ipsilateral renal anomaly; pregnancy course complicated by a rare urogenital anomaly. *Arch Gynecol Obstet* 280: 449-452.
 8. Aveiro AC, Miranda V, Cabral AJ, Nunes S, Paulo F, et al. (2011) Herlyn-Werner-Wunderlich syndrome: a rare cause of pelvic pain in adolescent girls. *BMJ Case Rep* 2011.
 9. Han BH, Park SB, Lee YJ, Lee KS, Lee YK (2012) Uterus didelphys with blind hemivagina and ipsilateral renal agenesis (Herlyn-Werner-Wunderlich syndrome) suspected on the presence of hydrocolpos on prenatal sonography. *J Clin Ultrasound Jun* 41: 380-382.
 10. Han B, Herndon CN, Rosen MP, Wang ZJ, Daldrup-Link H (2010) Uterine didelphys associated with obstructed hemivagina and ipsilateral renal anomaly (OHVIRA) syndrome. *Radiology Case Reports* 5: 327.
 11. Dhar H, Razek YA, Hamdi I (2011) Uterus didelphys with obstructed right hemivagina, ipsilateral renal agenesis and right pyocolpos: a case report. *Oman Med J* 26: 447-450.
 12. Kim TE, Lee GH, Choi YM, Jee BC, Ku SY, et al. (2007) Hysteroscopic resection of the vaginal septum in uterus didelphys with obstructed hemivagina: a case report. *J Korean Med Sci* 22: 766-769.
 13. Donnez O, Jadoul P, Squifflet J, Donnez J (2007) Didelphic uterus and obstructed hemivagina: recurrent hematometra in spite of appropriate classic surgical treatment. *Gynecol Obstet Invest* 63: 98-101.
 14. Cooper AR, Merritt DF (2010) Novel use of a tracheobronchial stent in a patient with uterine didelphys and obstructed hemivagina. *Fertil Steril* 93: 900-903.
 15. Smith NA, Laufer MR (2007) Obstructed hemivagina and ipsilateral renal anomaly (OHVIRA) syndrome: management and follow-up. *Fertil Steril* 87: 918-922.