

# Non Syndromic Form of Bilateral Bimaxillary Bull Teeth- A Case Report with Challenges in Pediatric Dentistry

Umopathy Thimmegowda, Veena Arali, Nagarathna C, Rakesh Chikkappa Basavarajendrappa

Department of Pedodontics and Preventive Dentistry, Rajarajeswari Dental College and Hospital, Bangalore, India

## Abstract

Bull teeth or taurodontism is a rare dental anomaly as seen in children in which the involved tooth has an enlarged pulp chamber with apical displacement of the pulpal floor. Endodontic treatment of bull teeth is challenging and requires special handling because of the proximity of canal orifices and apical displacement of roots. In this article, a case of bilateral bull teeth of primary maxillary, mandibular first and second molar is presented.

*Key Words: Taurodontism, Primary maxillary and mandibular, Elongated pulp chamber*

## Introduction

Genetic and Rare Diseases Information Centre (GARD), National Institutes of Health (NIH) and Orphanet, European rare diseases database considers enlarged pulp chambers with root dilacerations in primary teeth as a rare disease.

Witkop defined bull teeth or taurodontism as teeth with large pulp chambers in which the bifurcation or trifurcation are displaced apically and hence the chamber has greater apico-occlusal height than normal teeth and lacks cervical constriction at CEJ [1]. Bull teeth was first described in 1908 by Gorjanovic-Kramberger [2] in a 70,000 year old pre-Neanderthal fossil, discovered in Kaprina, Croatia [3]. Bull teeth were a frequent finding in early humans and is most common today in Eskimos, possibly as a selective adaptation for cutting hide. The term 'taurodontism' was however first stated by Sir Arthur Keith in 1913. The origin of this term is from Greek "tauros" which means "Bull" and "adontos" which means "Tooth" [1]. The origin of the word taurodont is from a combination of Latin and Greek giving the meaning of Bull tooth. Bull teeth is seen with highest frequency in eskimos as reported in the literature [4]. It has also been reported in hybrids of Australoids, the Bush people of South Africa, Mongoloid and Negroid populations as well [5]. Prevalence of bull teeth varies based on population from 0.1% to 48% [6-8]. Prevalence in primary dentition i.e in primary first molar is as low as 0.4% [9]. Further reports on deciduous teeth are lacking. The modern day prevalence of bull teeth in populations varied from 0.54%, in the primary dentitions of Japanese population to as high as 5.6%, in the permanent dentitions of Israeli adults [10]. Among young adults in China it was found to be 46.4%, Finnish population had highest prevalence at 60%. Turkish population showed prevalence of 22.8%, whereas Indian population showed prevalence of bull teeth in mandibular primary first molars to be 0.4% [11]. Most commonly affected teeth are molars followed by premolars in the permanent dentition, while primary molars are commonly affected in the primary dentition but bimaxillary bilateral incidence is very rare as in our case. Multiple theories have been proposed to suggest a possible etiology. One theory states that failure of Hertwig's epithelial root sheath diaphragm to invaginate at the normal level results in short roots and enlarged pup chamber. It is inherited as autosomal dominant

as well as recessive trait. Other theories include interference with induction of epithelial mesenchyme, disrupted homeostasis, high dose of chemotherapy during childhood, bone marrow transplantations, delay in the calcification of the pulp chamber floor [7]. Certain syndromes have been found to occur in association with taurodontism those include Down, Klinefilter's trichodonto-osseous [7], Mohr [12], Apert [13], Smith-Magenis, Williams, McCune Albright and Vander Woude syndromes [9]. In our case it is not associated with any syndromes so its nonsyndromic form of bull teeth. Different classifications have been proposed. Shaw (1928) classified into hypotaurodontism, mesotaurodontism, hypetaurodontism based on the size of pulp chamber and furcation [7]. The present case shows meso and hyper taurodont according to Shaw. Feichtinger and Rossiwall (1977) stated that the distance from the bifurcation or trifurcation of the root to the cement-enamel junction should be greater than the occluso-cervical distance for a taurodontic tooth [14]. Radiographically they appear rectangular in shape, devoid of normal tapering toward the apices. The pulp chambers will be large with increased apico- occlusal height. Absence of normal constriction at the cervix of the tooth, furcation is present at the root apex or few millimeter above [15]. Importance of recognizing a taurodont and their application in different specialties is challenging so a thorough knowledge about taurodont helps in recognizing, managing the rare entity successfully. Hereby presenting a case with bimaxillary bilateral bull teeth and discussing the treatment challenges encountered in routine clinical practice so that it helps the clinician for their practice.

## Case Report

A 5 year old boy visited the Department of Pedodontics and Preventive dentistry for a routine dental checkup. His medical and personal history was noncontributory. Physical and Extra oral examination revealed no abnormalities. On intra oral examination deep carious lesions were seen in relation to left and right mandibular first primary molars. No soft tissue abnormalities were found. Intra oral periapical radiographs of carious teeth showed caries involving enamel and dentin approximating the pulp in right and left primary mandibular first molars. Incidentally maxillary and mandibular primary

Corresponding author: Umopathy Thimmegowda, Senior Reader, Department of Pedodontics and Preventive Dentistry, Rajarajeswari Dental College and Hospital, #14 Ramohalli cross, Kumbalgodu, Mysore road, Bangalore-74, India, Tel: 09986478744; e-mail: umopathygowda@gmail.com

molars on both the side showed enlarged pulp chambers with less defined cervical constriction with furcation located 2mm above the apices along with dilacerations of the roots. A diagnosis of hypertaurodontism in relation to both the mandibular 1<sup>st</sup> and 2<sup>nd</sup> primary molars, bilaterally, bilateral mesotaurodontism in relation to both the maxillary 1<sup>st</sup> and 2<sup>nd</sup> primary molars was made and confirmed with orthopantomograph (OPG). Missing 51 and 64 due to caries. Caries excavation and restorations of the teeth were planned in relation to 74, 84. Band and loop space maintainer in relation to 64 (*Figure 1-3*).

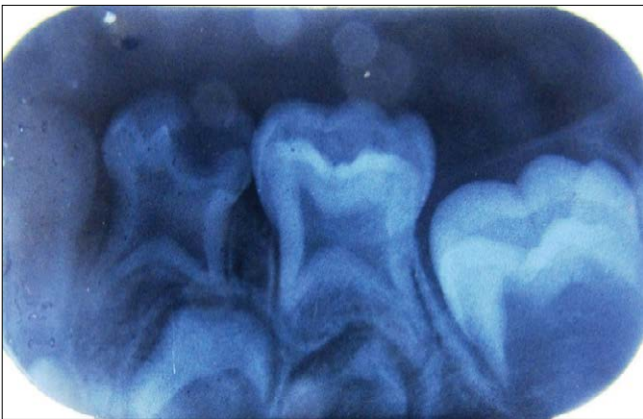
### Discussion

Bull teeth in primary teeth are commonly seen in mandibular primary first molars in Indian population at the incidence rate

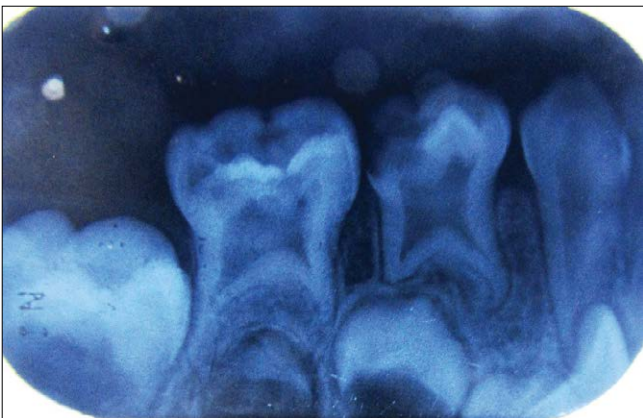is 0.4% [11]. But the occurrence of bilateral bimaxillary bull teeth are a very rare occurrence. So a thorough knowledge about the anatomy, variations in anatomy of the tooth, physiology of eruption, radiographic features of bull teeth and clinical challenges encountered during management helps clinician to manage such cases confidently and efficiently. Bull teeth may complicate pediatric, endodontic, orthodontic, prosthetic treatment planning. So timely accurate clinical and radiological diagnosis will help clinician to plan the treatment. Challenges encountered in primary dentition are enumerated below with management.

### Conservative challenge

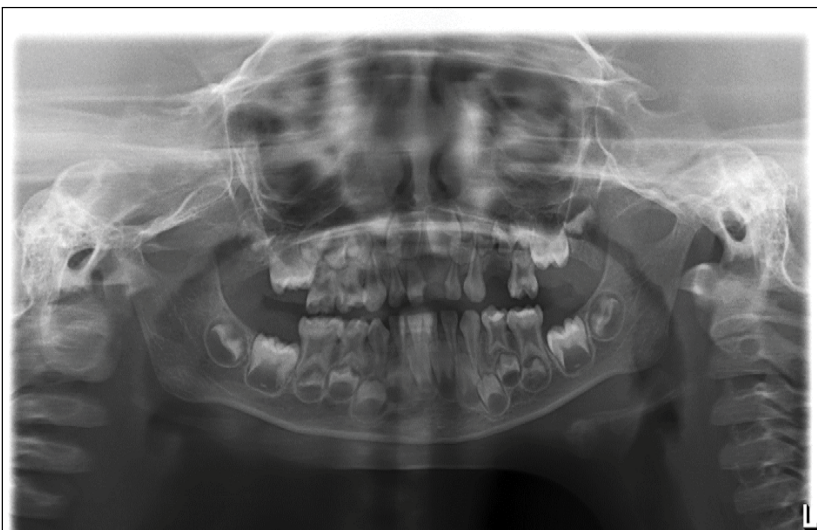In dentinal caries, during restoration cavity preparation in bull teeth is distinct as buccal surfaces approximate each other which needs a conservative cavity preparation such as minimal invasive procedures.



*Figure 1. Intraoral Periapical radiograph in relation to 74, 75.*



*Figure 2. Intraoral Periapical radiograph in relation to 84, 85.*



*Figure 3. OPG of the patient.*

### Endodontic challenge in primary teeth

As the taurodontism tooth shows wide variations in the size and shape of pulp chamber, varying degrees of obliteration and canal configuration, apically placed canal orifices, from a pedodontist point of view, presents a challenging situation in negotiation, instrumentation and obturation in root canal treatment. As bull teeth shows enlarged pulp chambers in primary teeth it is difficult to treat the pulpally involved deep carious lesions, pulpectomy in taurodontism teeth is challenging as the access opening design is different as compared to normal because of the proximity of buccal orifices. Another consideration is during pulp extirpation, wherein bleeding or hemorrhage is more because of large pulp chamber, which could be confused with perforation of the floor [16]. In these cases, 2.5% sodium hypochlorite can be used as irrigant to ensure complete removal of pulp, since the pulp content is voluminous. Biomechanical preparation is distinct as the canal orifices are apically positioned and obturation is done with either incremental filling or with syringe technique using Vitapex as resorption of root is delayed with zinc oxide eugenol resulting with delayed eruption of permanent teeth [17]. In case of any other abnormality like dilacerated roots are associated with taurodont teeth, as in our case flexi files, NiTi files or sometimes S1 Protaper rotary files can be used to aid in biomechanical preparation. Though taurodontism is of rare occurrence, the clinician should be aware of the complex canal system for its successful endodontic management.

### Pediatric consideration in primary teeth

Placement of crown or space maintainer is difficult because of the anatomy and morphology of the crown and loss of cervical constriction at CEJ which extends to the bifurcation or trifurcation of root. Because of the anatomy and morphology of the crown in taurodont tooth, retention of the crown is difficult. So in such cases custom made crown may be advised. During placement of space maintainers in primary teeth, because of altered morphology of the tooth, preformed bands may not fit appropriately, hence custom made bands need to be used accordingly.

### Surgical consideration

The extraction of taurodont tooth is usually complicated

because of the shift in the furcation to apical third. It is reported that extraction of such teeth may not be a problem as large body with little surface area of a taurodont tooth is embedded in the alveolus, unless the roots are widely divergent. Few authors believe that hypertaurodents may pose some problem during extraction because of apical shift of tri-furcation or bifurcation due to difficulty in placement of forceps beaks. This problem can be overcome by proper use of surgical teeth elevators [18]. Extraction is also difficult because of the divergence of the root along with dilacerations as chances of root breakage is more common.

### Prosthetic Considerations in primary teeth

For the prosthetic treatment of taurodont tooth which is grossly decayed tooth (loss of crown) with missing permanent successor, it has been recommended that post placement be avoided for tooth reconstruction, because of less surface area of the tooth is embedded in the alveolus. A taurodont tooth may not have as much stability as cynodont when used as an abutment for prosthetic purposes so extraction and followed by functional space maintainer should be the choice of treatment.

### Orthodontic application in primary teeth

A taurodont tooth is not stable as compared to cynodont when used as an abutment for orthodontic purposes. The lack of cervical constriction would deprive the tooth of the buttressing effect against excessive loading the crown [9].

It is very important for a general dental practitioner to be familiar with bull teeth or taurodontism not only with regards to clinical complications but also its management.

## Conclusion

Taurodont teeth are known to show wide variations in morphology of the pulp chamber and canal complexity. Although it is a very rare entity in deciduous dentition, recognition of such cases is important specially when considering endodontic and surgical treatment in pediatric patients. Knowledge of such conditions helps us to understand the anatomic variations of the pulp chamber and render the treatment accordingly.

## References

1. Witkop CJ. Clinical aspects of dental anomalies. *International Dental Journal*. 1976; **26**:378-90.
2. Gorjanovic-Kramberger K. Uber prismatische Molarwurzeln rezen-ter and diluvialer Menschen. *Anatomischer Anzeiger*. 1908; **32**: 401-13.
3. Prakash R, Vishnu C, Suma B, Velumurugan N, Kandaswamy D. Endodontic management of taurodontic teeth. *Indian Journal of Dental Research*. 2005; **16**: 177-81.
4. Goldstein E, Gottlieb MA. Taurodontism: familial tendencies demonstrated in eleven of fourteen case reports. *Oral Surgery, Oral Medicine, Oral Pathology*. 1973; **36**: 131-44.
5. Mena CA. Taurodontism. *Oral Surgery, Oral Medicine, Oral Pathology*. 1971; **32**: 812-23.
6. Gomes RR, Habckost CD, Junqueira LG, Leite AF, Figueiredo PT, Paula LM, et al. Taurodontism in Brazilian patients with tooth agenesis and first and second-degree relatives: A case control study. *Archives of Oral Biology*. 2012; **57**: 1062-9.
7. Khanna R, Kansal N, Kansal R, Kumar N, Bhullar K. Taurodontism: Etiology, classification and clinical significance. *Indian Journal of Dental Science*. 2012; **4**: 116-8.
8. Jafarzadeh H, Azarpazhooh A, Mayhall JT. Taurodontism: A review of the condition and endodontic treatment challenges. *International Endodontic Journal*. 2008; **41**: 375-88.
9. Manjunath BS, Kovvuru SK. Taurodontism- A review on its etiology, prevalence and clinical consideration. *Journal of Clinical and Experimental Dentistry*. 2010; **2**: e187-90.
10. Jaspers MT, Witkop CJ Jr. Taurodontism an isolated trait associated with syndromes and X-chromosomes aneuploidy. *American Journal of Human Genetics*. 1980; **32**: 396-413.
11. Huseyin S, Ibrahim SB, Yasin Y, Kenan C. Prevalence of Taurodont Primary Teeth in Turkish children. *Oral Health and Dental Management*. 2015; **14**: 23-26.
12. Joshy VR, Jose M, Mohammed R. Taurodontism of multiple teeth-A case report. *Oral & Maxillofacial Pathology Journal*. 2011; **2**: 132-5.

13. Tyagi P, Gupta S. Bilateral taurodontism in deciduous molars: A case report. *People's Journal of Scientific Research*. 2010; **3**: 21-3.

14. Feichtinger C, Rosiwall B. Taurodontism in human sex chromosome aneuploidy. *Archives of Oral Biology*. 1977; **22**: 327-9.

15. Srikanth HS. *SRM Journal of Research in Dental Sciences*. 2014; **5**: 111-113.

16. Panigrahi A, Panigrahi RG, K. T.S, Bhuyan R, Bhuyan SK. Non syndromic Familial Bilateral Deciduous Taurodontism-A First Case report. *Journal of Clinical and Diagnostic Research*. 2014; **8**: ZDO1-ZDO2.

17. Reddy V, Rao V, Arun P, Kumar R. Endodontic Treatment in Primary Molars with Taurodontism-A Case report. *Annals and Essences of Dentistry*. 2010; **2**: 52-55.

18. Durr DP, Campos CA, Ayers CS. Clinical significance of Taurodontism. *Journal of the American Dental Association*. 1980; **100**: 378-81.