

Neurosyphilis Presenting Unilateral Oculomotor Nerve Palsy and Bilateral Pupil Involvement

Hye In Park and Sung Mo Kang*

Ophthalmology department, Inha University Hospital, Korea

*Corresponding author: Sungmo Kang, Professor, Ophthalmology department, Inha University Hospital, Republic of Korea, Tel: 821084958369; E-mail: ksm0724@medimail.co.kr

Received date: December 22, 2014, Accepted date: Feb 23, 2015, Published date: February 26, 2015

Copyright: © 2014 Park HI and Kang SM. This is an open-access article distributed under the terms of the Creative Commons Attribution License, which permits unrestricted use, distribution, and reproduction in any medium, provided the original author and source are credited.

Abstract:

Of the symptomatic disorders associated with neurosyphilis, the earliest manifestation is syphilitic meningitis. Approximately 5% of patients with secondary syphilis develop associated meningitis. Headaches, meningismus, cranial nerve palsies (chiefly, in descending order of frequency, VII, VIII, VI, and II. Here, we report a case of neurosyphilis presenting as unilateral oculomotor nerve palsy with bilateral pupil involvement (Argyll-Robertson pupil).

A 43-year-old male presented with diplopia in both eyes at a neurology clinic 2 weeks before. He had right paralytic blepharoptosis, and both pupils were fixed and both pupils were not observed direct and indirect reflex and anisocoric. We observed Argyll Robertson pupil. He had 35 prisms of right exotropia, 2 prisms of right hypertropia at near and distance in the state of primary deviation and 60-prism right exotropia and 4- prism hypertropia in the state of secondary deviation. He had extraocular movement disorder in all gazes except abduction. We considered oculomotor nerve palsy associated with neurosyphilis based on the Argyll Robertson pupil. His orbit MRI suggested right oculomotor neuritis due to the presence of diffuse thickening of the right oculomotor nerve with enhancement. Finally, he was diagnosed with syphilis as a result of CSF protein 96.0, VDRL 7.5, and FTA-ABS (+) and was administered penicillin (4,000,000 units) and oral steroid (50 mg). One week after, his intraocular pressure was in the normal range. Extraocular movement examination findings were favorable as a result of 20-prism right exotropia at near and distance in the state of primary deviation and 35-prism right exotropia in the state of secondary deviation. He had extraocular movement disorder only in upper gaze.

A diagnosis of neurosyphilis should be considered in patients with serologic evidence of syphilis and one or more of the following cerebrospinal fluid abnormalities; mononuclear pleocytosis, elevated protein, increased immunoglobulin G, or the presence of oligoclonal bands.

Keywords: Neurosyphilis; Oculomotor nerve; pupil; Extraocular movement; Argyll Robertson pupil

Introduction

Syphilis has three stages in its natural history. The primary stage is characterized by the presence of a chancre or painless ulcer and regional lymphadenopathy. If untreated, the secondary stage is detected as a macular rash. Patients may present with neurological involvement at this stage with meningovascular symptoms of headache or stroke. Tertiary syphilis occurs more than 5 years after the primary stage as space-occupying cerebral lesions from intracerebral gumma or myelopathy from tabes dorsalis. HIV co-infection has altered the natural history of syphilis [1]. Neurological involvement is more common and disease progression from the asymptomatic phase to symptomatic neurosyphilis is faster in HIV-positive than in HIV-negative patients.

Neurosyphilis describes the neurologic complications associated with *T. pallidum* infection, and may occur during early or late during the disease course. The spectrum of neurosyphilis is broad [2].

Here, we report a case of neurosyphilis presenting as unilateral oculomotor nerve palsy with bilateral pupil involvement (Argyll Robertson pupil).

Case

A 43 year old male with no ocular trauma or disease history presented with diplopia in both eyes at a neurology clinic 2 weeks before. He had previously sought consultation at an ophthalmology clinic when his visual acuity was 0.4 (OD)/1.0 (OS) and his intraocular pressure was in the normal range. MRD1=0/4 and LFT=7/12 were measured in the right eye, there was right paralytic blepharoptosis, and both pupils were fixed and both pupils were not observed for direct and indirect reflex and was found anisocoric (5 mm (OD)/2 mm (OS) (Figure 1A).

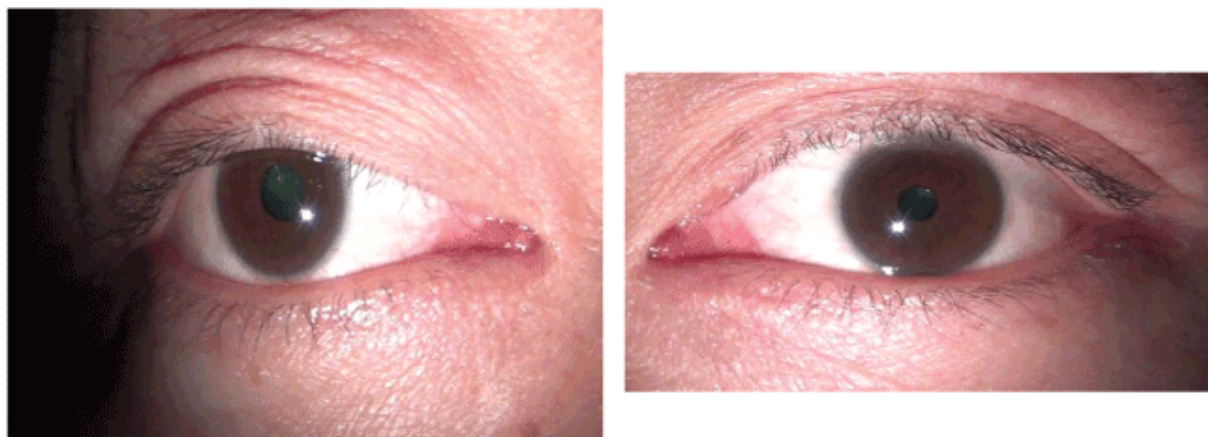

Figure 1: There is the right paralytic blepharoptosis and his both pupils are fixed and not observed with direct and indirect reflex and found anisocoric (5 mm (OD)/2 mm (OS)).

We checked that both pupils were reduced in size when he focused on a near object, but did not constrict when exposed to bright light (Argyll Robertson pupil, Figure 2). Exophthalmometry revealed 23.0 mm (OD), 22.0 mm (OS), and BL=122 mm. Slit exam and funduscopy findings were unremarkable. He had 35 prisms of right exotropia, 2 prisms of right hypertropia at near and distance in the state of primary deviation and 60 prism right exotropia and 4 prism hypertropia in the state of secondary deviation. He had extraocular movement disorder in all gazes except abduction (Figure 3).

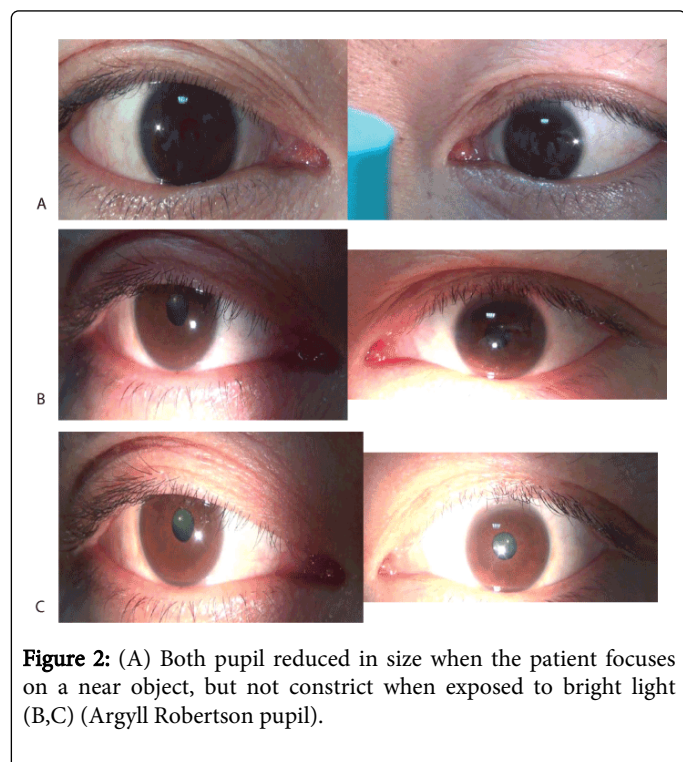


Figure 2: (A) Both pupil reduced in size when the patient focuses on a near object, but not constrict when exposed to bright light (B,C) (Argyll Robertson pupil).

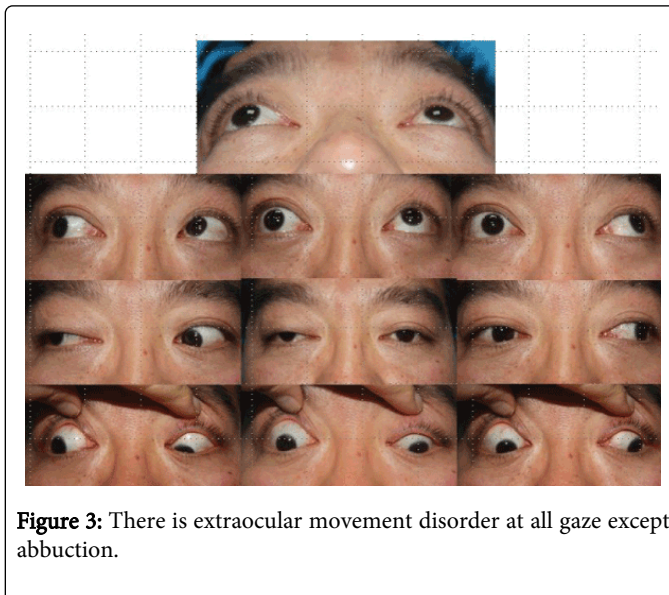


Figure 3: There is extraocular movement disorder at all gaze except abduction.

He didn't have any other clinical sign such as chancre or macular, maculopapular, or pustular rash, and mucous patches and alopecia. But we considered oculomotor nerve palsy associated with neurosyphilis based on the Argyll Robertson pupil. His brain MRI was non-specific except for mild ischemic change in both periventricular white matters but Orbit MRI suggested right oculomotor neuritis due to the presence of diffuse thickening of the right oculomotor nerve with enhancement (Figure 4). Finally, he was diagnosed with syphilis as a result of CSF protein 96.0 mg/dl, VDRL 7.5, and FTA-ABS (+). Blood WBC count was 7560/ μ l and HIV Ag/Ab was negative. He was administered penicillin G (4,000,000 units every 4 hours for 16 days) and oral steroid (Solondo 50 mg for 19 days). One week after, his corrected visual acuity was 1.0 in both eyes and his intraocular pressure was in the normal range. Extraocular movement examination findings were favorable as a result of 20 prism right exotropia at near and distance in the state of primary deviation and 35 prism right exotropia in the state of secondary deviation. He had extraocular movement disorder only in upper gaze.

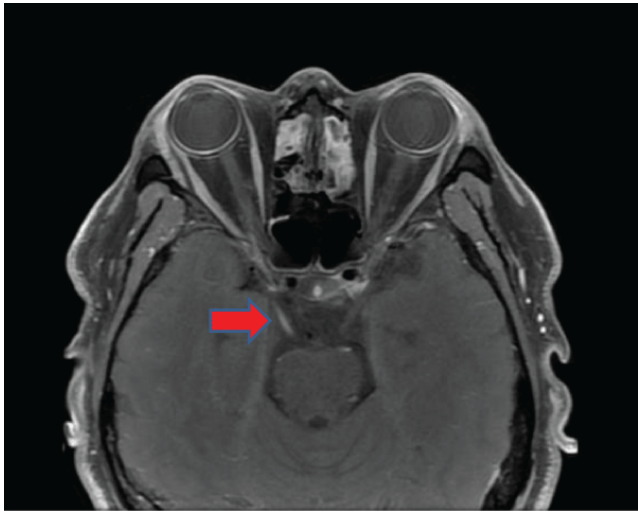


Figure 4: At T2 axial view Diffuse thickening of right oculomotor nerve with enhancement in the Orbit MRI.

Discussion

The most common form of neurosyphilis currently diagnosed is asymptomatic neurosyphilis. Individuals with this form of the disease come to medical attention because of serologic evidence of syphilis in the absence of neurologic sequelae. Examination of cerebrospinal fluid reveals evidence of neurosyphilis. These patients are at risk of developing symptomatic disease [3]. Of the symptomatic disorders associated with neurosyphilis, the earliest manifestation is syphilitic meningitis, which typically occurs within the first 12 months of infection and may accompany features of secondary syphilis [4]. Although the majority of patients with CSF abnormalities occurring in association with secondary syphilis are neurologically asymptomatic, approximately 5% of patients with secondary syphilis develop associated meningitis. Headaches, meningismus, cranial nerve palsies (chiefly, in descending order of frequency, VII, VIII, VI, and II), hearing loss, tinnitus, and vertigo may be observed in isolation or in combination in upwards of 40% of patients with secondary syphilis [5].




Figure 5: There is extraocular movement disorder at only upper gaze (After 1 week).

Pupil abnormalities are prevalent in roughly 45-53% of neurosyphilis [6]. The most common pupil abnormalities include bilaterally small pupils who react briskly to near stimuli, called Argyll Robertson pupils, or bilaterally large tonic pupils [6-8]. We observed Argyll Robertson pupils with unilaterally large tonic pupil through this case. But it is uncertain that unilaterally large tonic pupil is due to neurosyphilis. It is really regrettable that we didn't distinguish from Adie's pupil by pilocarpine test.

A cardinal requirement for the diagnosis of neurosyphilis is a reactive serum treponemal test, and the condition should be diagnosed in anyone with serology reactive for a treponemal test occurring in association with a reactive CSF VDRL [9]. A diagnosis of neurosyphilis should be considered in patients with serologic evidence of syphilis and one or more of the following cerebrospinal fluid abnormalities; mononuclear pleocytosis, elevated protein, increased immunoglobulin G, or the presence of oligoclonal bands. However, undoubtedly, neurosyphilis is over diagnosed when these criteria are used, and it has been suggested that the cerebrospinal fluid fluorescent treponemal antibody absorption test is a more sensitive one for the screening of neurosyphilis [10].

The treatment regimen for neurosyphilis should be 12-24 million units of crystalline aqueous penicillin administered intravenously daily (2-4 million units every 4 hours) for a period of 10-14 days. This regimen generally requires hospitalization, but prolonged hospitalization may be avoided in reliable, well-motivated patients by the placement of an indwelling catheter and home administration of penicillin after the first 24-48 hours of therapy. The penicillin should be administered at no less than 4 hour intervals to maintain penicillin levels consistently at or above treponemicidal values and to avoid the

subtherapeutic troughs that occur when it is administered less frequently [11].

References

1. Brightbill TC, Ihmeidan IH, Donovan MJ, Berger JR, Katz DA (1995) Neurosyphilis in HIV positive and HIV negative patients: neuroimaging findings. *AJNR Am J Neuroradiol* 16: 703-711.
2. Doherty L, Fenton KA, Jones J, Paine TC, Higgins SP et al. (2002) Syphilis: old problem, new strategy. *BMJ* 325: 153-156.
3. French P, Gomberg M, Janier M, Schmidt B, Vader PVV et al. (2009). IUSTI: 2008 European Guidelines on the Management of Syphilis. *Int J STD AIDS* 20: 300-309.
4. Harris DE, Enterline DS, Tien RD (1997). Neurosyphilis in patients with AIDS. *Neuroimaging Clin N Am* 7: 215-221.
5. Seeley WW, Venna N (2004) Neurosyphilis presenting with gummatous oculomotor nerve palsy. *J Neurol Neurosurg Psychiatry* 75: 789.
6. Holland BA, Perrett LV, Mills CM (1986) Meningovascular syphilis: CT and MR findings. *Radiology*.158: 439-442.
7. Johns DR, Tierney M, Felsenstein D (1987) Alteration in the natural history of neurosyphilis by concurrent infection with the human immunodeficiency virus. *N Engl J Med* 316: 1569-1572.
8. Englestein ES, Ruderman MI, Troiano RA, Digiovanni VJ (1986) Dilated tonic pupils in neurosyphilis. *J Neurol Neurosurg Psychiatry*.49: 1455-1457.
9. Tran TH, Cassoux N, Bodaghi B, Fardeau C, Caumes E et al. (2005) Syphilitic uveitis in patients infected with human immunodeficiency virus. *Graefes Arch Clin Exp Ophthalmol* 243: 863-869.
10. Durnian JM, Naylor G, Saeed AM (2004) Ocular syphilis: the return of an old acquaintance. *Eye* 18: 440-442.
11. Aldave AJ, King JA, Cunningham ET Jr. (2001) Ocular syphilis. *Curr Opin Ophthalmol* 12: 433- 441.