

Myelinated Retinal Nerve Fibers in Children: OCT Imaging, Refractive Error and Vision

Scott O'Brien¹, Derek T Sprunger¹, Maria E Lim¹ and Jingyun Wang^{1,2*}

¹Department of Ophthalmology, Eugene and Marilyn Glick Eye Institute, Indiana University School of Medicine, Indianapolis, IN, USA

²Salus University Pennsylvania College of Optometry, Elkins Park, PA, USA

Abstract

Purpose: To characterize peripapillary retinal nerve fiber layers (RNFL's) and macular retinal structure in children with unilateral myelinated retinal nerve fibers (MRNFs). We also investigated the correlation between MRNF abnormalities and refractive error/visual acuity.

Methods: Twelve children (7-13 years old) with MRNFs were included. Fourier domain optical coherence tomography was used to image both the peripapillary RNFL and the macular retinal structures in 6 patients. Using the instrument's segmentation software, global RNFL thickness and central subfield thickness (CST) of the macula were analyzed. Planimetry was used to quantify the MRNF area observed on fundus photography. Visual acuity and cycloplegic refractive errors (spherical equivalent) were also recorded. Results from the MRNF-affected eye were compared with the fellow eye.

Results: The global RNFL thickness of the eyes with MRNFs ($152 \pm 13.9 \mu\text{m}$) was significantly higher than the fellow eyes ($114.3 \pm 15.2 \mu\text{m}$) ($P=0.003$). The global RNFL thickness of the fellow eye was in normal range, and no significant differences were detected in macular CST between the eyes with MRNFs and fellow eyes ($P=0.403$). The MRNF area was significantly correlated with the spherical equivalent of the affected eye ($P=0.002$). In addition, the interocular difference of RNFL thickness between eyes was significantly correlated with anisometropia ($P=0.03$).

Conclusions: Eyes with MRNFs show a significantly thicker global peripapillary RNFL trend as compared to the fellow eye, and the area of MRNFs is correlated with the development of myopia and anisometropia, but not correlated to visual acuity.

Keywords: OCT; Retinal imaging; Myelinated retinal nerve fibers; Children; Myopia; Amblyopia

Introduction

Myelinated retinal nerve fibers (MRNFs) are developmental anomalies of the retina that appear as white to grey-white striated patches with feathery edges, often distributed around or contiguous with the optic disc and surrounding the vascular arcades. Based on a fundus photography study including 5789 patients, Kodama et al. reported that MRNFs occur in approximately 0.57% of the population, most often involving superior and inferior-temporal peripapillary areas. No MRNFs were discovered in the macula, and 7.7% were bilateral [1].

Patients with MRNFs may be asymptomatic or show significant visual dysfunction with acuity ranging from 20/40 to hand motion in previous reports [2,3]. Myopic anisometropia and amblyopia are often suggested to be associated with unilateral MRNFs, but their relationships with MRNF surface areas were not quantified [3]. For instance, Schmidt et al. reported that widespread MRNFs of the optic disc are associated with the development of myopia in adult patients, but they did not quantify the correlation between MRNF surface area and refractive error [4]. Interestingly, most previous studies investigating this developmental eye disease--MRNF and refractive error development--focus exclusively on adult patients. Very few studies involve solely a pediatric population. Kee et al. reported that the area of MRNFs is related to visual acuity improvement in 12 children; however, there is no quantitative MRNF data to demonstrate this relationship [2].

Previously, most studies have reported MRNFs with fundus photographs. While clinical use of Optical Coherence Tomography (OCT) has increased, there are only a few OCT retinal imaging case reports [5-9] and studies [10,11] on this specific patient population. In

6 pediatric eyes with MRNFs, Oh et al. reported that the distribution of the MRNFs is associated with the development of myopia. It remains unclear how MRNF surface area or the thickness of the peripapillary retinal nerve fiber layer (RNFL) in the eye with MRNFs is associated with myopia--particularly in children. OCT represents a newer technique to evaluate myelination and OCT images could be analyzed further to understand the effects on the retina. This study: 1) analyzed the Optical Coherence Tomography (OCT) of the peripapillary retinal nerve fiber layer (RNFL) and macula of MRNF and fellow eyes; 2) attempted to correlate MRNF abnormalities (MRNF surface area and RNFL thickness) with spherical equivalence and best corrected visual acuity presenting in pediatric patients.

Methods

This study combined both retrospective chart review and prospective measurements. The Institutional Review Board of Indiana University approved this research protocol as well as the Health Insurance Portability and Accountability Act (HIPAA) compliance forms. The patients were identified via chart review at our institution

***Corresponding author:** Jingyun Wang, Salus University Pennsylvania College of Optometry, 8360 Old York Rd, Elkins Park, PA 19027, USA, Tel: 215-780-1376; E-mail: jingyun.wang@gmail.com

Received June 03, 2016; **Accepted** October 28, 2016; **Published** October 31, 2016

Citation: O'Brien S, Sprunger DT, Lim ME, Wang J (2016) Myelinated Retinal Nerve Fibers in Children: OCT Imaging, Refractive Error and Vision. J Clin Exp Ophthalmol 7: 596. doi:10.4172/2155-9570.1000596

Copyright: © 2016 O'Brien S, et al. This is an open-access article distributed under the terms of the Creative Commons Attribution License, which permits unrestricted use, distribution, and reproduction in any medium, provided the original author and source are credited.

from June 2011 to February 2015, and were contacted for a possible additional prospective study. Informed consent was obtained from the subject's parents. The ocular conditions of all participants were diagnosed and managed by a pediatric ophthalmologist at Indiana University School of Medicine.

Participants

Inclusion criteria: Children diagnosed with unilateral MRNF were included and had fundus photography obtained. All participants were over 32 weeks gestational age without retinopathy of prematurity.

Exclusion criteria: Children with conditions that precluded high quality ocular imaging in the clinic setting (i.e best corrected visual acuity worse than 20/250, significant nystagmus, developmental delay), glaucoma, cataracts, corneal transplant, and/or co-existing ocular or congenital infections.

Cycloplegic refraction (retrospective)

At the time of retinal imaging, a cycloplegic refraction was performed using retinoscopy (cyclopentolate 1%). Refractive error and spherical equivalent (SEQ) were recorded. Astigmatism of greater than or equal to 1 D was considered significant. Anisometropia was considered significant if the interocular difference of SEQs was greater than or equal to 1 D.

Best-corrected visual acuity (BCVA, retrospective) was measured using crowded Snellen letters.

Fundus photograph and planimetry (retrospective)

Fundus photographs were taken with a non-mydratic auto fundus camera (NIDEK AFC-230, Eye and Health Care NIDEK Co. LTD, Japan). Shown in Figure 1, planimetry, was carried out by measuring the total patching surface area—determined by a software associated with the fundus camera—covered by the myelinated retinal nerve fibers (called “MRNF surface area” hereafter) [4]. For patients in this study, an exact measurement of the outer margins of the myelinated nerve fibers was not possible because they spread beyond the margin of the photographs. Therefore, only the minimum area could be determined.

OCT retinal imaging procedure (prospective)

OCT retinal imaging was completed in patients who were available for the prospective aspect of the study. The 3 mm circular scan for

peripapillary retinal nerve fiber layer (RNFL) thickness was measured with a high-resolution Fourier domain OCT (fdOCT) (iVue; Optovue Inc., Fremont, CA). Two or three scans were obtained from each eye, and the circular scan with the highest signal-noise-ratio was selected. The instrument's software calculated the overall average RNFL thickness. The software also separated the RNFL thickness around the optic disc into 4 distinct quadrants (superior, inferior, nasal, and temporal) and calculated the overall global thickness for each eye. Image quality was checked carefully after each image acquisition, and all images with insufficient quality or with any artifact were reacquired until image quality was satisfactory.

Macular thickness was also measured using the same fdOCT. Two or three macular volume scans across the fovea were obtained from each eye, and the volume scan with the highest signal-noise-ratio was selected. Average sectional total thickness was automatically determined by the instrument's software using a modified Early Treatment Diabetic Retinopathy Study (ETDRS) circle grid (center, middle, and outer rings: 1, 2, and 3 mm). Only the center and middle ring results were reported in this paper. Using the instrument's built-in software, the total Central subfield thickness (CST) was measured (i.e., 1 mm in diameter). Moving further from the center of the retina, the software also calculated the total thickness of the 4 surrounding quadrants (superior, inferior, nasal, and temporal) of the middle ring.

Data analysis

MRNF surface area, peripapillary RNFL thickness, and macular thickness were compared for the MRNF and fellow eyes using a paired t-test. These variables were then correlated with spherical equivalent and best corrected visual acuity. P values of less than 0.05 were considered to be statistically significant. A Bonferroni correction criterion is used for multiple comparisons.

Results

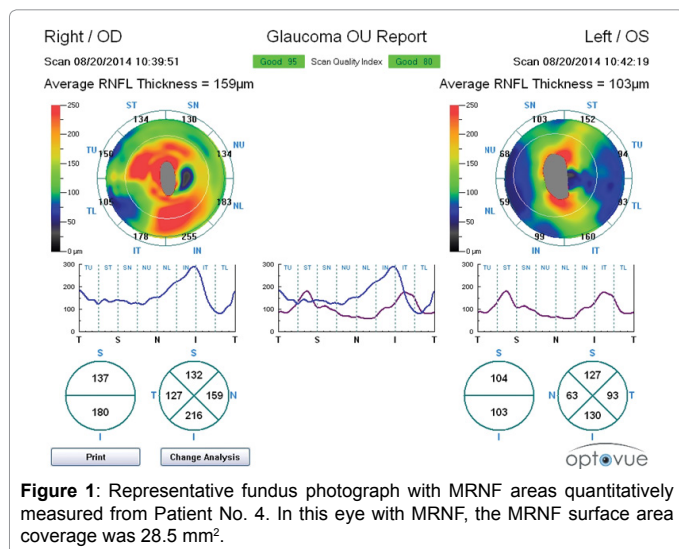
Twelve children with unilateral MRNF were initially identified and reviewed, while 6 patients were enrolled for OCT imaging. The fellow eye was used as a control for comparison purposes. Gestational age at birth of all participants was over 36 weeks, with the exception of one patient who was born at 33 weeks (without history of retinopathy of prematurity). Patient characteristics are summarized in Table 1. Two patients had well-controlled intermittent exotropia. All patients with amblyopia were previously treated with patch occlusion of the fellow eye. MRNF affected right and left eyes equally.

Age of participants was between 7 and 14 years old. Best corrected visual acuity ranged from 20/30 to 20/250 for MNRN eyes, and from 20/20 to 20/30 for fellow eyes. Spherical equivalent of the eyes with MRNF ranged from -14.4D to +7.4D (Table 1). Half of the affected eyes (6/12) exhibited significant astigmatism, often at an oblique axis, ranging from 1D to 3D. Of 12 eyes with MRNF, 7 eyes presented with significant anisometropia, ranging from 1 to 12D.

Planimetry of 10 patients revealed MNRN surface area coverage that ranges from 1.9 to 28.5 mm² with the values listed in Table 1. Representative MRNF surface area analysis on Patient No. 4 is shown in Figure 1.

The MRNF eyes show higher peripapillary RNFL thickness

The global RNFL thickness of the eyes with MRNF ($152 \pm 13.9 \mu\text{m}$) was significantly higher than the fellow eyes ($114.3 \pm 15.2 \mu\text{m}$) (Paired t-test, $t=4.1$, $P=0.003$; an example OCT image is shown in Supplementary file). The global RNFL thickness of the fellow eye was

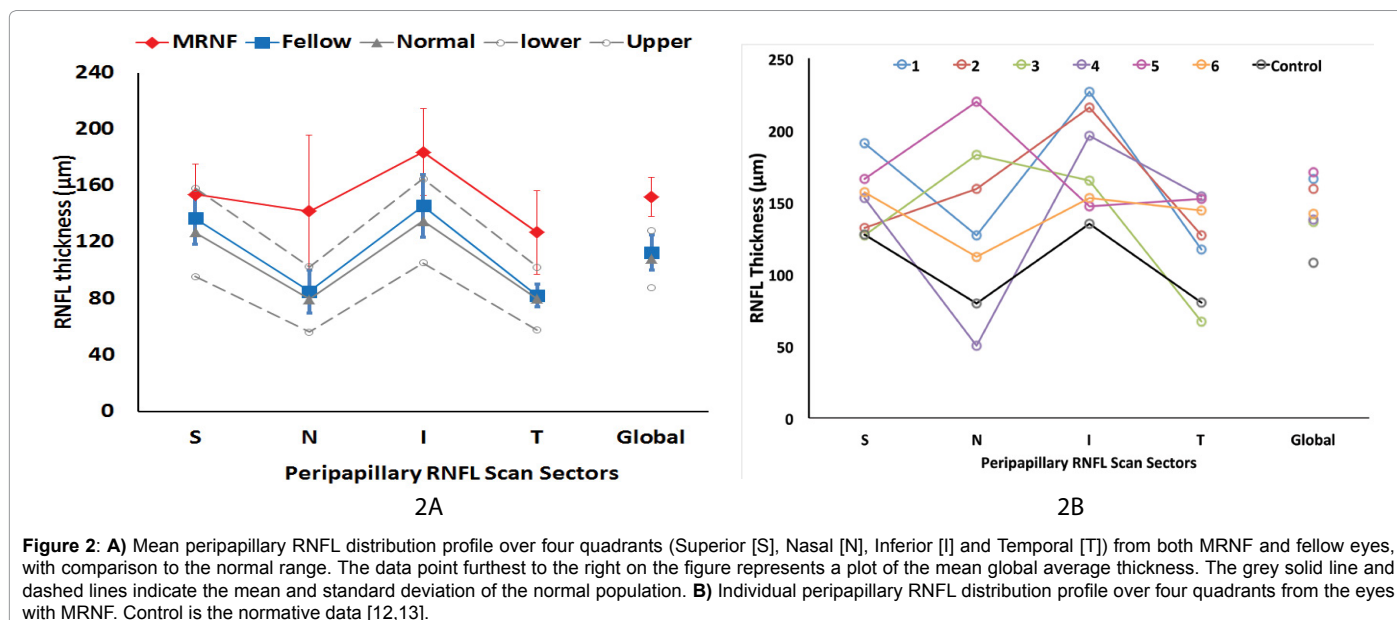


Patients	Eye	Gender (M/F)	Age at Rx (years)	Sphere	Cyl	Axis	SEQ	Best Corrected VA	Anisometropia (Diopters)	Myelinated Surface Area
1	MRNF (L)	F	9	2	2.5	83	3.25	20/20	0.75	166
	Fellow			2.5	3	92	4	20/25		144
2	MRNF (R)	F	12.3	-15.75	2.75	105	-14.38	20/250	12.13	159
	Fellow			-2.5	0.5	100	-2.25	20/30		103
3	MRNF (L)	M	7.4	-9.5	1.5	135	-8.75	20/150	9.25	136
	Fellow			0.5			0.5	20/20		102
4	MRNF (R)	F	7.4	-3.25			-3.25	20/60	3.5	138
	Fellow			0.25			0.25	20/20		108
5	MRNF (L)	M	13.3	-8.25	3	70	-6.75	20/30	6.75	171
	Fellow			Plano			0	20/20		124
6	MRNF (L)	F	11.6	-2	2.5	45	-0.75	20/40	1.5	142
	Fellow			0.75			0.75	20/20		105
7	MRNF (R)	M	9	5.25	0.5	75	5.5	20/25	-0.75	NA
	Fellow			4.5	0.5	100	4.75	20/30		NA
8	MRNF (L)	F	11.6	1.25			1.25	20/30	-0.75	NA
	Fellow			0.5			0.5	20/30		NA
9	MRNF (R)	F	8.1	-4.75	0.75	80	-4.375	20/30	1.125	NA
	Fellow			-3.75	1	90	-3.25	20/80		NA
10	MRNF (L)	F	8.8	1.5	0.5	90	1.75	20/80	0	NA
	Fellow			1.5	0.5	90	1.75	20/100		NA
11	MRNF (R)	M	12.3	6.5	1.75	50	7.4	20/40	0.35	NA
	Fellow			7.75			7.75	20/40		NA
12	MRNF (R)	F	8.2	-3.25	0.5	70	-3	20/40	3.75	NA
	Fellow			0.75			0.75	20/20		NA

Note:

- 1) Anisometropia is calculated that spherical equivalent of the fellow eye is subtracted by spherical equivalent of the mRNF eye. The negative values indicate that the mRNF eye is more hyperopic.
- 2) Patient No. 5: Chiari Malformation; Patient No. 8: Juvenile Pilocytic Astrocytoma;
- 3) Patient No. 9: Duane's Syndrome; Patient No. 3: 6 X(T) at near 10X(T) at distance; Patient No. 10: 12 X(T) at near 4X(T) at distance; Patient No. 11 was born at gestational age of 33 weeks.

Table 1: A summary of the patients (“#” indicates when data is not available).



within the normal range [12,13]. Global thickness of the peripapillary RNFL is listed in Table 1. Peripapillary RNFL thickness distribution profile over the 4 quadrants generally showed a thicker trend in the eyes with MRNF than the fellow eyes (Figure 2A). With Bonferroni correction criteria of 0.0125, no significant difference was detected

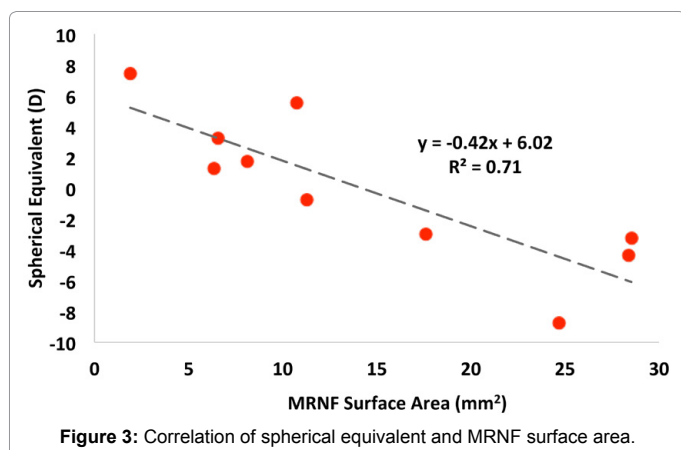
between quadrants (Paired t-test, P=0.02, 0.06, 0.03, 0.03 for S, N, I, and T quadrants, respectively). Notably, RNFL thickness per individual varies, most likely due to variable distribution of MRNFs (Figure 2B and Table 2). Interestingly, the average RNFL thickness of the nasal (N), inferior (I), and temporal (T) quadrants in the eyes with MRNF was

Peripheral RNFL thickness (µm)						
Patient	Eye	Superior	Nasal	Inferior	Temporal	Global
1	MRNF (L)	191	127	227	117	166
	Fellow	159	100	199	118	114
2	MRNF (R)	132	159	216	127	159
	Fellow	127	63	130	93	103
3	MRNF (L)	127	183	165	67	136
	Fellow	121	77	126	82	102
4	MRNF (R)	153	50	196	154	138
	Fellow	132	79	143	76	108
5	MRNF (L)	188	220	147	152	171
	Fellow	160	108	138	92	124
6	MRNF (L)	157	112	153	144	142
	Fellow	199	83	149	71	105

Table 2: A summary of the peripapillary RNFL thickness of the patients

Macular total thickness (µm)						
Patient	Eye	Center	Superior	Nasal	Inferior	Temporal
1	MRNF (L)	239	333	330	323	314
	Fellow	235	320	324	321	302
2	MRNF (R)	236	184	274	282	255
	Fellow	250	297	299	287	282
3	MRNF (L)	234	283	279	294	299
	Fellow	223	293	298	295	286
4	MRNF (R)	269	325	300	104	208
	Fellow	270	325	322	315	313
5	MRNF (L)	282	340	325	313	333
	Fellow	255	325	335	322	318
6	MRNF (L)	264	330	328	334	331
	Fellow	234	315	318	318	305
Summary	MRNF (mean)	254.0	299.2	306.0	275.0	290.0
	MRNF (SD)	20.3	59.9	25.3	85.9	49.3
	Fellow (mean)	244.5	312.5	316.0	309.7	301.0
	Fellow (SD)	17.0	14.1	14.7	14.9	14.4
	P-value	0.23	0.54	0.16	0.37	0.61

Table 3: A summary of macular thickness of the patients



overall thicker than the normal range. Only the RNFL thickness of the superior (S) quadrant in the eyes with MRNF was considered normal.

No differences detected in macular thickness

No significant differences in central subfield thickness (CST) were observed between the MRNF and fellow eyes. (Paired t-test, $t=0.88$, $P\text{-value}=0.403$). The CST values of both the MRNF and fellow eyes were also within the normal range [14]. The average macular thickness

values for the 1mm central foveal subfield and for each quadrant of the 2 mm diameter circle are shown in Table 3.

Refractive error was significantly correlated with planimetry

To understand the correlation between refractive error and MRNF surface area, we compared SEQ and the MRNF surface areas using correlational studies. The MRNF surface area was significantly (negatively) correlated with spherical equivalent ($N=10$, $r=0.84$, $t=4.38$, $P\text{-value}=0.002$), for example, a larger MRNF surface area is associated with a higher magnitude of myopia (Figure 3).

Interocular difference of peripapillary RNFL thickness was positively correlated with anisometropia

OCT imaging also provides a comparison of RNFL thickness between eyes. The peripapillary RNFL thickness difference (between the MRNF and fellow eye) was calculated for each of the 6 patients. This thickness difference between eyes was significantly (positively) correlated with anisometropia ($N=6$, $r=0.85$, $t=3.2$, $P\text{-value}=0.03$) (Figure 4). For example, a higher anisometropia was associated with a larger RNFL thickness difference between eyes.

Best corrected visual acuity and planimetry or peripapillary RNFL

There was no correlation found between visual acuity of the eyes with MRNF and planimetry or peripapillary RNFL.

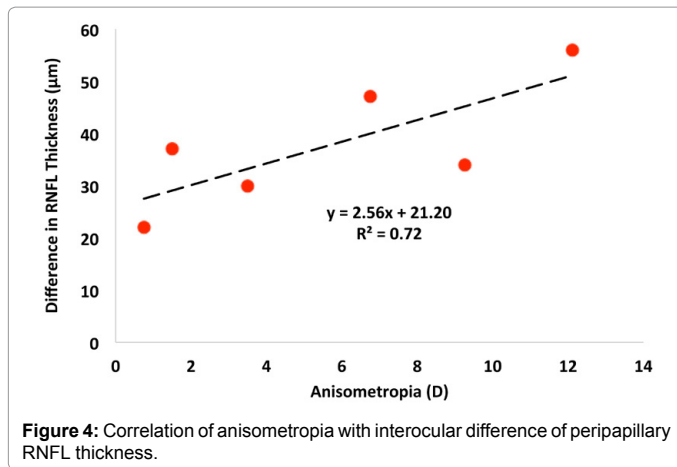


Figure 4: Correlation of anisometropia with interocular difference of peripapillary RNFL thickness.

Discussion

Although macular thickness was within the normal range, we found that the peripapillary RNFL of the MRNF eye was significantly thicker than the fellow eye. The distribution of peripapillary RNFL thickness varied among individuals, which may result from variable distribution of MRNFs—such results agree with a previous study stating that the circular scan of fdOCT is significantly associated to the major distribution of MRNFs [11]. We also observed that the MRNF surface areas were negatively correlated with refractive errors and, therefore, our findings demonstrate that widespread MRNFs of the optic disc are associated with the development of myopia. A significant positive correlation between anisometropia and interocular difference of peripapillary RNFL suggests that a pathogenic mechanism of myopic anisometropia is associated with MRNFs.

Some suggest that partial occlusion from MRNFs may induce myopia, similar to form deprivation [15]. In a recent study involving 12 adults, Lee et al. reported that local retinal sensitivity, measured with microperimetry, was decreased in the retinal areas underlying MRNFs [10]. Schmidt et al. also found that microperimetry of the area around the optic disc showed a relative scotoma near the blind spot corresponding to myelinated nerve fibers. The decreased visual function might be related to abnormal axial elongation in the eye with MRNFs. In our study, the macula was normal in the eyes with MRNF. The refractive error showed a trend of association with the MRNF surface area. Because MRNF affects the peripheral retina more than the macula, our results agree with the hypothesis that partial occlusion from MRNFs may induce myopia.

Due to significant anisometropia associated with MRNF-affected eyes, patients are at a high risk for amblyopia. Even with previous amblyopia treatment, 7 patients in this study remained amblyopic. Our visual acuity outcome varies from previous reports in the eye with MRNF. Summers et al. reported two cases in which aggressive occlusion improved vision in patients with MRNF [16]. Kasmann et al. reported similar results in 4 cases [17]. Hittner et al. reported that 5 out of 12 patients with MRNF had good visual acuity [18]. Straatsma et al. suggested that younger patients who have parafoveal fixation and no strabismus respond best to amblyopia therapy, and advocated earlier therapy to treat the amblyopia associated with MRNFs [19]. Kee et al. suggested that the area of MRNFs is related to visual acuity improvement in the eye with MRNFs [2]. We found that the visual acuity in the eyes with MRNF is not significantly associated with MRNF surface area or RNFL thickness. Such results are not surprising because visual acuity is

more complicated than structure and can be affected by other variables such as onset of deprivation and compliance with glasses and patching [20]. We had limited ability to explore the relationship between the area of MRNF and visual acuity.

In this study, we compared our data with normative data on the OCT manual on RNFL thickness for two reasons: 1) the normative data were collected with the same brand of OCT instrument as our studies [12,13]; and 2) Further, our previous study did not see significant RNFL differences with age [21,22].

Our study is limited by our small sample size from a tertiary care center. Tabletop mounted OCT requires good patient cooperation and fixation. By excluding children who fixate poorly in the iVue imaging device, i.e. with visual acuity worse than 20/250 or significant nystagmus, we may have excluded patients with more severe retinal abnormalities [23-25]. Additionally, the built-in software of fundus photography is not ideal to measure MRNF surface area. Planimetry provides a quantitative tool for comparison to previous studies that only qualifies severity of MRNF by location (“spared the macular area” or “merely around the optic disc”) [4]. Another consideration is that patients with good visual acuity and MRNF are less likely to seek care and would not be represented in our study. Visual function was estimated by visual acuity in this study. This is limited to central vision and not as sensitive as contrast sensitivity function. Visual field and contrast sensitivity function may be used in future studies.

In conclusion, OCT may help clinicians differentiate retinal abnormalities associated with MRNFs versus abnormalities due to other reasons. Also, the amount of retina affected by MRNFs may help guide treatment as we found that an increased area of involvement may predict poorer final visual outcome potential. The results from this study encourage a multi-center study in the future. Our findings contribute to the growing application of OCT in pediatric populations.

Acknowledgements

This study is supported by a Showalter Foundation Fund given to Dr. Wang and a Research to Prevent Blindness (RPB) Unrestricted Grant to the Glick Eye Institute.

Commercial Relationship

All authors have no commercial relationship.

Financial Support

This study is supported by a Research to Prevent Blindness (RPB) Unrestricted Grant to the Glick Eye Institute.

References

1. Kodama T, Hayasaka S, Setogawa T (1990) Myelinated retinal nerve fibers: prevalence, location and effect on visual acuity. *Ophthalmologica* 200: 77-83.
2. Kee C, Hwang JM (2005) Visual prognosis of amblyopia associated with myelinated retinal nerve fibers. *Am J Ophthalmol* 139: 259-265.
3. Tarabishy AB, Alexandrou TJ, Traboulsi EI (2007) Syndrome of myelinated retinal nerve fibers, myopia, and amblyopia: a review. *Surv Ophthalmol* 52: 588-596.
4. Schmidt D, Meyer JH, Brandt-Dohm J (1996) Wide-spread myelinated nerve fibers of the optic disc: do they influence the development of myopia? *Int Ophthalmol* 20: 263-268.
5. Bass SJ, Westcott J, Sherman J (2016) OCT in a Myelinated Retinal Nerve Fiber Syndrome with Reduced Vision. *Optom Vis Sci* 93: 1285-1291.
6. Grzybowski A, Winiarczyk I (2015) Myelinated retinal nerve fibers (MRNF) - Dilemmas related to their influence on visual function. *Saudi J Ophthalmol* 29: 85-88.
7. Holló G (2016) Influence of myelinated retinal nerve fibers on retinal vessel density measurement with AngioVue OCT angiography. *Int Ophthalmol*.

8. Moradian S, Karim S (2009) Unilateral myelinated retinal nerve fiber layer associated with axial myopia, amblyopia and strabismus. *J Ophthalmic Vis Res* 4: 264-265.
9. Yalcin E, Balci O, Akingol Z (2013) Association of extensive myelinated nerve fibers and high degree myopia: case report. *Indian J Ophthalmol* 61: 606-607.
10. Lee KH, Kim SW, Kwon SS, Oh J, Huh K (2016) Microperimetry and spectral domain optical coherence tomography in myelinated retinal nerve fibers. *Int J Ophthalmol* 9: 170-172.
11. Oh BL, Hwang JM, Woo SJ (2014) Myelinated nerve fiber-associated local scleral excavation and induced axial myopia. *Retina* 34: 2028-2036.
12. Garas AP, Vargha GH (2010) Reproducibility of retinal nerve fiber layer and macular thickness measurement with the RTVue-100 optical coherence tomograph. *Ophthalmology* 117: 738-746.
13. Rao HL (2010) Comparison of different spectral domain optical coherence tomography scanning areas for glaucoma diagnosis. *Ophthalmology* 117: 1692-1699.
14. Wu WC, Lin RI, Shih CP, Wang NK, Chen YP, et al. (2012) Visual acuity, optical components, and macular abnormalities in patients with a history of retinopathy of prematurity. *Ophthalmology* 119: 1907-1916.
15. Wallman J, Turkel J, Trachtman J (1978) Extreme myopia produced by modest change in early visual experience. *Science* 201: 1249-1251.
16. Summers CG, Romig L, Lavoie JD (1991) Lavoie, Unexpected good results after therapy for anisometropic amblyopia associated with unilateral peripapillary myelinated nerve fibers. *J Pediatr Ophthalmol Strabismus* 28: 134-136.
17. Käsmann B, Höh H, Ruprecht KW (1996) Results of occlusion therapy in anisomyopic amblyopia with myelinated nerve fibers. *Ger J Ophthalmol* 5: 241-245.
18. Hittner HM, Antoszyk JH (1987) Unilateral peripapillary myelinated nerve fibers with myopia and/or amblyopia. *Arch Ophthalmol* 105: 943-948.
19. Straatsma BR, Heckenlively JR, Foos RY, Shahinian JK, et al. (1979) Myelinated retinal nerve fibers associated with ipsilateral myopia, amblyopia, and strabismus. *Am J Ophthalmol* 88: 506-510.
20. Holmes JM, Repka MX, Kraker RT, Clarke MP (2006) The treatment of amblyopia. *Strabismus* 14: 37-42.
21. Wang J, Spencer R, Leffler JN, Birch EE (2012) Characteristics of peripapillary retinal nerve fiber layer in preterm children. *Am J Ophthalmol* 153: 850-855.
22. Yanni SE, Wang J, Cheng CS, Locke KI, Wen Y, et al. (2013) Normative reference ranges for the retinal nerve fiber layer, macula, and retinal layer thicknesses in children. *Am J Ophthalmol* 155: 354-360e1.
23. Wang J, Smith HA, Donaldson DL, Haider KM, Roberts GJ, et al. (2014) Macular structural characteristics in children with congenital and developmental cataracts. *J AAPOS* 18: 417-422.
24. Wang J, Spencer R, Leffler JN, Birch EE (2012) Critical period for foveal fine structure in children with regressed retinopathy of prematurity. *Retina* 32: 330-339.
25. O'Brien S, Wang J, Smith HA, Donaldson DL, Haider KM, et al. (2015) Macular structural characteristics in children with Down syndrome. *Graefes Arch Clin Exp Ophthalmol* 253: 2317-2323.