

Case Report

Open Access

Miller Fisher Syndrome – An Atypical Clinical Presentation

Venkata Umakant Kodali¹, Seshulakshmi Borra² and Srinivasa Rao Bolla^{3*}

¹Associate Professor, Department of General Medicine, Mamata Medical College, Khammam – 507001, Andhra Pradesh, India

²Associate Professor, Department of Radiodiagnosis, Mamata Medical College, Khammam – 507001, Andhra Pradesh, India

³Associate Professor, Department of Anatomy, Mamata Medical College, Khammam – 507001, Andhra Pradesh, India

Introduction

Miller Fisher Syndrome (MFS) is an acquired disease of nervous system which is considered as a rare variant of Guillain-Barré Syndrome (GBS). Collier first described in 1932 as a variant of the Guillain-Barre syndrome with the triad of ataxia, areflexia and ophthalmoplegia. Charles Miller Fisher in 1956 described 3 patients with the symptoms of sluggish pupillary reflexes, acute external ophthalmoplegia, ataxia and areflexia [1], who were recovered spontaneously. MFS also has rarer variants. Here we are presenting a case of MFS having distal paresthesias, weakness of all four limbs, ptosis along with ataxia, areflexia, ophthalmoplegia conservatively managed. The patient gradually improved in symptoms including power, ataxia, ophthalmoplegia without intravenous immunoglobulin. After 20 days the patient was discharged from hospital with complete recovery.

Case Report

A 47 year old male presented to the department of General Medicine of Mamata Medical college with sudden onset of generalized weakness, distal paresthesias of all four limbs, bilateral drooping of eyelids and double vision for past 2 days (Figure 1). Ptosis is not of fatigable type and there was no diurnal variation. After two days of admission, he developed unsteadiness of gait, while walking he had tendency to fall on either side and was able to walk only with support. His imbalance was not proportionate to weakness. There was no history of fever, headache, loose motions and upper respiratory tract infections in the past one month. There was no history of bladder and bowel incontinence. There was no recent history of trauma, drug abuse, alcohol addiction and vaccination.

General physical examination was normal with stable vitals. On neurological examination higher psychic functions were normal. Cranial nerve examination revealed bilateral complete external ophthalmoplegia with ptosis was present which neither exaggerated on fixing of gaze upward nor improved with neostigmine. There was no nystagmus, optic fundus was normal. On motor system examination, muscle tone decreased in both lower limbs power is 4/5 in both lower limbs and normal in upper limbs. There was no muscular wasting / atrophy, involuntary movements are not present. In all four limbs deep tendon reflexes are absent, plantars were flexors bilaterally. Sensations like thermal, pain and touch were normal. In lower limbs Joint position sense and vibration sense were affected. Rombergs test was positive. He had ataxic gait with grossly impaired Tandem walking and tendency to fall on either side. Finger nose test and other cerebellar signs were normal.

His routine investigations are normal. CT brain, thyroid function tests and Ach-R activity by radioimmuno assay were normal. CSF Analysis has shown 15 cells, predominantly lymphocytes, protein 220 mg%, albuminocytological dissociation present. Nerve conduction study showed sensory motor axonal neuropathy with more of sensory involvement.

As the patient shown triad symptoms of MFS - ataxia, areflexia, ophthalmoplegia and weakness of lower limbs, clinically he was diagnosed to have Miller Fisher variant of GBS. Nerve conduction

study supported our clinical diagnosis. Patient had shown gradual improvement in symptoms including power, ataxia, ophthalmoplegia without intravenous immunoglobulin. After 20 days the patient was recovered completely (Figure 2).

Discussion

GBS is a type of neuromuscular paralysis presented as acute idiopathic polyneuritis which has several variants. MFS was found 1% to 5% of all cases of GBS in Western countries [2], whereas it is 19% in Asian countries [3]. Berlit et al. in their review of 223 cases of MFS described that the first symptom observed was diplopia (38.6%) or ataxia (20.6%). In 81.6% areflexia was present [4]. Cranial nerves



Figure 1: At the time of admission.

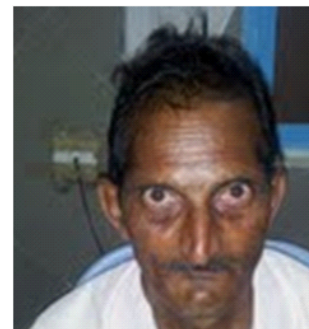


Figure 2: After recovery.

***Corresponding author:** Srinivasa Rao Bolla, Associate Professor, Department of Anatomy, Mamata Medical College, Khammam – 507001, Andhra Pradesh, India, Tel: +91 9440047894; Fax: +91 8742 234306; E-mail: bolla.srinivas@gmail.com

Received February 18, 2013; **Accepted** February 27, 2013; **Published** March 04, 2013

Citation: Venkata Umakant K, Seshulakshmi B, Srinivasa Rao B (2013) Miller Fisher Syndrome – An Atypical Clinical Presentation. Intern Med 3: 119. doi:10.4172/2165-8048.1000119

Copyright: © 2013 Venkata Umakant K, et al. This is an open-access article distributed under the terms of the Creative Commons Attribution License, which permits unrestricted use, distribution, and reproduction in any medium, provided the original author and source are credited.

involvement other than III cranial nerve was found in 127 cases (56.9%). Most commonly involved are VII, IX, X and XII cranial nerves [4]. In the present case III, IV and VI Cranial nerves are involved.

Symptoms in common with GBS include rapid onset, generalized areflexia, albuminocytological dissociation in CSF. Basic difference is lack of weakness. In the present case limb weakness and ptosis were seen with above findings. Acute phase Immunoglobulin G (IgG) antibodies to GQ1b ganglioside is a specific serum marker for MFS [2]. In over 90% of cases of MFS anti GQ1b IgG antibodies are found [3] and its role in pathogenesis of MFS, especially ophthalmoplegia was described [5]. Antibody appears in 80% patients peaking over 1st week, albuminocytological dissociation in CSF later [5].

Higher level of sensory and CNS involvement is seen in MFS. The peripheral mismatch between proprioceptive input from muscle spindles and kinesthetic information for joint receptors results in ataxia [6,7]. Motor damage in the cranial nerves axonal neuropathy with predominant sensory nerve changes in the limbs was found in typical MFS [8]. This study supports the nerve conduction study finding of our case. Reduced sensory nerve action potentials and absent H reflexes are the most common electrophysiological findings, more variability is observed with F waves and CT or MRI [5].

With a common tie of the GQ1b antibody different variants are present. Combined features of GBS and MFS in which oculomotor disturbance and limb weakness occurring within few days of one another (GBS Overlap variant) was observed in some cases. Recurrence of MFS also reported rarely [9]. Lower cranial nerve variants of GBS and atypical MFS were also reported [10].

MFS is a benign condition which is self-limiting. MFS has a good prognosis. Recovery usually occurs in 10-20 weeks; residual symptoms were present in 33.2%, recurrence in 7% patients [4]. It was reported in the largest published case series of MFS that all the 28 patients returned to normal activities by 6 months after the neurological onset. The median (range) period for neurological onset is 32 (8-271) days and the disappearance of ataxia and ophthalmoplegia was 88 (29-165) days. However, cases progressing to respiratory failure and requiring mechanical ventilation have also been described, particularly in children. Other serious complications reported include coma, ballism,

cardiomyopathy from dysautonomia, lactic acidosis, and pain [11]. In the present case patient was managed conservatively. Over a period of 20 days, he gradually improved including power, ataxia followed by ophthalmoplegia without any residual symptoms.

MFS is a relatively uncommon condition. High clinical suspicion is needed to diagnose MFS because all symptoms may not appear at the same time. Though uncommon, respiratory failure is possible in MFS. It is necessary to rule out other clinical conditions with rapid onset of ophthalmoplegia and ataxia, such as brainstem stroke, Wernick's encephalopathy, Bickerstaff brainstem encephalitis and also other acute painful ophthalmoplegias such as bilateral cavernous sinus thrombosis, Tolosa-Hunt syndrome and superior orbital fissure syndrome before the clinical diagnosis of MFS in Primary health care setups.

References

1. Santra G, Datta AK (2008) Miller Fisher syndrome—an uncommon clinical presentation. *J Assoc Physicians India* 56: 898-900.
2. Arnason GBW (1993) Acute inflammatory demyelinating polyneuropathy. *Peripheral neuropathy*. (3rd edn). Philadelphia: Saunders 1437-1497.
3. Mori M, Kuwabara S, Fukutake T, Yuki N, Hattori T (2001) Clinical features and prognosis of Miller Fisher syndrome. *Neurology* 56: 1104-1106.
4. Berlitt P, Rakicky J (1992) The Miller Fisher Syndrome. Review of the literature. *J Clin Neuroophthalmol* 12: 57-63.
5. Arányi Z, Kovács T, Sipos I, Bereczki D (2012) Miller Fisher syndrome: brief overview and update with a focus on electrophysiological findings. *Eur J Neurol* 19: 15-20, e1-e3.
6. Santra G, Datta AK (2008) Miller Fisher Syndrome- an uncommon clinical presentation. *J Assoc Physicians India*. 56: 898-900.
7. Shahani BT, Rooper AH (1982) Mechanism of ataxia in Fisher syndrome. *Ann Neurol* 12: 77.
8. Fross RD, Daube JR (1987) Neuropathy in the Miller Fisher syndrome: clinical and electrophysiological findings. *Neurology* 37: 1493-1498.
9. Sitajayalakshmi S, Borgohain R, Mani J, Mohandas S (2002) Recurrent Miller fisher syndrome: a case report. *Neurol India* 50: 365-367.
10. Ter Bruggen JP, Van Der Meche FG, De Jager AE, Polman CH (1998) Ophthalmoplegic and lower cranial nerve variants merge into each other and into classical Guillain Barre Syndrome. *Muscle Nerve* 21: 239-242.
11. Lo YL (2007) Clinical and immunological spectrum of the MillerFisher syndrome. *Muscle Nerve* 36: 615-627.