

## Migrated Intravesical Foreign Bodies: A Five Year Review

Vinod Priyadarshi<sup>1\*</sup>, Nidhi Sehgal<sup>2</sup>, Anurag Puri<sup>1</sup>, Jitendra Pratap Singh<sup>1</sup>, Malay Kumar Bera<sup>1</sup> and Dilip Kumar Pal<sup>1</sup>

<sup>1</sup>Department of Urology, IPGMER and SSKM Hospital, Kolkata-20, India

<sup>2</sup>Consultant Radiologist, NG Medicare, Kolkata-20, India

\*Corresponding author: Priyadarshi V, Department of Urology, IPGMER and SSKM Hospital, Kolkata-20, India, Tel: + 91 9903431047; E-mail: vinod\_priyadarshi@yahoo.com

Received date: Jul 15, 2016; Accepted date: Aug 03, 2016; Published date: Aug 10, 2016

Copyright: © 2016 Priyadarshi V, et al. This is an open-access article distributed under the terms of the Creative Commons Attribution License, which permits unrestricted use, distribution, and reproduction in any medium, provided the original author and source are credited.

### Abstract

**Introduction:** Migratory foreign bodies make a separate group of intravesical foreign bodies and any object in vicinity of bladder may migrate into it.

**Material and methods:** Retrospective analysis of migratory intravesical foreign bodies which were treated over last five year, done and discussed with the available literature.

**Results:** Different foreign bodies reported to migrate into the bladder through different route. In most of the cases, they present with minimal lower Urinary Tract Symptoms (LUTS) which are often ignored by patients and clinicians; and it is the haematuria which draw medical attention. With time they encrustate into stone but rarely seen to migrate further.

**Conclusion:** Almost any foreign body in lower abdomen may migrate into urinary bladder through almost any possible route, from where they rarely migrate further. Bladder remains as an ideal receptacle to retain them for long with encrustation.

**Keywords:** Foreign body; Urinary bladder; Intravesical; Migration

### Introduction and Objectives

A variety of foreign bodies have been reported to be lodged in urinary bladder and the most are self-inserted by the patient itself out of curiosity or autoerotic stimulation or as a complication of a surgical procedure or instrumentation [1,2]. History itself is very suggestive of diagnosis in most of such cases. Unlike these self inflicted or post instrumentation foreign bodies, there are conditions where objects reach into the bladder following migration from the vicinity which used to be highly unpredictable. Presentation in such cases is often delayed and confusing. We are discussing here nine cases of five different foreign bodies; each migrated from a different route into the bladder.

### Patients and Methods

Hospital records of patients who were treated for intravesical foreign bodies over last three years were retrospectively obtained and those patients, who had evidence of foreign body migration to bladder were selectively analysed and available literature over in situ migration of foreign bodies reviewed.

### Results

A total 18 patients of intravesical foreign bodies were treated over last five years. Six patients who had self inflicted foreign bodies in bladder along with urethra and three patients, who had retained Foleys bulbs and catheter fragments, were excluded from the study and rest

nine patients (50%), who had migrated foreign bodies were selectively analysed.

First case was a 9-year-old child who had single episode of haematuria and suprapubic pain since one month. He had history of sewing needle prick on posterior aspect of left thigh 4 years back (Figure 1) and undergone two failed explorations of thigh (Figure 2), for the same. X-ray KUB and IVU confirmed that needle had migrated to the bladder and encrusted into a bladder stone (Figure 3). After cystoscopic confirmation, cystolithotomy done.

Second case was a 31-year-old women who came with a sudden episode of haematuria though she had LUT symptoms for six months. Apart from UTI, she had a triangular-shaped bladder-stone over a T-shaped radio opaque shadow on X-Ray KUB. She had a history of IUCD insertion 7 years back and she became pregnant 3 years thereafter. Suggesting that the IUCD may have dropped, no attempt was made by her caregiver to locate the device at any time. Cystolithotomy was done to remove the stone in total to avoid any residual fragment of copper-T device.

Third case was 28-year-old male, who had recurrent episodes of haematuria, supra pubic pain and fever since one month. He also had history of recurrent episodes of dysuria which he ignored. Along with other investigations, x-ray KUB was obtained which show coiled wire loops in suprapubic region. USG suggested stone in bladder. When patient was asked again about the coiled wires, an alleged history of assault and forceful insertion of electric wire in his rectum 6 years back, came into the knowledge. But the patient also claimed that he had defecated out the wire very next day and remained symptomless except mild pain in anal region for a few days. Patient didn't approach for any medical assistance out of shame. Sigmoidoscopy was negative.

Cystoscopy confirmed encrusted coiled wire loops in bladder which was removed by cystolithotomy.

Fourth case was a male of 32 years, who had few episodes of painless terminal haematuria since last 3-4 weeks. He had history of fire arm injury in lower abdomen and a bullet was lodged in right groin which was could not be located during primary exploration. Serial X-rays were consistent with the presence of bullet in pelvic cavity. Fresh x ray KUB obtained and this time bullet was seen to migrate to the suprapubic region. Cystoscopy confirmed presence of encrusted bullet in bladder which was removed by cystolithotomy.

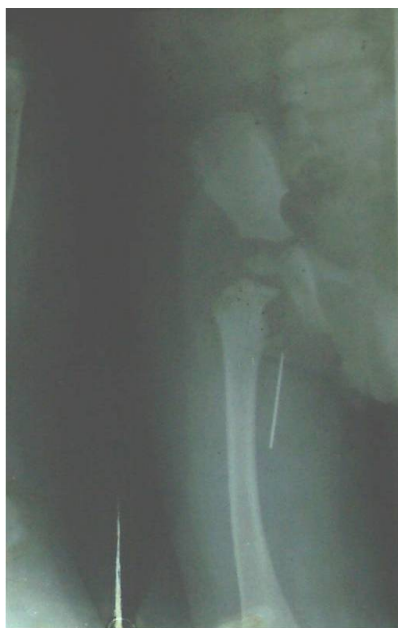

Figure 1: Previous X-ray of case-1, showing needle in thigh.

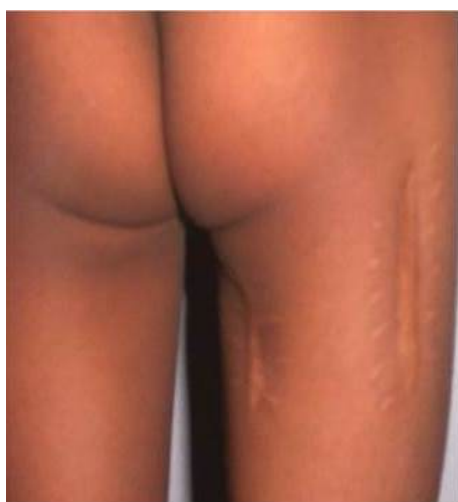


Figure 2: Showing Scar marks in thigh for previous exploration.

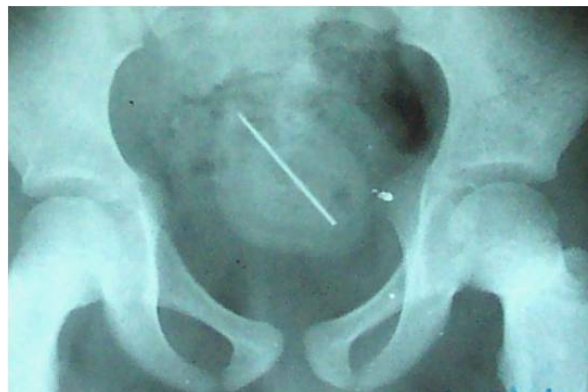

Figure 3: X-ray showing same needle migrated from thigh into the bladder.

Fifth case was a 36 year old woman who was referred for intermittent left flank pain and her USG was suggestive of Left hydronephrosis and hydroureter up to distal ureter along with an IUCD in bladder which was fixed at vesicouterine junction (VUJ).

On IVU, left kidney was poorly excretory and left ureter was poorly traceable due to impinged IUCD. Cystoscopy confirmed an impinged IUCD at left VUJ which was removed; bladder and uterus repaired separately with O'Connor technique and procedure completed with suprahialal ureteroneocystostomy (Paquin technique).

In sixth case, there was recurrent pyuria, dysuria and few episodes of terminal haematuria for six months in a 33 year old female. She had h/o Manchester repair 4 years back for uterine prolapse. USG was suggestive of heterogeneous mass in the trigonal area of bladder while cystogram of IVU series suggested filling defect in bladder (Figure 4). But on cystoscopy, it was actually a piece of gauze with surrounding sloughed ulcer in trigonal area. Foreign body was removed cystoscopically and the recovery was uneventful.

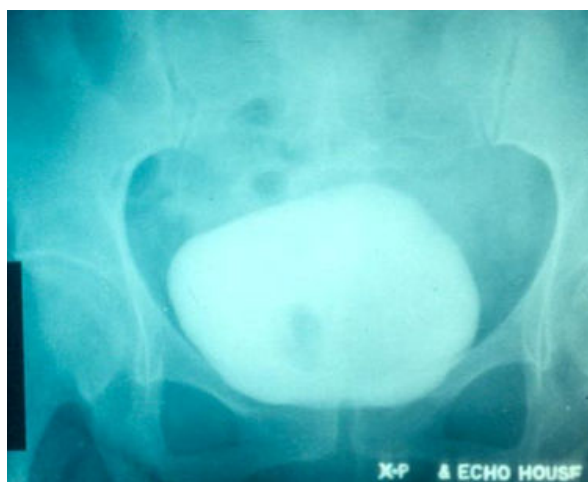

Figure 4: showing intravesicle migrated guagepiece as space occupying lesion.

Seventh case was again a case of IUCD in bladder in a 29 year old lady who had secondary amenorrhea for 2 month. She had no other symptoms. Her urine test and USG were negative for pregnancy. But the same USG was suggestive of a copper -T in bladder lumen which was inserted 3 years back. X-Ray KUB and cystoscopy was done. The IUCD removed through suprapubic 10 mm intravesical laparoscopic port under cystoscopic guidance.

Eighth case had encrusted prolene sutures wandering in the bladder lumen which were found during cystoscopy in diagnostic workup for LUTS in a 62 year old male who had right side herniorrhaphy 5 years back. Sutures were removed endoscopically and the recovery was uneventful.

Ninth case had an encrusted electric wire coiled in bladder which was actually introduced in urethra 4 years back out of sexual eroticism

and patient lost grip over it during erection of penis. Though this patient used to have mild discomfort in micturition thereafter, he reported for medical attention only after 4 years when he developed acute retention of urine. X-ray showed encrusted electric coil, which was removed cystoscopically after fragmenting it with lithoclast.

Interestingly, there was a long history of in-situ presence for foreign body in each of these cases with minimal symptoms and none presented with fistulae. The symptoms were mostly ignored at first and it was haematuria or the retention which drawn the medical attention. Three out of four females had IUCD as a foreign body and all these patients were not informed about to check threads intermittently and to alarm on “missing of threads”.

Clinical presentation, nature of migrant foreign body and treatment extended has been summarised in Table 1.

Case	Symptoms at presentation						Active UTI	Foreign body profile		Treatment	
	Age	Sex	LUTS	Haematuria	Pain	Symptom duration		Duration	Original Site	Nature	
1	9 y	M	+	One episode	+	1 month	-	4 yr	Left Thigh	Sewing needle	Cystolithotomy
2	31 y	F	+	One episode	+	6 month	+	7 yr	Uterus	IUCD	Cystolithotomy
3	28 y	M	+	+	+	1 year	+	6 yr	Rectum	Coiled Wire	Cystolithotomy
4	32 y	M	-	+	-	1 month	-	5 yr	Right groin	Bullet	Cystolithotomy
5	36 y	F	+	-	+	5 month	-	4 yr	Uterus	IUCD	Open removal and repair with ureteric reimplantation
6	43 y	F	+	Few episodes	+	5 month	+	4 yr	Peritoneal/extra peritoneal?	Gauze	Retrieval through intravesical laparoscopic port
7	29 y	F	+	-	+	2 month	+	2 yr	Uterus	IUCD	Retrieval through intravesical laparoscopic port
8	62 Y	M	+	-	+	3 year	-	5 yr	Right groin	Non-absorbable sutures	Cystoscopic retrieval
9	28 y	M	+	One episode	-	3 year	+	4 yr	Urethra	Coiled wire	Cystoscopic retrieval

**Table 1:** showing clinical summary.

## Discussion

Intravesical foreign bodies are an important consideration in the differential diagnosis of lower urinary tract symptoms [1]. Usually, the urinary bladder lies deep in the pelvis and it is inaccessible for the introduction of foreign bodies into it, but surprisingly, so far, diverse objects have been recovered from the bladder [2]. Literature suggests almost any conceivable object has been introduced in to the urinary bladder [1]. Over the years, incrustations develop around these foreign bodies and they present as bladder calculi.

These foreign bodies are categorized into three subgroups based on the mode of their entry into the bladder [1,2].

### Type 1

Self introduced for sexual gratification or attempted abortion [3] or as consequences of psychiatric illness or under effect of drugs.

### Type 2

Iatrogenic, where the foreign body is inadvertently left behind in the bladder at the time of a major bladder surgery or during transurethral endoscopic instrumentation or catheterization.

### Type 3

Migratory type, where they may usually migrate from the uterus, rectum, pelvis and vagina. Almost any foreign body lying around the urinary bladder has got a potential of migration into the bladder [2].

Symptoms of intravesical foreign bodies are usually those of acute cystitis including urinary frequency, dysuria, hematuria, and strangury. Some patients may present with swelling of the external genitalia, poor urinary stream, and urinary retention. More importantly, patients occasionally present with no symptoms or complaint of minimal discomfort [1].

Migratory foreign bodies in bladder needs a separate discussion here as unlike other 2 types, suggestive history is often missing, presentation is often delayed and confusing while diagnoses mostly taken as surprise. Apart from types of foreign bodies reported in this study (needle, bullet, electric wire, IUCD), a variety of other objects have been reported to migrate into the urinary bladder from the surrounding pelvic organs, including vaginal pessary, artificial urinary sphincter, prosthetic slings and TVT tapes, nonabsorbable sutures and tacks used in Stamey procedures and Burch colposuspension, surgical gauze and orthopaedic screws and wires [1,2,4-6]. Even a major group of self-inflicted foreign bodies which were actually inserted in distal and bulbar urethra, further migrate into bladder by involuntary perineal muscle contact and could not be retrieved by the patient itself.

Chicken and fish bones, pins and needles, pencil, rectal thermometer, toothpicks were reported to migrate into the bladder via gastrointestinal tract. IUCD requires a special mention here as it is one of the most commonly used foreign bodies in a female. A physician should give clear instructions to the recipients regarding periodic check of threads and to alarm once they found it missing which may be an early sign of migration. Apart from IUCD, pessaries and lippis loop, other foreign bodies may perforate the bladder via vagina, mostly as a result of masturbation injuries [7]. Or after an assault or in psychiatric population. Bodenbach and Riaz reported the intravesical migration of polypropylene mesh which was used for hernia repair [2]. Even a transvesical migration of distal end of ventriculoperitoneal shunt has been reported [2]. And as much we know, migration of sewing needle from thigh to bladder described in this study is first of such kind of migration reported so far.

Mechanism of such migration mostly remain obscure. Various theories have been proposed, including muscular activity, respiratory excursion, capillary action, electrolysis, local bone resorption secondary to prolonged implantation, gravitational forces, the great freedom of motion of an extremity and fracture non-union [8]. IUCD migrations are partially explained by probable uterine perforation primarily at the time of insertion in undetected extreme posterior uterine position. This risk increases especially during the puerperium, recent abortion or MTP, following cesarean section, in sepsis and in multipara [9]. Foreign body in vicinity causes constant irritation and slowly erode through bladder wall and this process is augmented by muscular contractions of bladder such that even soft foreign bodies like surgical gauze and sponge make their way into the bladder [2]. Being capacious, highly vascular and muscular organ, bladder retain such migrant bodies as an ideal receptacle without producing much symptoms and sometimes silently. A prolonged stay in bladder leads to encrustation of these migrated foreign bodies which later present as stones. Theoretically there is always a possibility of fistula formation,

but due to high vascularity of bladder and dense fibrosis due to foreign body itself, it is rarely seen.

Once in the bladder, foreign bodies are rarely seen to migrate further. Though bladder tries to evacuate them per urethra with micturition [4], a contrary migration of an intravesical foreign body to vicinity organ is quite uncommon and there is only one such report in English literature where a self inflicted intraviscle foreign body migrated into the retroperitoneum [7]. Urinary bladder, as such works as an ultimate destination in lower abdomen and pelvis, where most of these foreign bodies migrate to lodge and rarely move further.

The symptoms are usually underestimated, and the patients are usually treated for urinary tract infection without any imaging investigation being carried out. Only when symptoms assume serious proportions, the patient undergoes further investigations. Hence, it would be prudent to carry out a simple investigation like a plain X-ray in patients who have any positive history or having recurrent lower urinary tract symptoms. An X-ray and USG examination of the pelvis are enough to arrive to the diagnosis. If a foreign body is found to involve more than one organ at the same time on USG, a CT scan should be done to study the exact site, size, and the pathway of the fistulous track caused by the migrating foreign body in order to plan optimum treatment [9]. Laboratory investigations will reveal leukocytosis in infected cases, while urine examination will reveal either pus cells or microscopic or gross hematuria depending upon the severity of infection and the irritation caused by it.

Surgery is the mainstay of treatment [1,10] and aimed at providing complete removal of the foreign body with minimal complications [3]. It is a safe practice to administer a course of antibiotics prior to surgical intervention. A preliminary cystoscopic examination is mandatory to chart the course of further intervention [10]. Most foreign bodies in the bladder may be removed either complete or after fragmentation via the endoscopic approach. However, the optimal technique is dictated by the patient's condition, associated urinary tract injuries and size, and shape and nature of the foreign body. Rafique described various reported techniques and cystoscopic modification of intravesical stone retrieval [1]. Though use of Holmium: YAG laser to fragment and facilitate transurethral removal of large intravesical foreign bodies have been described [11,12], but with fragmentation, there is always a possibility of incomplete removal and subsequent recurrence of stone.

In the present study, one IUCD and onegauze were removed under cystoscopic guidance and hydrodistention through 10 mm suprapubic intravesical laparoscopic port as described by Reddy and Daniel [13] but without using carbon dioxide insufflation. Electric wire in one case and sutures in another one case were removed cystoscopically. All other foreign bodies in this study were removed with suprapubic cystolithotomy after preliminary cystoscopy as it allowed complete and safe removal of large, complex, impregnating and potentially injuring foreign bodies and decreases the chance of residual fragments, recurrence of stone and other complications. Only one case required primary bladder repair at the migration site.

### Conclusion

Almost any foreign body in lower abdomen may migrate into the urinary bladder through almost any possible route. Being capacious, vascular and muscular organ, bladder can retain such migrant bodies for a long period without much significant symptoms. Clinical presentation usually occur when they encrustate and form stones.

Migrated foreign bodies make separate entity and requires further longitudinal studies, follow-up of such patients and documentation of experience in removing these migrated bodies, is required.

## References

1. Rafique M (2008) Intravesical Foreign Bodies: Review and Current Management Strategies. *Urol J* 5: 223-231.
2. Mylarappa P, Srikantaiah HC (2011) Calcified Intravesical Gossypiboma Following Abdominal Hysterectomy: A Case Report. *Journal of Clinical and Diagnostic Research* 5: 645-647.
3. Ford SD, Persad RA, Brewster SF, Gingell JC (1992) Intravesical foreign bodies: five year review. *BJU* 69: 41-45.
4. Heetveld MJ, Poolman RW, Heldweg EA, Ultee JM (2003) Spontaneous expulsion of a screw during micturation: an unusual complication 9 years after internal fixation of pubic symphysis diastasis. *Urology* 61: 645.
5. Negoro H, Kawakita M, Imai Y (2005) Intravesical tape erosion following the tension-free vaginal tape procedure for stress urinary incontinence. *International Journal of Urology* 12: 696-698.
6. Salvarci A, Agrali Y (2015) Migration of endotacker into the bladder 7 years after laparoscopic retroperitoneal burch application. *Int Braz J Urol* 41: 382-387.
7. Cury J, Coelho RF, Srougi M (2006) Retroperitoneal Migration of a Self-Inflicted Ballpoint Pen via the Urethra. *International Braz J Urol* 32: 193-195.
8. Fong YC, Lin WC, Hsu HC (2005) Intrapelvic migration of a Kirschner wire. *J Chin Med Assoc* 68: 96-98.
9. Sataa S, Sami BR, Sabeur R, Karim C, Ali H (2011) Bladder calculus resulting from the migration of an Intrauterine Contraceptive Device: A report of ten cases. *Nephro- Urology monthly* 3: 54-61.
10. Ophoven AV, deKernion JB (2000) Clinical management of foreign bodies of the genitourinary tract. *J Urol* 164: 274-87.
11. Wyatt J, Hammontree LN (2006) Use of Holmium:YAG laser to facilitate removal of intravesical foreign bodies. *J Endourol* 20: 672-674.
12. Davis NF, Smyth LG, Giri SK, Flood HD (2012) Evaluation of endoscopic laser excision of polypropylene mesh/sutures following anti-incontinence procedures. *J Urol* 188: 1828-1832.
13. Reddy BS, Daniel RD (2004) A novel laparoscopic technique for removal of foreign bodies from the urinary bladder using carbon dioxide insufflation. *Surg Laparosc Endosc Percutan Tech* 14: 238-239.