

## Management of Postoperative Biliary Fistula After Hydatid Liver Surgery: Are There Any Differences between Localizations?

Gokhan A<sup>1</sup>, Ali K<sup>1</sup>, Bora K<sup>2</sup>, Soykan A<sup>3</sup>, Mustafa K<sup>1</sup>, Emin G<sup>2</sup>, Halil A<sup>1</sup>, Servet K<sup>2</sup>, Sebahattin C<sup>4\*</sup> and Özgür K<sup>4</sup>

<sup>1</sup>Department of Surgery, Bakırköy Dr. Sadi Konuk Training and Research Hospital, Istanbul

<sup>2</sup>Department of Surgery, Okmeydanı Training and Research Hospital, Istanbul

<sup>3</sup>Department of Surgery, Istanbul Training and Research Hospital, Istanbul

<sup>4</sup>Department of Surgery, Yüzüncü Yıl University Medical Faculty, Turkey

\*Corresponding author: Sebahattin Celik, Department of General Surgery, Yüzüncü Yıl University Faculty of Medicine Van, Turkey; Tel: +90 505 705 79 57; E-mail: scelik@yyu.edu.tr

Rec date: Jan 24, 2016; Acc date: Mar 04, 2016; Pub date: Mar 15, 2016

Copyright: © 2016 Gokhan et al. This is an open-access article distributed under the terms of the Creative Commons Attribution License, which permits unrestricted use, distribution, and reproduction in any medium, provided the original author and source are credited.

### Abstract

#### Objectives

The most common complication of hepatic hydatid cysts is the intra-biliary rupture seen approximately in 10-30% of patients. This complication mainly seen in the centrally localized, large hydatid cyst operations. The aim of this study is to compare managements of postoperative biliary fistula after hydatid liver surgery, according to localization of hepatic cyst.

#### Method

A total of 156 patients who underwent surgery for hydatid cyst localized to the liver and presented with persistent drainage of bile from drain after surgical intervention, were included in this prospective study. All the patients were done ERCP procedure because of external biliary fistula after hydatid liver surgery. Patients divided in two groups according to cyst localization in liver. Group 1 (n=96) right side localized cysts, group 2 (n=60) left side-localized group.

#### Results

Closure time of the external biliary fistula was significant differences between group 1 and group 2 (19 days in group 1 and 25 days in group 2, p<0.05). Mean daily fistula output was 294cc (range 100-800 cc) in Group 1, 351 cc (range 200-1000 cc) in Group 2, respectively. The daily fistula output was higher in group 2 than in group 1 p<0.05. In group 1 multiple cysts was more than in group 2.

#### Conclusions

We suggest to perform earlier ERCP procedure, if localization of hydatid cyst is in the central and fistula output is >300 ml/day. The left lobe located hydatid cysts with external biliary fistula take more time to close than those located in the right lobe.

**Keywords:** ERCP; Liver hydatid cyst; Intra-biliary rupture; Biliary fistula; Liver surgery

### Introduction

The establishment of a connection between the cyst cavity and the biliary ducts is one of the commonly encountered complications that create difficulty with the diagnosis and treatment. In patients with hydatid disease, occult intra-biliary rupture is seen in 10.3% to 37.2%, and frank intra-biliary rupture is observed in 3.2% to 17% of patients [1,2]. After hydatid surgery, fistula can occur owing to two main reasons as follow; first, a communication between the cyst and the biliary system is missed at operation and is not directly secured. Second, and rarely, the presence of hydatid material within the biliary

tract causes biliary ductal obstruction, resulting in a persistent biliary fistula that is relieved only when the hydatid material passes or is removed. Although there is some consensus on the medical and surgical treatment of hydatid cyst disease, the treatment of postoperative external fistula still remains controversial [3,4]. Endoscopic retrograde cholangiopancreatography (ERCP) is indicated if cystobiliary communication is found clinically or on laboratory testing. Cholangiography may show cystobiliary fistula, cyst materials in the bile ducts, compression of the bile ducts by the cyst, and bile duct dilatation. Cyst membrane or daughter cysts that escape into the bile ducts can be retrieved through ERCP. Endoscopic sphincterotomy (ES) with or without a nasobiliary drain or biliary stent may alleviate the pressure in the bile ducts, preventing bile reflux into the cyst [5-7].

Some clinical factors, laboratory and radiologic findings associated with an intrabiliary rupture of a cyst can be useful in establishing the proper diagnosis and management. There are some diagnostic problems before surgery for patients with intrabiliary rupture of hydatid cyst. Elevated some laboratory findings are showed that risk factors for these patients. In currently, despite efforts to prevent postoperative biliary fistulas during surgery, some patients continue to experience this undesirable complication. The question is that any significant differences between left and right hepatic lobes at the localization of hepatic cyst effect on biliary fistula. The other question, what should be done for postoperative biliary fistula? The aim of in this prospective study was to compare the results of management between right/ left lobes and central/peripheral localized postoperative biliary fistula after hydatid liver surgery and to present our treatment modality.

## Materials and Methods

Three surgical research institutions took part in this multicenter prospective study between 2004 and 2013. A total of 156 patients who operated liver hydatid cyst and presented with persistent drainage of bile from lodge drain after surgical intervention were included in this study. Patients divided in two groups according to cyst localization in liver. Group 1 (n=96) right side localized cysts, Group 2 (n=60) left side localized group. A postoperative persisting bile leak was described as the continuous bile discharge from lodge drain after 10 days [8]. The patient records were reviewed, and the data results were recorded on a standard form. This included age, sex, location, whether the cyst was primary or recurrent, cyst number (single or multiple), cyst size, daily fistula output, stages according to Gharbi's classification [9], time to closure of the biliary fistula, complications, mortality, laboratory and radiologic findings. All patients underwent a full blood cell count, liver function tests (alkaline phosphatase-ALP,  $\gamma$ -glutamyl transferase-GGT, alanine aminotransferase-ALT, aspartate aminotransferase-AST, lactate dehydrogenase-LDH, total bilirubin and direct bilirubin) before surgery. Diagnosis was detected by ultrasonography and computed tomography. Postoperative mortality was defined as death occurring in the time prior to discharge from the hospital. Fistula with an output above 300ml/d was described as high output [4]. ERCP procedure was done for all patients because of biliary fistula after surgery. In addition to this conditions liver hydatid cyst were evaluated for peripheral and central location according to fistula flow and the time of fistula closure.

## Statistical analysis

Data were analyzed by using SPSS for Windows 15.0. Results are presented as mean (standard deviation) and frequencies (percent). Student's t and Mann Whitney U tests were used to evaluate the differences between groups for measured variables and the chi square/ Fischer's exact test were used for categorical variables. A p value less than 0.05 were considered significant.

## Results

A total of 156 patients who underwent surgery for hydatid cysts localized to the liver and persistent drainage of bile were included in this study. All surgeries were conservative, including unroofing of the cyst by partial pericystectomy and cavity management. There were 96 patients in group 1 and 60 patients in group 2. Patient demographics and postoperative clinical outcomes are outlined in Table 1. Of the 156

patients, 140 patients had single cyst and the remaining 16 patients had multiple cysts.

	Group 1 (n=96) (Right Lobe)	Group 2 (n=60) (Left Lobe)	P
Age (years)	41.7(16-75)	43.4 (18-80)	p>0.05
Gender (F/M)	46/50	23/37	p>0.05
Fistula Closure time (day)	19(5-98)	25 (4-90)	p<0.05
Fistula output (ml)	294cc (100-800)	351cc (200-1000)	p<0.05
Complications*	4	2	-
Mortality	0	0	-

**Table 1:** Patient characteristic and postoperative clinical situations.\*Complications: 5 mild bleeding, 1<sup>st</sup> ent dislocation

Cyst Features	Group 1 (n=96)	Group 2 (n=60)	Overall	P
<sup>1</sup> Cyst size (cm)	9.5(6-20)	8.6 (5-15)		p>0.05
Single	84	56	140	
Multiple	12	4	16	p<0.05
Primary	85	53	138	p>0.05
Recurrent	11	7	18	p>0.05
<sup>2</sup> Classification of Hydatid Cyst				
Type 1	2	-	2	
Type 2	20	13	33	
Type 3	41	26	67	
Type 4	33	21	54	
Type 5	-	-	-	

**Table 2:** Features and classification of the hydatid cyst in 156 patients. Note: <sup>1</sup>In patients with multiple cysts, the biggest cyst was considered for localization and cyst size, <sup>2</sup>According to Gharbi's classification

In group 1 multiple cysts was more than in group 2. There were significant differences between the groups p<0.05. The total number of cysts was 182 in 156 patients. Moreover, 138 patients had primary cyst and the rest 18 patients had recurrent cyst. The liver is divided into two lobes according to Couinaud's nomenclature [10]. The cysts were located mostly in the right lobe (96 patients), followed by the left lobe (60 patients). In group 1 cyst size mean 9.5 cm (min 6- max20) and in group 2 cyst size 2 mean 8.6 (min 5- max 15). While 144 (92%) patients had single cyst, 12 patients (8%) had multiple cysts. Features and classification of the hydatid cyst in 156 patients were presented in Table 2. Our data shows that the most laboratory findings were ALP and GGT levels associated with intra-biliary rupture. The level of ALP was high in group 1 55 patients (57.3%), in group 2 48 patients (80%) and GGT was found high in group 1, 30 patients (31.2%), in group 2, 21 patients (35%). When compared the groups for ALP level, in group 2 higher than in group 1 (p<0.05). The patients preoperative radiologic and laboratory finding data is given in Table 3. In addition, we

compared liver cyst localization of patients according to peripheral and central placed. While Mean fistula closure time 15 days in peripheral posterior group, 21 days in peripheral lateral group. On the other hand central anterior and central medial groups fistula closure time were 20 days and 28 days, respectively. There were significant differences between the groups  $p < 0.05$ . When we compare the groups for fistula output and cyst size we could not determine significantly differences in each group. The data is given in Table 4.

Laboratory Factors	Group 1 (n=96)	Group 2 (n=60)	P
ALT level>55U/L	10 (10.4%)	8 (13%)	$p > 0.05$
AST level>37U/L	8 (8.3%)	6 (10%)	$p > 0.05$
ALP level>120U/L	55(57.3%)	48 (80%)	$p < 0.05$
GGT level>50U/L	30 (31.2%)	21 (35%)	$p > 0.05$
Total bilirubin level>1.2mg/dl	9 (9.4%)	7 (11.7%)	$p > 0.05$
Direct bilirubin level>0.2mg/dl	8 (8.3%)	6 (10%)	$p > 0.05$
<b>Radiologic Findings</b>			
Dilated intrahepatic bile duct	26 (27%)	17 (28.3%)	$p > 0.05$
Dilated right + left intrahepatic bile duct	3 (3.1%)	4 (6.6%)	$p > 0.05$
Dilated extrahepatic bile duct	11 (11.5%)	8 (13.3%)	$p > 0.05$
Dilated intrahepatic+extrahepatic bile duct	14 (14.6%)	9 (15%)	$p > 0.05$
Overall	54 (56.3%)	37 (61.6%)	$p > 0.05$

**Table 3:** Performance of laboratory and radiologic factors associated with intrabiliary rupture according to preoperative assessment.

Localization	Peripheral		Central		P
	Group 1 Posterior (n=29)	Group 4 Lateral (n=14)	Group 2 Anterior (n=67)	Group 3 Medial (n=46)	
Fistula output (ml)1	284cc (100-600)	386cc (100-950)	299cc (80-1000)	342cc (100-700)	$p > 0.05$
Fistula Closure time1 (day)	15 (5-33)	21 (4-90)	20 (5-98)	28 (5-90)	$p < 0.05$
Cyst size (cm)	9,3 (5,5-15)	8,1 (6-12)	9,5 (6-20)	8,9 (5-20)	$p > 0.05$

**Table 4:** Liver cysts compared according to peripheral and central placement.

None of the patients were undergone a preoperative ERCP. Endoscopic sphincterotomy was performed in majority of the patients. Hydatid membranes and daughter cysts were removed with a dormia

basket or balloon, if they were observed during ERCP. Biliary stenting was added mostly in patients with relatively higher fistula output. The overall success rate was 100%. Results of ERCP treatment are given in Table 5. Mean fistula closure time in group 1, 19 days; in group 2, 25 days. There were significant differences between the groups  $p < 0.05$ . Mean daily fistula output was 294 cc (range 100-800 cc) in Group 1, 351 cc (range 200-1000 cc) in Group 2, respectively. The daily fistula output was higher in group 2 than in group 1  $p < 0.05$ . Complications were seen in 5 patients and were mild bleeding [11,12]. All patients were treated medically. In group 2, stent placement was ineffective in 1 patient because of over insertion in the bile duct, stent was withdrawn. No mortality was observed in our study. Major biliary communications between the cyst and the right hepatic ducts were seen in 42 (43.7%) patients and communications with the left hepatic ducts in 31 (51.7%) patients according to ERCP procedure.

	Group 1 (n=96) (Right Lobe)	Group 2 (n=60) (Left Lobe)	Total
Only Sphincterotomy	45	29	74
7F Stent	11	7	18
10F Stent	39	23	62
Nasobiliary Stent	1	1	2

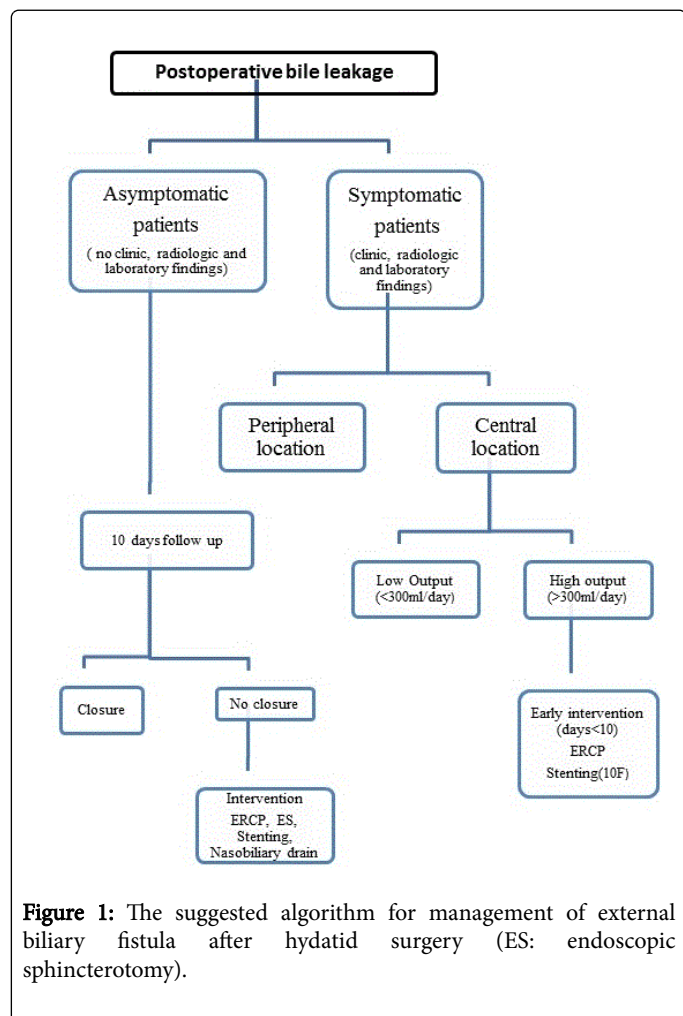
**Table 5:** Results of ERCP treatment in patients with cystobiliary fistula.

## Discussion

Direct communications with bile ducts are usually asymptomatic and result in postoperative biliary fistulas after hydatid liver surgery [13]. Cystobiliary communications that occur after rupture of the cysts into the bile ducts can be minor or major. Minor communications are usually asymptomatic, revealed postoperatively by biliary leakage, whereas major communications cause obstructive jaundice and cholangitis [14]. Although there are so many articles about hydatid disease in the literature, there are limited studies about relationship with cyst localization and treatment option [15-17]. In our study, we analysed postoperative biliary fistula cases after hydatid cyst operations in the last 9 years and we suggested that treatment modality (Figure 1).

Hydatid cysts usually are located in the right lobe of the liver [18,19]. In our study, 96 (61.5%) patients with hydatid cyst localized in the right lobe (group 1), 60 (38.5%) patients with hydatid cyst localized in the left lobe (group 2) of liver. USG is the most suitable method for diagnosis of hydatid cyst. It is helpful for providing essential information about the location, number, size, and type of cysts, the condition of the intrahepatic and extrahepatic biliary system [18,19]. We performed USG and CT in our patients to obtain additional information about the hepatic cyst. In this study, the most common radiologic finding was dilated intrahepatic bile duct in 26 patients (27%) and in 17 patients (28.3%) in group 1 and 2, respectively. If the hydatid cyst localized central of the liver (right anterior and left medial segment), left and right dilated intrahepatic bile duct may seen. Kayaalp et al. [15] in a series of 113 patients showed that the location of the hydatid cyst near the hilum is a risk factor for the development of a cystobiliary communication and cavity-related complications. We found both dilated (left and right lobe) intrahepatic bile duct in group 1, 3 patients (3.1%) and in group 2, 4 patients (6.6%). We thought that total of 91 patients (58%) could be associated with intrabiliary rupture according to radiologic findings preoperatively. However, the size of

the cyst is as important as its localization in the development of biliary-cystic communication [1]. Size of the cyst was recognized as a predictive factor in the development of biliary-cystic communication. In literature, suggested size >10 cm plays a role in occurrence of a cystobiliary communication [20,21].



**Figure 1:** The suggested algorithm for management of external biliary fistula after hydatid surgery (ES: endoscopic sphincterotomy).

Cholestatic enzymes, such as alkaline phosphatase and GGT, can be mildly elevated in about one third of cases, however especially in patients with biliary involvement. Elevated bilirubin levels (>1 mg/dL) with elevated alkaline phosphatase and GGT levels almost always are diagnostic of cystobiliary communications [14]. Atli et al. show that elevated liver function test results (ALT, AST, ALP, GGT, total bilirubin and direct bilirubin levels), a large cyst diameter, the presence of ultrasonographic findings and type 4 cyst on USG were the significant clinical factors associated with the presence of a frank intrabiliary rupture on univariate analysis [22]. We also found that the fistula of the left side localized cysts more persistence to heal than the right side fistulae p<0.05. According to liver anatomy, left intrahepatic bile duct is longer than right intrahepatic bile duct and also left hepatic bile duct placed in parallel to left hepatic lobe. We consider that due to the this anatomic placement, liver hydatid cyst that located on the left lobe (especially segment III and IV) may be major connected with common bile duct, more frequently. In consequence of the shortness of the right common bile duct, the possibility of the major communication with right located cyst hydatid and common bile duct seems lower than the left located cyst hydatid. In addition to this explanation, right common

bile duct split up segmenter bile ducts earlier. In our experience we determined the contrast liquid leakage parallel to main bile duct on the left located cyst hydatid while contrast leakage was seen generally on the seconder bile ducts in right located cyst hydatid. For this reason, we thought that the left located cyst may resistant to spontaneous closure after the liver hydatid surgery.

Surgery is an important treatment option for patients with hydatid disease. Operative options include pericystectomy and hepatic resection or simply unroofing the cyst and treating the residual cavity [16,17]. Postoperative mortality and morbidity of hydatid cyst associated with biliary tract is very high. For that reason it is very important to detect such cyst associated with biliary tract during operation. The first step of the treatment is intraoperative detection of connection with cyst and biliary tract. At this stage, associated biliary tract fistula repair is an important step in preventing the development of postoperative biliary fistula. When the cyst cavity is opened, we can detect connection of biliary tract and cyst by the presence of bile in the cavity or inspections after removal of the daughter vesicles inside the cavity. The second step is management of the biliary fistula after surgery for hydatid cyst. Biliary fistula can be detected by drains which are placed in the operation in the early postoperative period. During the postoperative period, ERCP can help to clarify the causes of ongoing or recurrent symptoms or laboratory abnormalities, may help to resolve the obstruction or cholangitis due to residual material in biliary ducts, and may provide the chance to manage postoperative external biliary fistulae (Level 4, Grade C) [23]. Patients with bile fistula are followed by the amount of leakage. Follow-up time is depends on experience of surgeon and amount of bile leakage. In literature, waiting time for intervention after hydatid surgery with external biliary surgery is 10 days [8]. The optimal endoscopic approach for managing external biliary fistula after hydatid surgery remains unanswered. According to our experience in this and previous studies [24], if localization of hydatid cyst is in the central of liver [anterior segment [5,8], medial segment [4]] and fistula output is >300 ml/day, we suggest early intervention and to place 10F stent into main duct. However, in a study conducted in our clinic observation previously, we compared between sphincterotomy and stents (7F and 10F) on affect of biliary fistula. Stent diameter 10F was found to be proportional to the duration of fistula closure time [24]. Large and centrally located cysts are seen risky for development of biliary fistula. Biliary fistula after hydatid cyst operation usually close spontaneously without any intervention [25,26]. The possibility of closing the fistula is correlated with peripherally located cysts, cyst diameter less than 8 cm and below 300 cc/day of bile leakage. We recommended that early ERCP and stenting should be performed if high fistula output (≤ 300 cc/day) and central localization (both right and left lobe) were observed after hydatid cyst surgery. The suggested algorithm for management of external biliary fistula after hydatid surgery was given in Figure 1.

In conclusion, left lobe placement cysts with external biliary fistula had more persistence to close than right lobe placement cysts after surgery. We suggest to perform earlier ERCP procedure, if localization of hydatid cyst is in the central and fistula output is >300 ml/day. As a result, the choice of the therapeutic modality should depend on patient characteristics and endoscopist's expertise.

### Acknowledgements

We thank to Irmak Bircan to spell check for English.



## References

1. Hamamci OE, Besim H, Sonisik M, Korkmaz A (2005) Occult intrabiliary rupture of hydatid cysts in the liver. *World J Surg* 29: 224-226.
2. Botrugno I, Gruttadauria S, Li Petri S, Cintorino D, Spada M, et al. (2010) Complex hydatid cysts of the liver: a single center's evolving approach to surgical treatment. *Am Surg* 76: 1011-1015.
3. El Malki HO, El Mejdoubi Y, Souadka A, Zakri B, Mohsine R, (2010) Does primary surgical management of liver hydatid cyst influence recurrence? *J Gastrointest Surg* 14: 1121-1127.
4. Demircan O, Baybus M, Seydoglu G, Akinoglu A, Sakman G (2006) Occult cystobiliary communication presenting as postoperative biliary leakage after hydatid liver surgery: Are there significant preoperative clinic predictors? *Can J Surg* 49: 177-184.
5. Cicek B, Parlak E, Disibeyaz S, Oguz D, Cengiz C, et al. (2007) Endoscopic therapy of hepatic hydatid cyst disease in preoperative and postoperative settings. *Digestive Disease and Sciences* 52: 931-935.
6. Bilsel Y, Bulut T, Yamaner S, Buyukuncu Y, Bugra D, et al. (2003) ERCP in the diagnosis and management of complications after surgery for hepatic echinococcosis. *Gastrointest Endoscopy* 57: 210-213.
7. Saritas U, Parlak E, Akoglu M, Sahin B (2001) Effectiveness of endoscopic treatment modalities in complicated hepatic hydatid disease after surgical intervention. *Endoscopy* 33: 858-863.
8. Kayaalp C, Bzeizi K, Demirbag AE, Akoglu M (2002) Biliary complications after hydatid liver surgery: incidence and risk factors. *J Gastrointest Surg* 6: 706-712.
9. Tagliacozzo S (2003) Management of hydatid disease of the liver. In: Poston JG, Blumgard HL, Surgical Management of Hepatobiliary and Pancreatic Disorders. (2nd edition), Martin Dunitz Ltd, London.
10. Blumgart HL, Hann EL (2007) Surgical and radiologic anatomy of the liver, biliary tract and pancreas. In: Blumgart HL (ed) *Surgery of the liver, biliary tract, and pancreas*. (5th edn), Saunders Elsevier, Philadelphia.
11. Freeman LM (2005) Complications of ERCP: prediction, prevention, and management. In: Baron HT, Kozarek R (eds) *ERCP*. Saunders Elsevier, Philadelphia.
12. Ferreira L, Baron HT (2007) Post-sphincterotomy bleeding: who, what, when, and how. *Am J Gastroenterol* 102: 2850-2858.
13. Kayaalp C, Aydin C, Olmez A, Isik S, Yilmaz S (2011) Leakage tests reduce the frequency of biliary fistulas following hydatid liver cyst surgery. *Clinical Science* 66: 421-424.
14. Kayaalp C (2007) Hydatid cyst of the liver. In: Blumgart HL, *Surgery of the Liver Biliary Tract and Pancreas*. (4th edition), Saunders, Elsevier, Philadelphia.
15. Kayaalp C, Bostancı B, Yol S, Akoglu M (2003) Distribution of hydatid cysts into the liver with references to cystobiliary communications and cavity related complications. *Am J Surg* 185: 175-179.
16. Ozmen MM, Coskun F (2002) New technique for finding the ruptured bile duct into the liver cysts: scope in the cave technique. *Surg Laparosc Endosc Percutan Tech* 12: 187-189.
17. Ulualp KM, Aydemir I, Senturk H, Eyuboglu E, Cebeci H, et al. (1995) Management of intrabiliary rupture of hydatid cyst of the liver. *World J Surg* 19: 720-724.
18. Ozaslan E, Bayraktar Y (2002) Endoscopic therapy in the management of hepatobiliary disease. *J Clin Gastroenterol* 35: 160-174.
19. Gourgiotis S, Stratopoulos C, Moustafellos P, Dimopoulos N, Papaxoinis G, et al. (2007) Surgical techniques and treatment for hepatic hydatid cysts. *Surg Today* 37: 389-395.
20. Agaoglu N, Turkyılmaz S, Arslan MK (2003) Surgical treatment of hydatid cysts of the liver. *Br J surg* 90: 1536-1541.
21. Malki OH, Mejdoubi Y, Souadka A, Mohsine R, Ifrine L, et al. (2008) Predictive factors of deep abdominal complications after operation for hydatid cyst of the liver: 15 years of experience with 672 patients. *J Am Coll Surg* 206: 629-637.
22. Atli M, Kama AN, Yuksek NY, Doganay M, Gozalan U, et al. (2001) Intrabiliary rupture of a hepatic hydatid cyst. *Arch Surg* 136: 1249-1255.
23. Dziri C, Haouet K, Fingerhut A, Zauouche A (2009) Management of cystic echinococcosis complications and dissemination: where is the evidence. *World J Surg* 33: 1266-1273.
24. Adas G, Arikan S, Gurbuz E, Karahan S, Eryasar B, et al. (2010) Comparison of endoscopic therapeutic modalities for postoperative biliary fistula of liver hydatid cyst: a retrospective multicentric study. *Surg Laparosc Endosc Perc Tech* 20: 223-227.
25. Lewall DB, Nyak P (1998) Cautionary signs of biliary complications in liver hydatidosis. *Br J Radiol* 71: 37-41.
26. Franciosi CM, Romano F, Porta G, Caprotti R, De Fina S, et al. (2002) Surgical treatment of hydatid disease of the liver. An experience from outside the endemic area. *Chir Ital* 54: 667-672.