

Management of Genu Varum/Valgum in Shwachman-Diamond Syndrome: A Report of Two Cases

Giovanni Luigi Di Gennaro¹, Elisa Pala^{2*} and Onofrio Donzelli¹

¹Paediatric Orthopaedic Surgeon, Pediatric Orthopedic Department, Istituto Ortopedico Rizzoli, Bologna, Italy

²Registrar University of Bologna, Pediatric Orthopedic Department, Istituto Ortopedico Rizzoli, Bologna, Italy

Abstract

Shwachman's syndrome is a rare autosomal recessive disorder characterized by exocrine pancreatic insufficiency, bone marrow failure and skeletal abnormalities. The skeletal defects in the knees are related to the asymmetrical development of the growth plates that can result in varum/valgum deformities.

We describe two cases of knee deformity in SDS patients surgically treated. In case n.1, because of a severe deformity, an osteotomy of the distal femur was performed by removing a lateral wedge and stabilizing with a staple, plus lateral tibial hemiepiphyodesis. In case n. 2 first a medial hemiepiphyodesis of the proximal tibia with Blount staples was performed. After 18 months the staples were removed from the tibia and a medial femoral hemiepiphyodesis was performed.

In both patients satisfactory angular alignment of the knees was obtained.

In patients with genu varu/valgum in SDS the general condition of the patient (values of neutropenia and thrombocytopenia) determines the timing of surgical treatment because the risk of infection is always lurking. Traditional methods, such as osteotomy or hemiepiphyodesis, have proved to be effective in the treatment of these deformities, but must be finely adjusted, by repeating or combining these procedures to adapt to the conditions of the pathologic physes.

Introduction

Shwachman's syndrome, first described by Shwachman et al. in 1964 [1], is a rare autosomal recessive disorder characterized by exocrine pancreatic insufficiency, bone marrow failure, skeletal abnormalities, short stature and other less common features [1-4].

Although its cause and pathogenesis remain unknown, an autosomal recessive genetic pattern has been suggested [3] and the altered gene is SBDS on chromosome 7q11. One of the hallmarks of SDS is exocrine pancreatic dysfunction caused by absence of acinar cells [2,5] and patients classically present in early infancy malabsorption, steatorrhea, failure to thrive, and low levels of fat soluble vitamins A, D, E, and K [2]. During childhood, almost 50% of patients present spontaneous improvement in pancreatic function and pancreatic enzyme supplements are discontinued. [2,5-7].

The most common hematological abnormality affecting 88–100% of patients with SDS is intermittent neutropenia [1,2,5,7,8]. Patients with SDS have an increased risk of myelodysplasia and malignant transformation, in particular, development of acute myelogenous leukemia [2,7,9,10]. Anemia, with reticulocytopenia has been described in 42%–82% of patients, whereas thrombocytopenia has been reported in 24%–88% of patients and can lead to fatal bleeding.

Patients with SDS are susceptible to recurrent bacterial, viral, and fungal infections [2,11]. Pancreatic exocrine and bone marrow dysfunctions are universal features of Shwachman–Diamond syndrome, whereas skeletal dysplasia is variable and observed in 40% to 80% of cases. [2,4].

Abnormal development of growth plates and metaphyses, delayed bone age, progressive deformities and pathological fractures have been reported [3,7].

Characteristic skeletal changes are present in all patients with SDS and SBDS mutations [4], but their severity and localization varies

with age. No phenotype–genotype correlation has been observed [2,4,5,12,13].

The slow normalization of the maturation defect with growth suggests that it is due to the underlying cellular pathology and not secondary to nutritional problems [4,7].

The association of metaphyseal chondrodysplasia and SDS was first reported by Burke et al. [14], while Stanley et al. [15] reported the more extensive metaphyseal involvement especially of the femoral head.

Other sites affected include the humeral heads, wrists, knees, ankles, spine and ribs [2]. Rib-cage abnormalities (narrow rib cage, shortened ribs with flared anterior ends, costochondral thickening), progressive spinal deformities (kyphosis, scoliosis, and vertebral collapse) have been described [4].

The lower limbs are affected more severely than the upper limbs. The typical features are: delayed appearance of secondary ossification centers, variable widening and irregularity of the metaphyses in early childhood, followed by progressive thickening and irregularity of the growth plates, associated frequently with asymmetrical growth, and generalized osteopenia of the long bones [2,4,5,12,13]. Asymmetrical growth results in valgus alignment of

*Corresponding author: Elisa Pala, Istituto Ortopedico Rizzoli, Via GC Pupilli, 1, 40136 Bologna, Italy, Tel: +393394044900; Fax: +39051331710; E-mail: pala.elisa@gmail.com

Received June 25, 2013; Accepted August 05, 2013; Published August 08, 2013

Citation: Di Gennaro GL, Pala E, Donzelli O (2013) Management of Genu Varum/Valgum in Shwachman-Diamond Syndrome: A Report of Two Cases. J Med Diagn Meth 2: 126. doi:10.4172/2168-9784.1000126

Copyright: © 2013 Di Gennaro GL, et al. This is an open-access article distributed under the terms of the Creative Commons Attribution License, which permits unrestricted use, distribution, and reproduction in any medium, provided the original author and source are credited.

the femoral necks and valgus tilting of the femoral heads on the femoral necks, and in the distal femur, varus or less often valgus deformities of the knees [4,5,8].

Two cases of knee deformity in SDS patients are described in the present paper: one patient with genu varum treated with corrective

osteotomy and one patient with genu valgum treated with temporary hemiepiphysestesis.

The data for this investigation were collected and analyzed in compliance with the procedures and policies set out in the Helsinki Declaration, and both patients gave their informed consent to data treatment. The study was authorized by the local Ethical Committee.

Case Report

Case 1 (Table 1, Figure 1)

The patient and his parents underwent genetic analysis to search for mutations in the SBDS gene with PCR-RFLP. This case was a compound heterozygote for two SBDS mutations, 258+2T→C and 183-184TA→CT.

He presented in July 2001 aged 9.6 years with a progressive varus deformity of the knees (Figure 1A). At that time the unstable general health conditions and the neutropenia with the consequent risk of infection were contraindications for surgery so it was decided to continue routine examinations in the outpatients clinic.

Over the next year, the general conditions of the patient improved but a worsening in the varus knees was observed. X-rays performed in 2002 showed a 25-30° varus deformity of the knees with an evident metaphyseal dysplasia that prompted us to consider a surgical solution (Figure 1B).

For such a severe deformity modulating growth surgery (such as hemiepiphysestesis with staples or 8-plate), which is preferred because it is less invasive and provides rapid functional recovery, was no longer sufficient. Therefore, correction had to be achieved by osteotomy of the femur. In June 2002 (age 10.5 years, height 124 cm, weight 37 kg) the right knee underwent osteotomy of the femur with lateral wedge removal and stabilization with a staple; the staple was placed astride the osteotomy and the physes to combine the initial correction obtained by the osteotomy with the modulating effect on the lateral half of the physes over time. Furthermore, the proximal tibia was treated with lateral hemiepiphysestesis using two staples. On the day of surgery Ceftriaxone 1.5 g. was administered intravenously as preoperative antibiotic prophylaxis and continued at dose of 1 g. per day over the following 4 days.

After surgery a cast was applied for 40 days. Despite the low neutrophil counts, we have no complications during the surgery or after surgery.

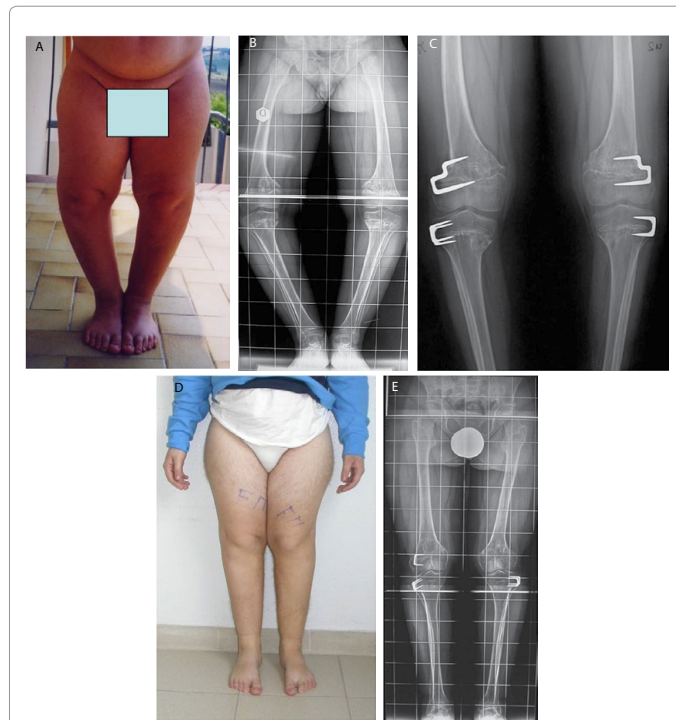


Figure 1: Case 1

- 1 A: Age 9.6 yrs, boy, genu varum in SDS.
- 1 B: Age 10.5 yrs, height 124 cm, weight 37 kg. Preoperative standing A.P. radiograph shows bilateral genu varum (25-30°). Evident dysplasia on the distal femur and proximal tibiae with lucent and irregular areas of ossification, flaring and beaking of the metaphysis on the medial corners.
- 1 C: post-operative X-ray shows the knees after osteotomy of both femurs with lateral wedge removal and stabilization with a staples; plus lateral tibial hemiepiphysestesis.
- 1 D: Age 16.10 yrs, height 149 cm, weight 63 Kg. General good conditions, normal lower extremity alignment.
- 1 E: Standing A.P. radiograph showing satisfactory correction 6 years later. The patient had reached skeletal maturity, so it was possible to remove hardware, because there was no "rebound effect" on risk.

	Case 1			Case 2		
	Osteotomy (first) May 2002	Revision surgery Dec 2005	Staples removal Dec 2008	Hemiepiphysestesis Aug 2007	Revision surgery Jan 2010	Staples removal Dec 2011
Age (years)	10.5	13.10	16.10	11.5	13.10	15.9
Height (cm)	124	144	149	126	139	150
Weight (kg)	37	50	63	35	47.6	52
RBC (4500000-5900000/mmc)	4.300.000	4.580.000	4.804.000	4.270.000	4.900.000	4.450.000
WBC (4500- 9500/ mmc)	4.200	3.300	3.900	5.700	4.900	4.100
Lymphocytes (%)	72.6	70.2	61.8	56.9	58.2	56.4
Neutrophil (%)	16.3	15.5	24.5	44.6	31.4	32.7
PLT (130-400000/ mmc)	110,000	79.000	82.000	113.000	94.000	66.000
Hg (14-18 g/100ml)	13.1	15	15.8	13.0	13.2	14.8

Table 1: Preoperative height, weight, and blood cell values.

Four months later, the same surgery was performed on the left knee (Figure 1C).

Correction of the deformity was assessed every three months.

Knee alignment was satisfactory radiographically, the ranges of knee motion were normal and the correction remained stable for about 3 years.

In 2005 loosening of the right femur staple and a tendency to overcorrection in the left knee was observed; the patient underwent revision surgery on both knees to reposition the staple in the right femur and remove the staple from the left femur.

In December 2008 (age 16.10 year, height 149 cm, weight 63 Kg), after the closure of growth plates and a correct global axis, the staples were removed from the right distal femur and from both tibiae (Figure

1D-E). In both surgery, despite the low neutrophil counts, we have no complications during the surgery nor after surgery.

Case 2 (Table 1, Figure 2)

The patient and his parents underwent genetic analysis to search for mutations in SBDS gene with PCR-RFLP. This case was a compound heterozygote for two SBDS mutations, 258+2TC and 183-184TA→CT.

He presented in 2007 aged 11 years with progressive valgus deformity of the knees. Clinically the intermalleolar distance was 13 cm (Figure 2A) and the X-rays showed a tibio-femoral axis of about 18° (Figure 2B). At that time his general health conditions were good and stable and, due to the progressive knee deformity, it was decided to perform surgery to counteract the tendency towards worsening.

In August 2007 (age 11.5 yrs, height 126 cm, weight 35 kg) he underwent a medial tibial hemiepiphysestomy with Blount staples. On the day of surgery Ceftriaxone 1 g. was administered intravenously as preoperative antibiotic prophylaxis and continued at dose of 1 g. per day over the following 4 days.

The patient was seen periodically in the outpatient clinic. After 18 months the intermalleolar distance was reduced to 8 cm, but the X-ray showed a persistence of valgus deformity of the femoral axis and an overcorrection of the tibia (Figure 2C).

In January 2010, at the age of 13.10, the staples were removed from the tibia and a medial femoral hemiepiphysestomy was performed.

In December 2011, (age 15.9 yrs, height 150 cm, weight 52 kg), the framework was stabilized, the physes was closed (Figure 2D-E) and the staples were removed.

Discussion

The association of metaphyseal chondrodysplasia with SDS was first reported by Burke et al. [14]. Skeletal abnormalities and age-related alterations were similar in all patients and showed no obvious correlation with the underlying SBDS mutations. Furthermore, there was considerable variability in the location and severity of the skeletal abnormalities even among patients with identical mutations [4].

The metaphyseal changes (Table 2) differed from those seen in Jansen's metaphyseal chondrodysplasia, rickets and Schmid's metaphyseal chondrodysplasia. It is more difficult to distinguish between SDS and Mc Kusick's metaphyseal chondrodysplasia (cartilage-hair hypoplasia) [4].

Skeletal changes are present in all patients examined in a study by Makitie et al. [4] and the presence or absence of abnormalities in a specific region of the skeleton appears to be dependent on the age of the patient [4].

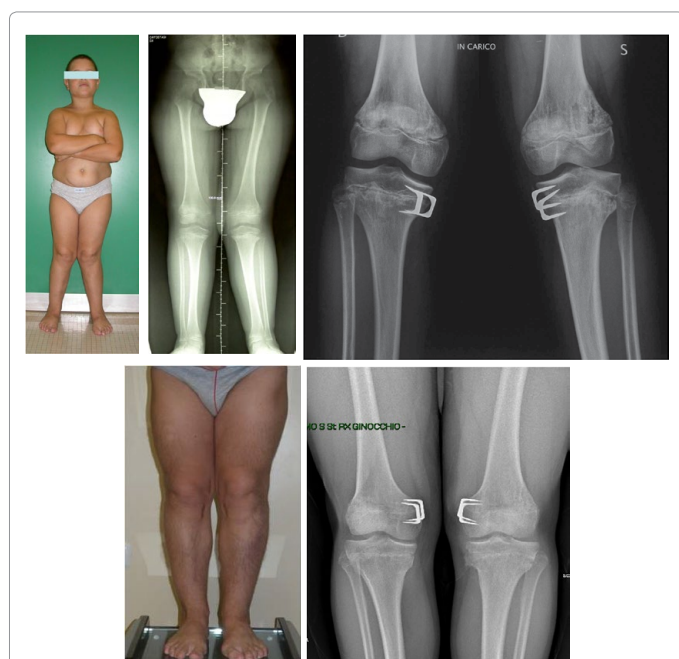

Figure 2: Case 2
 2 A: Age 11.5 yrs, boy, height 126 cm, weight 35 Kg, genu valgum in SDS. The intermalleolar distance was 13 cm.
 2 B: Preoperative full length standing A.P. radiograph shows a valgus knee deformity of 18° with metaphyseal dysplasia prevalent in the proximal tibia.
 2 C: 18 months after medial tibial hemiepiphysestomy with staples, the X-ray shows the persistence of valgus deformity of the femoral axis and an overcorrection of the tibia. At that time the intermalleolar distance was 8 cm.
 2 D: Age 15.9 yrs, height 150 cm, weight 52 Kg. Clinical features with the knees aligned properly before removing the staples from the femur.
 2 E: Full length standing A.P. radiograph shows framework stabilized.

Jansen (MIM 156400)	Schmid (MIM 156500)	McKusick (MIM 250250)	Rickets
extreme disorganization of the metaphyses; severe short stature; <u>biochemical abnormalities</u> (calcium, phosphorus, alkaline phosphatase)	disproportioned short stature; bowed legs; coxa vara; radiographic change most pronounced at the hip with enlarged capital femoral epiphysis and short femoral neck; <u>no extra skeletal manifestations</u>	haematological abnormalities; defective immunity; severe short-limbed short stature; <u>hair hypoplasia</u>	<u>biochemical abnormalities</u> (calcium, phosphorus, alkaline phosphatase); cupping, fraying, and splaying of metaphyses occur predominantly at sites of rapid growth (proximal humerus, distal radius, distal femur and both ends of the tibia); the radiologic appearance varying with the growth rate of the child: renal rickets is usually seen in older children, nutritional rickets is more common in infants;

Table 2: Different types of metaphyseal chondrodysplasia [4].

Concerning the knee in SDS, during the first 2 years of life, secondary ossification centers of the distal femur and proximal tibia are small and develop slowly. The metaphyses of the distal femur and proximal tibia are often expanded with beaking of the medial and lateral corner. During late childhood and adolescence, the secondary centers of ossification become larger and more normal in shape. At this age, thickening of the growth plates is often associated with lucent and irregular areas of metaphyseal ossification (Figure 1B and 2B). Some of them have asymmetrical growth producing varus and (less often) valgus deformities of the knee. Similar changes are seen in the proximal tibia as well, but the abnormalities are less pronounced [4].

The assessment of standard radiographic measurements such as mechanical axis deviation with use of full-length standing radiographs has been found to be reliable in children [16].

Osteotomy is the most common technique for correcting the angular deformity of a limb. However, growth manipulation or guided growth is a viable option in some skeletally immature patients. Prerequisites to guided growth include angular deformity as well as physes with sufficient remaining growth to achieve correction [17]. Determining the appropriate timing of hemiepiphysiodesis is one of the most difficult aspects of using growth manipulation to correct angular deformity in patients with skeletal dysplasia. Estimating remaining growth based on skeletal age is an inexact process. The health of the physes must be considered [18]. Furthermore the results of hemiepiphysiodesis in patients with physal abnormalities have been unpredictable. Additionally, severe angular deformities may disturb normal physal growth [17].

For all these reasons, in case n.1 because of such a severe deformity, it was not sufficient to perform a hemiepiphysiodesis, so it was decided to perform an osteotomy to correct the deformity immediately. In addition, the staple was applied astride the physes to hold the osteotomy in place and combine the immediate correction obtained by the osteotomy with the modulating effect on the physes over time, thus to prevent a possible recurrence of the deformity. At the same time, the proximal tibia was treated with the application of two staples on the lateral side to counter the worsening of the deformity over time.

In case n. 2 a medial hemiepiphysiodesis of the proximal tibia with Blount staples was performed with the aim of modulating the growth to counteract the tendency to worsen. Once angular correction was achieved on the tibia (actually a small amount of overcorrection had occurred), and there was still a valgus alignment of the knees, the tethering device (staples) was removed from the tibia, so normal linear growth resumed and placed on the femur to continue the correction. When the framework was stabilized, with the knees aligned properly, the staples were removed from the femur.

Briefly, to prevent the patient's condition from worsening and avoid making an osteotomy mandatory, a medial hemiepiphysiodesis was performed on the tibiae, although age was a bit premature because the response to growth manipulation of pathological physes was unpredictable. This partial or rather prudent approach, required subsequent treatment of the femur.

Because response to treatment of the dysplastic physes combined with guided growth procedures is hard to predict, it is imperative to inform parents well regarding the importance of routine postoperative follow-up (approximately every 3-4 months) and the likelihood of additional procedures, to fine-tune the angular alignment.

In conclusion the management of genu varum/valgum in SDS

the general condition of the patient (values of neutropenia and thrombocytopenia) determines the timing of surgical treatment because the risk of infection and/or bleeding is always lurking. Traditional methods, such as osteotomy or hemiepiphysiodesis, have proved to be effective in the treatment of these deformities, but must be finely adjusted, i.e. sometimes it is necessary to repeat the procedure or to combine them to adapt to the conditions of the pathologic physes.

Conflict of Interest

We wish to draw the attention of the Editor to the following facts which may be considered as potential conflicts of interest and to significant financial contributions to this work.

We wish to confirm that there are no known conflicts of interest associated with this publication and there has been no significant financial support for this work that could have influenced its outcome.

We confirm that the manuscript has been read and approved by all named authors and that there are no other persons who satisfied the criteria for authorship but are not listed. We further confirm that the order of authors listed in the manuscript has been approved by all of us.

We confirm that we have given due consideration to the protection of intellectual property associated with this work and that there are no impediments to publication, including the timing of publication, with respect to intellectual property. In so doing we confirm that we have followed the regulations of our institutions concerning intellectual property.

We further confirm that any aspect of the work covered in this manuscript that has involved either experimental animals or human patients has been conducted with the ethical approval of all relevant bodies and that such approvals are acknowledged within the manuscript.

We understand that the Corresponding Author is the sole contact for the Editorial process (including Editorial Manager and direct communications with the office). He/she is responsible for communicating with the other authors about progress, submissions of revisions and final approval of proofs.

References

1. Shwachman H, Diamond LK, Oski FA, Khaw KT (1964) THE SYNDROME OF PANCREATIC INSUFFICIENCY AND BONE MARROW DYSFUNCTION. J Pediatr 65: 645-663.
2. Burroughs L, Woolfrey A, Shimamura A (2009) Shwachman-Diamond syndrome: a review of the clinical presentation, molecular pathogenesis, diagnosis, and treatment. Hematol Oncol Clin North Am 23: 233-248.
3. Aggett PJ, Cavanagh NP, Matthew DJ, Pincott JR, Sutcliffe J, et al. (1980) Shwachman's syndrome. A review of 21 cases. Arch Dis Child 55: 331-347.
4. Mäkitie O, Ellis L, Durie PR, Morrison JA, Sochett EB, et al. (2004) Skeletal phenotype in patients with Shwachman-Diamond syndrome and mutations in SBDS. Clin Genet 65: 101-112.
5. Dall'Oca C, Bondi M, Merlini M, Cipolli M, Lavini F, B et al. (2011) Shwachman-Diamond syndrome. Musculoskelet Surg.
6. Cipolli M, D'Orazio C, Delmarco A, Marchesini C, Miano A, et al. (1999) Shwachman's syndrome: pathomorphosis and long-term outcome. J Pediatr Gastroenterol Nutr 29: 265-272.
7. Mack DR, Forstner GG, Wilschanski M, Freedman MH, Durie PR (1996) Shwachman syndrome: exocrine pancreatic dysfunction and variable phenotypic expression. Gastroenterology 111: 1593-1602.
8. Dhar S, Anderton JM (1994) Orthopaedic features of Shwachman syndrome. A report of two cases. J Bone Joint Surg Am 76: 278-282.
9. Faber J, Lauener R, Wick F, Betts D, Filgueira L, et al. (1999) Shwachman-Diamond syndrome: early bone marrow transplantation in a high risk patient and new clues to pathogenesis. Eur J Pediatr 158: 995-1000.

10. Woods WG, Roloff JS, Lukens JN, Krivit W (1981) The occurrence of leukemia in patients with the Shwachman syndrome. *J Pediatr* 99: 425-428.
11. Grinspan ZM, Pikora CA (2005) Infections in patients with Shwachman-Diamond syndrome. *Pediatr Infect Dis J* 24: 179-181.
12. Berrocal T, Simon MJ, al-Assir L, Prieto C, Pastor L, et al. (1995) Shwachman-Diamond syndrome: clinical, radiological and sonographic findings. *Pediatr Radiol*. 25: 356-9.
13. Canepa G, Maroteaux P, Pietrogrande V (1996) Condrodisplasia metafisaria tipo Shwachman. *Sindromi dismorfiche e malattie costituzionali dello scheletro*. Vol. 1. Padova: Piccin, 2001: 277.
14. Burke V, Colebatch JH, Anderson CM, Simons MJ (1967) Association of pancreatic insufficiency and chronic neutropenia in childhood. *Arch Dis Child* 42: 147-157.
15. Stanley P, Sutcliffe J (1973) Metaphyseal chondrodysplasia with dwarfism, pancreatic insufficiency and neutropenia. *Pediatr Radiol* 1: 119-126.
16. Gordon JE, Chen RC, Dobbs MB, Luhmann SJ, Rich MM, et al. (2009) Interobserver and intraobserver reliability in the evaluation of mechanical axis deviation. *J Pediatr Orthop* 29: 281-284.
17. Saran N, Rathjen KE (2010) Guided growth for the correction of pediatric lower limb angular deformity. *J Am Acad Orthop Surg* 18: 528-536.
18. McIntosh AL, Hanson CM, Rathjen KE (2009) Treatment of adolescent tibia vara with hemiepiphysiodesis: risk factors for failure. *J Bone Joint Surg Am* 91: 2873-2879.