

# Living Donor Liver Transplantation for Patients with Pre-existent Portal Vein Thrombosis

Hazem M Zakaria<sup>1</sup>, Mohammad Taha<sup>1</sup>, Emad Hamdy Gad<sup>1</sup>, Hossam El-Deen Soliman<sup>1</sup>, Osama Hegazy<sup>1</sup>, Talaat Zakareya<sup>2</sup>, Mohamed Abbasy<sup>2</sup>, Dina Elazab<sup>3</sup>, Doha Maher<sup>3</sup>, Rasha Abdelhafiz<sup>4</sup>, Hazem Abdelkawy<sup>4</sup>, Nahla K Gaballa<sup>5</sup>, Khaled Abou El-Ella<sup>1</sup> and Tarek Ibrahim<sup>1</sup>

<sup>1</sup>Department of Hepatopancreatobiliary and Liver Transplant Surgery, National Liver Institute, Menoufia University, Menoufia, Egypt

<sup>2</sup>Department of Hepatology and Gastroenterology, National Liver Institute, Menoufia University, Menoufia, Egypt

<sup>3</sup>Department of Pathology, National Liver Institute, Menoufia University, Menoufia, Egypt

<sup>4</sup>Department of Diagnostic and intervention radiology, National Liver Institute, Menoufia University, Menoufia, Egypt

<sup>5</sup>Department of Anesthesia and Intensive Care, National Liver Institute, Menoufia University, Menoufia, Egypt

**Corresponding Author:** Hazem Zakaria, National Liver Institute, Menoufia University, Shebin El-koom, Menoufia, Egypt, Tel: +201097071055; E-mail: hazemlashenn@yahoo.com

**Received date:** May 25, 2017; **Accepted date:** June 5, 2017; **Published date:** June 8, 2017

**Copyright:** © 2017 Zakaria HM, et al. This is an open-access article distributed under the terms of the Creative Commons Attribution License, which permits unrestricted use, distribution, and reproduction in any medium, provided the original author and source are credited.

## Abstract

**Background:** Portal vein thrombosis (PVT) in living donor liver transplantation (LDLT) is a surgical challenge with technical difficulty. The aim of this study was to analyze the operative planning for management of PVT in LDLT and the impact of PVT on the outcome in comparison to patients without PVT.

**Methods:** Between July 2003 to August 2016, 213 patients underwent LDLT. The patients were divided into two groups with and without PVT. The preoperative, operative, and postoperative data were analysed.

**Results:** Thirty six patients (16.9%) had different grades of PVT at time of liver transplantation (LT); grades I, II, III and IV were 18 (50%), 14 (38.9%), 3 (8.3%) and 1 patient (2.8%) respectively. The management of PVT was by; thrombectomy in 31 patients (86%), bypass graft in 2 patients (5.6%), portal replacement graft in 1 patient (2.8%), anastomosis with the left renal vein in 1 patient (2.8%) and with large collateral vein in 1 patient (2.8%). Overall postoperative PVT occurred in 10 patients (4.7%), 4 patients of them had preoperative PVT. The perioperative mortality in patients with PVT, and patients without PVT was 33.3%, and 20.3%, respectively (P=0.17). The 1-, 3-, 5-, and 7y survival in patients with PVT was 49.7%, 46.2%, 46.2%, 46.2% respectively and in patients without PVT it was 65%, 53.7%, 50.8%, 49% respectively (P=0.29).

**Conclusions:** Preoperative PVT may not keep a patient from undergoing successful LT with comparable outcome to patients without PVT specially with partial PVT.

**Keywords** Portal vein thrombosis; Living donor; Liver transplantation; Thrombendvenectomy; Venous graft

## Introduction

Portal vein thrombosis (PVT) was previously viewed as an absolute or a relative contraindication to living donor liver transplantation (LDLT). It may not currently keep from experiencing fruitful liver transplantation (LT) with the refinement of surgical techniques, yet there is generously increased surgical complexity and perioperative morbidity [1,2].

Many surgical techniques have been introduced to gain adequate portal flow such as thrombectomy, and portal vein (PV) reconstruction using interposition or bypass vein grafts. The utilization of these procedures relies upon the degree of PVT (partial or complete), the extension of the thrombus through the splanchnic venous system and the experience of the different transplant groups [3-5].

In LDLT there are some difficulties in vascular pedicle dissection at the hilum of the liver specially with large collaterals, and the limited availability of venous grafts make this surgery a challenge [5-8]. The

aim of this study is to analyse the different modalities in management of PVT and its impact on the outcome of LDLT in comparison to patients without PVT.

## Patients and Methods

The study was conducted as retrospective study of 213 adult patients who underwent LDLT at National Liver Institute, Menoufia University, Menoufia, Egypt, between July 2003 and August 2016. The patients were divided into two groups; group of patients with PVT, and patients without PVT as a comparison group. The data were collected from an institutional review board (IRB) approved prospective database.

The preoperative, intraoperative, and postoperative data were collected. Diagnosis of preoperative PVT was by Doppler ultrasound (US) and the portography phase of the abdominal triphasic computed tomography (CT) scan or magnetic resonance image (MRI) that were performed within one month before LT. Also accidental intraoperative detection of PVT was included in the study. Patients with PVT and HCC positron emission tomography (PET) scan was done to exclude malignant PVT.

**Yerdel [4] classification was used for grading of PVT and surgical planning:**

**Grade I:** Partial thrombosis of PV of <50% of the vein lumen, with no or minimal extension to the superior mesenteric vein (SMV).

**Grade II:** obstruction >50% of the PV lumen, including total obstruction, with no or minimal extension to SMV.

**Grade III:** Complete thrombosis of the PV and the proximal of SMV.

**Grade IV:** Complete thrombosis of both PV and SMV.

Proline 6/0 sutures were used for PV anastomosis in a continuous matter for anterior and posterior wall. Patients with small PV diameter, interrupted sutures were used for the anterior wall.

Intraoperative Doppler ultrasound (US) was used for evaluation of the vasculature before abdominal closure. Daily Doppler US was done for postoperative follow up during the hospital stay.

**Postoperative anticoagulant therapy**

Heparin infusion was used (50 µg/kg/day) for first week, then low molecular weight heparin (LMWH) subcutaneous in a therapeutic doses (1 ml/kg, twice daily) and antiplatelets until discharge. Oral anticoagulant as Warfarin, and antiplatelets were given for 6 months after the hospital discharge. All patients with PVT and hepatocellular carcinoma (HCC) underwent histopathological analysis for the thrombus.

Follow-up of the patients was from the date of surgery to April 2017, by Doppler US every month in first year postoperative, then every 3-6 months after one year. For suspected cases with PVT or weak flow, CT portography was done. Postoperative PVT was classified as early PVT (in the first 3 ms), and late PVT (after 3 ms of LT). Perioperative mortality was described as the mortality in the first month post-transplant. The 1-, 3-, 5 y survival was recorded.

All the data were collected, tabulated, analysed using SPSS version 21. Chi-square or Fisher's exact test and Mann Whitney U or Student T-test were used for statistical analysis. The survival rate was calculated with the Kaplan-Meier method and compared using Log-rank test. P values of less than 0.05 was considered significant.

**Results**

From July 2003 to August 2016, 213 adult recipients underwent LDLT. The incidence of PVT in patients who underwent LDLT was 36 patients (16.9%), and 177 patients (83.1%) without PVT.

All patients with PVT were diagnosed by preoperative US, and confirmed by CT portography, except in 8 (22%) patients that PVT was discovered intraoperative; 6 patients of them had grade I PVT, and 2 patients had grade II PVT. So the sensitivity, specificity, positive and negative predictive values of the US was 99%, 77.8, 93.3% and 95.6% respectively and the accuracy was 95%.

Patients' demographic, Graft characteristics, Characteristics of PV anastomosis and recipient operation were listed in Table 1.

Character	PVT	No PVT	p-value
	(36)	(177)	
<b>Recipient age</b>			0.95
Mean ± SD	46.5 ± 9.7	46 ± 8.2	
Range	(18-60)	(18-63)	
<b>Receipient gender</b>			1
Male	4(11.1%)	21(11.9%)	
Female	32(88.9%)	165(88.1%)	
<b>Donor age</b>			0.65
Mean ± SD	27.8 ± 7.2	27.2 ± 6.5	
Range	(18-43)	(18-45)	
<b>Donor gender</b>			0.69
Male	24(66.7%)	124(70%)	
Female	12(33.3%)	53(30%)	
<b>Primary disease</b>			0.09
-HBV/HCV related liver cirrhosis without HCC	21(58.3%)	99(56%)	
- liver cirrhosis with HCC	8(22.2%)	62(35%)	
-Others	7(19.5%)	16(9%)	
<b>Child score</b>			0.51

A	3(8.3%)	8(4.5%)	
B	12(33.3%)	54(30.5%)	
C	21(58.4%)	115(65%)	
<b>MELD score</b>			1
Mean ± SD	16 ± 5	16 ± 4	
Range	(10-26)	(7-34)	
<b>GRWR%</b>			0.87
Mean ± SD	1 ± 0.25	1 ± 0.21	
Range	(0.65-1.7)	(0.6-1.7)	
<b>Type of the graft</b>			0.9
Right lobe	34(94.4%)	170(96%)	
Left lobe	2(5.6%)	7(4%)	
<b>No of graft portal veins</b>			0.85
One	34 (94.5%)	162(91.5%)	
Two	2(5.5%)	15 (8.5%)	
<b>PV diameter (mm)</b>			0.09
Mean ± SD	13.0 ± 3.67	18.9 ± 3.41	
Range	(9-22)	(11-24)	
<b>CIT (min)</b>			0.02
Mean ± SD	93 ± 69	66 ± 42	
Range	(40-340)	(20-320)	
<b>WIT (min)</b>			0.82
Mean ± SD	52 ± 16	51 ± 17	
Range	(30-90)	(25-120)	
<b>PV anastomosis time (min)</b>			0.77
Mean ± SD	15.45 ± 3.75	16.42 ± 6.38	
Range	(10-25)	(10-30)	
<b>Total operative time (h)</b>			0.01
Mean ± SD	14.1 ± 4.3	12.6 ± 2.6	
Range	(7-29)	(7-23)	
<b>Plasma transfusion (unit)</b>			0.01
Mean ± SD	12 ± 11	6 ± 7	
Range	(0-53)	(0-34)	
<b>Blood transfusion (unit)</b>			0.01
Mean ± SD	11 ± 11	6 ± 5	
Range	(0-46)	(0-33)	

<b>Postoperative Complications</b>			0.19
-PV complication (stenosis, thrombosis)	5(13.9%)	6(3.4%)	0.02
- HA complication (stenosis, thrombosis, steal)	10(27.8%)	27(15.3%)	0.07
- Biliary complication (biliary stricture, bile leak)	10(27.8%)	83(46.9%)	0.08
-Rejection	9(25%)	53(30%)	0.69
<b>Hospital stay (day)</b>			0.34
Mean ± SD	26 ± 23	23 ± 15	
Range	(1-91)	(1-120)	
<b>Hospital mortality</b>	15(41.6%)	52(29.4%)	0.17

PVT (Portal vein thrombosis), SD (Standard deviation), HBV (Hepatitis B virus), HCV (Hepatitis C virus), HCC (Hepatocellular carcinoma), MELD (Model of end stage liver disease), GRWR (Graft recipient weight ratio), CIT (Cold ischemia time), WIT (Worm ischemia time), Min (Minute), mm (millimeter), PV (Portal vein), h (hour), No (number).

**Table 1:** Patients demographics, preoperative, operative and postoperative data in patients with and without PVT.

The risk factors for preoperative PVT in cirrhotic patients were; high model of end stage liver disease (MELD) score (P=0.04), low protein C (P=0.03).

Of 36 patients with PVT, 18 patients (50%) had PVT grade I, 14 patients (38.9%) had grade II PVT, 3 patients (8.3%) had grade III PVT, and only 1 patient (2.8%) had grade IV PVT.

Intraoperative management of PVT was as follow; 31 patients (86%) underwent thrombectomy (eversion thromboendovenectomy in 25 patients, simple thrombectomy in 4 patients, and incisional thrombectomy in 2 patients), 2 patients (5.6%) had bypass graft from the recipient left internal jugular vein (IJV) between SMV and graft PV, 1 (2.8%) patient had portal replacement graft from the recipient left external iliac vein (EIV), 1 (2.8%) patient with grade IV PVT had anastomosis between left renal vein and graft PV by venous graft from IJV, 1 (2.8%) patient with grade III PVT had anastomosis between large collateral vein and graft PV.

Seven patients with preoperative PVT and HCC all were proved to be benign PVT after histopatological analysis

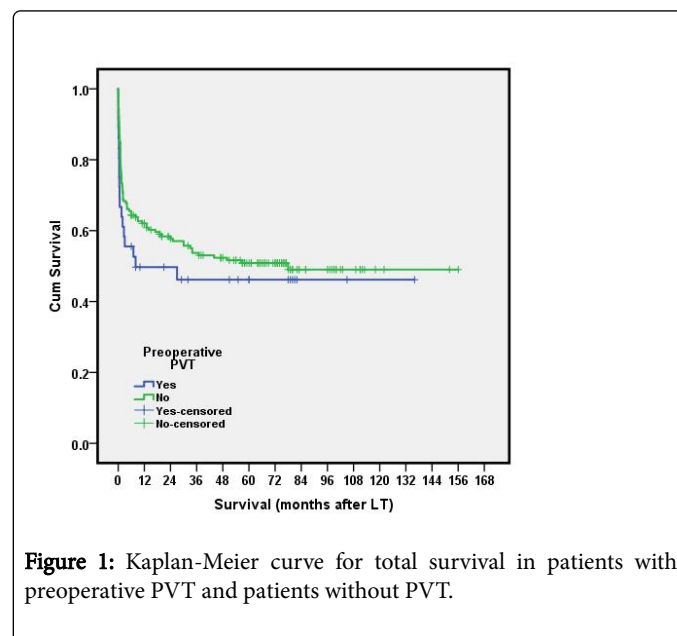
Post-operative main complications were listed in Table 1. Postoperative PVT occurred in 10 patients (4.7%) all in the form of early PVT. four patients had preoperative PVT; 2 patients grade II PVT, 1 patient grade I, and 1 patient grade III. One patient of the 4 had postoperative partial PVT and 3 patients complete obstruction.

The management of postoperative PVT was by exploration and thrombectomy in addition to anticoagulant in 4 patients. Two patients underwent treatment by thrombolytic agents as (Streptokinase or tissue plasminogen activator) and anticoagulant because of the bad general condition and multi organ failure, the remaining 4 cases, anticoagulant was only used.

In this study, there was significant statistical correlation between the occurrence of post-operative PVT and low protein C (P=0.02), intra operative massive blood and plasma transfusion (P=0.03), and long operative time (P=0.01). postoperative PVT had no significant relation with the preoperative PVT (P=0.14), or the use of vascular grafts in PV reconstruction (P=0.6).

In patients with PVT the perioperative mortality was (12/36) 33.3%, the 90 days mortality was (16/36) 44.4%. The 1-, 3-, 5-, and 7y total survival in patients with PVT was 49.7%, 46.2%, 46.2%, 46.2%.

In patients without PVT the pri-operative mortality was (36/177) 20.3%, the 90 days mortality was (56/177) 31.6%, with no statistical significance with the group of PVT (P=0.17). The 1-, 3-, 5-, and 7y survival was 65%, 53.7%, 50.8%, 49%. There was no statistical significant difference between the total survival of both groups (P=0.29) (Figure 1).



**Figure 1:** Kaplan-Meier curve for total survival in patients with preoperative PVT and patients without PVT.

The perioperative mortality in patients with partial PVT was 12%, the perioperative mortality in complete PVT was 55.5% with statistical significant difference (P<0.01). In patients with partial PVT the 1-, and 5 y survival was 65.8%, and 58.5% respectively. In patients with complete PVT the 1-, and 5 y survival was 33.3%, and 33.3% with significant difference between the two groups (P=0.03).

In univariate analysis risk factors for overall survival were; high MELD score ( $P=0.05$ ), massive intraoperative blood and plasma transfusion ( $P=0.01$ ), postoperative vascular complications ( $P=0.01$ ), postoperative biliary complications ( $P=0.05$ ), acute graft rejection ( $P=0.05$ ), small for size syndrome ( $P=0.04$ ). Preoperative PVT was not a risk factor for survival ( $P=0.37$ ).

In multivariate analysis the independent risk factors for overall survival were; high MELD score ( $P=0.04$ ), massive intraoperative blood transfusion ( $P=0.01$ ), postoperative vascular complications ( $P=0.01$ ), postoperative biliary complications ( $P=0.01$ ), acute graft rejection ( $P=0.03$ ), small for size syndrome ( $P=0.01$ ). Preoperative PVT was not a risk factor for survival ( $P=0.17$ ).

## Discussion

Portal vein thrombosis was previously viewed as a contraindication to liver transplantation. Now, the procedure can be performed even in extended thrombosis with reported favourable results. However, there is still a considerable intraoperative challenge during hilar dissection due to extensive collateral formation and inflammatory changes around the PV with a relative perioperative hazard for LT [3,9].

In our study the incidence of pre-operative PVT in patients undergoing LDLT was (16.9%), nearly similar to the incidence reported by most liver transplant centres, which ranged from 2 to 26% [6].

Several studies have described risk factors for PVT including male patients, old age, cryptogenic liver cirrhosis, autoimmune hepatitis, Child class C, hypercoagulability, HCC of the liver, and previous splenectomy or portosystemic shunt [7,8]. Others described a significant relation between PVT and the presence of spontaneous bacterial peritonitis and lower levels of albumin [10]. In this study the risk factors for preoperative PVT was high MELD score and low protein C. Although we observed a greater incidence among males, older candidates, Child-Pugh C, Budd-Chiari syndrome and viral cirrhosis we cannot consider them as predisposing factors because the statistical differences were not significant.

The sensitivity and specificity of US in detecting PVT were reported by Yerdel et al., as 73%, and 99% respectively, the positive and negative predictive values of the US were 86% and 98% respectively. The sensitivity in grades I, II, III, and IV PVT was 48%, 82%, 100%, and 100%, respectively so it was increased with the degree of thrombosis [4]. Pécora et al., also reported that false negative results of US can occur only in patients with partial PVT, so it was significantly higher in grade I PVT [1], as we had reported in our series.

Francoz et al., and others reported successful PV recanalization and safe surgery after trial of anticoagulant treatment in 8 of 19 patients before transplantation by utilizing LMWH and oral anticoagulant [11,12]. Egawa et al., likewise attempted preoperative anticoagulation with successful decrease in the size of the thrombus in one patient following one month treatment [8]. But in our study we did not use anticoagulant before LT.

Artacho et al., reported 48 patient with PVT, and management was by; thrombectomy in 36 patients (75%) (26 partial and 10 complete PVT), venous conduit in 4 patients (8.3%) (1partial and 3 total PVT), cavoportal hemitransposition in 4 patients (8.3%), collateral vein-portal anastomosis in 3 patients (6.2%), anastomosis with right renal vein in 1 patient (2%) [7].

In other expressive series, Pan et al., showed the experience of transplantation in 253 patients with different grades of PVT; (grades I, II, III, and IV were 104, 114, 29, and 6 patients respectively). In grades I and II, the management was by thrombectomy without any hospital mortality. For patients with grade III PVT; thrombectomy was only possible in 23 patients and 4 patients had venous graft reconstruction for SMV or tributary vein-portal anastomosis, and 2 patients were submitted to portal arterialization with 3.4% hospital mortality. For patients with grade IV PVT, the management was by successful thrombectomy in 3 patients, renal vein-portal anastomosis in 2 patients and cavoportal hemi-transposition in 1 patient [13].

For PV reconstruction with jumping graft from the SMV, it is sometimes needed to have a long enough vein graft. The reconstruction using 2 vein grafts may be required if a single vein graft was too short. These vein grafts might be from the EIV, IJV, the distal portion of the native PV, the umbilical portion of the left PV or Cryo-preserved vein grafts [8,14,15].

Our series match with Yerdel et al., and Manzia et al., that the best treatment in patients with grade III PVT is the venous graft or anastomosis to a large collateral vein or the renal side of spleno-renal shunt [4,16].

Liado et al., reported that there is a controversy regarding the management of grade IV PVT. Liver transplantation may be contraindicated if there was no suitable collateral vein for anastomosis, as it is associated with poor outcome [3].

The recurrence rate of PV rethrombosis vary among series, ranging from 0% to 30%, depending on the severity of PVT, its preoperative extension and also on the time of LT [2,5,17]. In our series 4 patients (11.1%) had rethrombosis of PV which compares favorably with the published rates. Three patients of postoperative PVT were mainly due to venous out flow obstruction and graft congestion and not related to surgical technique as the thrombus is floating and not attached to the wall of the PV.

Liado et al., and others showed a high rate of post-LT rethrombosis [18], although this finding has not been confirmed by other authors [19]. These differences in the rates of rethrombosis probably due to the different types of patients included in the various studies, differences in surgical techniques and centre's experience [19,20]. In contrast to our series, Carvellas et al., showed that the post-LT PVT re-thrombosis was an independent risk factor for poor survival [21].

There is still controversial regarding the outcome of patients with PVT post-LT, almost similar to that without PVT or rather worse [22]. In a recent study [21] the outcome of LT for patients with preoperative PVT was similar to recipients without PVT in well selected patients. However Saidi et al., showed a worse allograft survival and patients survival in LDLT for patients with pre-existing PVT compared to patients without PVT [23].

Despite the surgical progress, the perioperative mortality rates of LT in the presence of PVT remain high, ranging from 9 to 42% [20]. In our study the peri-operative mortality rates in the cases with preoperative PVT was 33.3% vs. 20.3% in patients without PVT with no statistical significant difference ( $P=0.13$ ).

Some studies agree with the literature that LT in patients with PVT is associated with a greater postoperative mortality rate than patients without PVT (29.1% vs. 16.5%;  $P<0.05$ ). Nevertheless, their study showed that the significant difference was only in candidates with total PVT ( $P<0.01$ ) but not among patients with partial PVT ( $P=0.8$ ) [7,24].



That was match with our series in which there was significant higher perioperative mortality in patients with total PVT ( $P < 0.01$ ).

Also other series reported a significant higher first 3 months perioperative mortality and graft failure in patients with pre-existing PVT mainly in patients with extensive PVT [24,25].

One of large reported series, which included 63 patients with PVT, showed that patients with PVT had longer operative time, greater transfusion, and higher post-operative mortality [7,26]. However, other reports described that there was no increase in post-LT mortality or reduced survival but there was only more difficult operation [3,27,28].

Dumortier et al., reported that 1-year survival rates of patients with and without PVT were similar: 83.7% vs. 86.7%. But the patient survival rate might be altered in cases of extensive PVT, associated with high rates of rethrombosis and mortality [20]. Doenecke et al., showed that 1y survival for patients with PVT grade I,II was 90%, compared to 57% for PVT grade III, IV. They also reported no significant difference in the incidence of post-perative liver dysfunction between high and low MELD PVT groups except for a slightly higher transfusion requirement longer intraoperative parameters and the duration of hospital stay [29]. In the study by Pécora et al., the patients with PVT grade I presented a 5 y survival rate identical to controls (86%); but patients with degrees II, III and IV had lower survivals [1] as shown in our series. Qi et al., showed that the recipients with preoperative PVT, especially with complete thrombosis, had no statistically significant difference in perioperative or five year survival rate than patients without PVT [30].

## Conclusions

Preoperative PVT may not prevent a patient from experiencing successful LT with comparable outcome to patients without PVT. Preoperative knowledge of the level of PVT can help with the operative plane of management to diminish the surgical complexity. Partial PVT had better prognosis than complete thrombosis.

## References

1. Pécora RA, Canedo BF, Andraus W, Martino RB, Santos VR, et al. (2012) Portal vein thrombosis in liver transplantation. *Arq Bras Cir Dig* (São Paulo) 25: 273-278.
2. Ponziani FR, Zocco MA, Campanale C, Rinninella E, Tortora A, et al. (2010) Portal vein thrombosis: Insight into physiopathology, diagnosis, and treatment. *World J Gastroenterol* 16: 143-155.
3. Llado L, Fabregat J, Castellote J, Ramos E, Torras J, et al. (2007) Management of portal vein thrombosis in liver transplantation: influence on morbidity and mortality. *Clin Transplant* 21: 716-721.
4. Yerdel MA, Gunson B, Mirza D, Karayalçin K, Olliff S, Buckels J, et al. (2000) Portal vein thrombosis in adults undergoing liver transplantation: risk factors, screening, management, and outcome. *Transplantation* 69: 1873-1881.
5. Orlando G, De Luca L, Toti L, Zazza S, Angelico M, et al. (2004) Liver transplantation in the presence of portal vein thrombosis: report from a single center. *Transplant Proc* 36: 199-202.
6. Gimeno F, Calvo J, Loinaz C, Meneu JC, Perez B, et al. (2005) Comparative analysis of the results of orthotopic liver transplantation in patients with and without portal vein thrombosis. *Transplant Proc* 37: 3899-3903.
7. Artacho G, Pulido L, Martinez J, Artacho GS, Pulido LB, et al. (2010) Outcomes of liver transplantation in candidates with portal vein thrombosis. *Transplantation Proceedings* 42: 3156-3158.
8. Egawa H, Tanaka K, Kasahara M, Takada Y, Oike F, et al. (2006) Single center experience of 39 patients with preoperative portal vein thrombosis among 404 adult living donor liver transplantations. *Liver Transpl* 12: 1512-1518.
9. Wu TH, Lin YS, Lee CF, Wu TJ, Yu MC, et al. (2011) Clinical Analysis and Strategy for Liver Transplantation in Patients with Pre-existing Portal Vein Thrombosis. *Chang Gung Med J* 34:426-434.
10. Conde MH, LlopE, Revilla J, Pons F, Puga NF, et al. (2016) Prevalence and outcome of portal thrombosis in a cohort of cirrhotic patients undergoing liver transplantation. *Revista Española de Enfermedades Digestivas* 108: 716-720.
11. Francoz C, Belghiti J, Vilgrain V, Sommacale D, Paradis V, et al. (2005) Splanchnic vein thrombosis in candidates for liver transplantation: usefulness of screening and anticoagulation. *Gut* 54: 691-697.
12. Chen H, Liu L, Qi X, He C, Wu F, et al. (2016) Efficacy and safety of anticoagulation in more advanced portal vein thrombosis in patients with liver cirrhosis. *Eur J Gastroenterol Hepatol* 28: 82-89.
13. Pan C, Shi Y, Zhang JJ, Deng YL, Zheng H, et al. (2009) Single-center experience of 253 portal vein thrombosis patients undergoing liver transplantation in China. *Transplant Proc* 41: 3761-3765.
14. D'Amico G, Tarantino G, Spaggiari M, Ballarin R, Serra V, et al. (2013) Multiple ways to manage portal thrombosis during liver transplantation: surgical techniques and outcomes. *Transplant Proc* 45: 2692-2699.
15. Moon D, Lee S, Hwang S, Park K, Kim K, et al. (2004) Umbilical portion of recipient's left portal vein: a useful vascular conduit in dual living donor liver transplantation for the thrombosed portal vein. *Liver Transpl* 10: 802-806.
16. Manzia TM, Fazzolari L, Manuelli M, Pellicciaro M, Baiocchi L, et al. (2016) Liver transplantation in a patient with complete portal vein thrombosis, is there a surgical way out? A case report. *Ann Med Surg* 11: 5-8.
17. Gad EH, Abdelsamee MA, Kamel Y (2016) Hepatic arterial and portal venous complications after adult and pediatric living donor liver transplantation, risk factors, management and outcome (A retrospective cohort study). *Ann Med Surgery* 8: 28-39.
18. Manzanet G, Sanjua'n F, Orbis P, López R, Moya A, et al. (2001) Liver transplantation in patients with portal vein thrombosis. *Liver Transpl* 7: 125.
19. Robles R, Fernández JÁ, Hernández Q, Marín C, Ramírez P, et al. (2004) Eversion thromboendovenectomy in organized portal vein thrombosis during liver transplantation. *Clin Transplant* 18: 79-84.
20. Dumortier J, Czyglik O, Poncet G, Blanchet MC, Boucaud C, et al. (2002) Eversion thrombectomy for portal vein thrombosis during liver transplantation. *Am J Transplant* 2: 934-938.
21. Karvellas CJ, Cardoso FS, Senzolo M, Wells M, Alghanem MG, et al. (2017) Clinical Impact of Portal Vein Thrombosis Prior to Liver Transplantation: A Retrospective Cohort Study. *Ann Hepatol* 16: 236-436.
22. Ponziani FR, Zocco MA, Garcovich M, D'Aversa F, Roccarina D, et al. (2012). What we should know about portal vein thrombosis in cirrhotic patients: A changing perspective. *World J Gastroenterol* 18: 5014-5020.
23. Saidi RF, Jabbour N, Li Y, Shah SA (2014) Outcomes of Patients with Portal Vein Thrombosis Undergoing Live Donor Liver Transplantation. *Int J Org Transplant Med* 5: 43-49.
24. Englesbe MJ, Kubus J, Muhammad W, Sonnenday CJ, Welling T, et al. (2002) Portal vein thrombosis and survival in patients with cirrhosis. *Liver Transpl* 16: 83-90.
25. Ghabril M, Agarwal S, Lacerda M, Chalasani N, Kwo P, et al. (2016) Portal vein thrombosis is a risk factor for poor early outcomes after liver transplantation: Analysis of risk factors and outcomes for portal vein thrombosis in waitlisted patients. *Transplantation* 100:126-133.
26. Yerdel MA, Gunson B, Mirza D, Karayalçin K, Olliff S, et al. (2000) Portal vein thrombosis in adults undergoing liver transplantation: risks factors, screening, management, and outcome. *Transplantation* 69:1873-1881.

- 
27. Kim JD, Choi DL, Han YS (2011) An early single-center experience of portal vein thrombosis in living donor liver transplantation: clinical feature, management and outcome. *J Korean Surg Soc* 81: 35-42.
  28. Molmenti EP, Roodhouse TW, Molmenti H, Jaiswal K, Jung G, et al. (2002) Thrombectomy for organized portal vein thrombosis at the time of liver transplantation. *Ann Surg* 235: 292-296.
  29. Doenecke A, Tsui TY, Zuelke C, Scherer MN, Schnitzbauer AA, et al. (2010) Pre-existent portal vein thrombosis in liver transplantation: influence of pre-operative disease severity. *Clin Transplant* 24: 48-55.
  30. Qi X, Dai J, Jia J, Ren W, Yang M, et al. (2015) Association between portal vein thrombosis and survival of liver transplant recipients: a systematic review and meta-analysis of observational studies. *J Gastrointest Liver Dis* 24: 51-59.