

Influence of Horizontal Condylar Angle and X-Ray Projection Angle on the Appearance of the Condyle on Lateral Temporomandibular Joint Panoramic Radiographs

Subash Beloor Vasudeva¹, Norikazu Kaneko², Atsushi Endo³, Tomohiro Okano⁴

¹MDS, BDS. Department of Radiology, Showa University School of Dentistry, Tokyo, Japan. ²RT. Radiology Technician, Department of Radiology, Showa University School of Dentistry, Tokyo, Japan. ³RT, MS. Radiology Technician, Department of Radiology, Showa University School of Dentistry, Tokyo, Japan. ⁴PhD, DDS. Professor, Department of Radiology, Showa University School of Dentistry, Tokyo, Japan.

Abstract

Aims: This study used dried human mandibles and aimed to assess the effect of different horizontal condylar angle and the effect of different beam angles from three different units in the depiction of medial, central and lateral parts of the condyle on panoramic and lateral temporomandibular joint (TMJ) panoramic images.

Methods: Standard panoramic and lateral TMJ panoramic images of four dried human mandibles with horizontal condylar angles of 5, 8, 10, 15, 17 and 20 degrees were analysed. The different parts of the condyle were represented by radiopaque markers. The standard panoramic and lateral TMJ panoramic images of the four mandibles were acquired from three panoramic radiography models with different x-ray beam angle. The images were analysed for the position of these radiopaque markers.

Results: Standard panoramic images demonstrated almost similar images of the condyles in the three panoramic models. The lateral TMJ panoramic images demonstrated the medial pole anterior to the lateral pole when the x-ray projection angle was more than the horizontal condylar angle; superimposition of medial and lateral poles when the x-ray projection angle was equal to horizontal condylar angle; and lateral pole anterior to medial pole when the x-ray projection angle was less than beam projection angle.

Conclusion: This study demonstrated that apart from other factors, the depiction of the mandibular condyle on lateral TMJ panoramic radiographs depends on the horizontal condylar angle, and the x-ray beam angle, which differs among different manufacturers. Therefore these limitations have to be considered when interpreting the integrity of the mandibular condyle on lateral TMJ panoramic radiographs.

Key Words: Standard Panoramic Radiograph, Lateral Temporomandibular (TMJ) Panoramic Radiograph, Horizontal Condylar Angle, X-Ray Projection Angle

Introduction

Panoramic radiography is one of the frequently used imaging tools in dentistry. These radiographs used by almost all branches of dentistry. Panoramic radiographs give information about the teeth and surrounding alveolar bone, which is useful in obtaining general information about a patient's oral health status. Panoramic radiographs also give information about the integrity of structures related to teeth such as maxillary sinus and mandibular condyle [1]. Panoramic radiographs are used very frequently by dentists the world over because of their cost-effectiveness, relatively low radiation

dose to the patient, easy availability of the imaging services, and their ability to depict the teeth and associated structures with a single exposure [2]. However, panoramic radiography also has many drawbacks such as distortion and magnification of the structures [3], and superimposition of other anatomic structures on the teeth and areas such as condyle [4]. Even with these limitations, panoramic radiography is still used routinely by dentists, especially those in the specialty treating temporomandibular (TM) disorders. These images give an overall idea about the integrity of the mandibular condyle. The extensive degenerative changes of

Corresponding author: Dr Subash Beloor Vasudeva, No 9, 1st Cross, RRM Extension, K. H. Road, Bangalore 560027, India; e-mail: subash75adiga@gmail.com

condyle are detected by these images fairly accurately [4,5] and this helps the clinician in planning the management of a patient with a TM disorder. Flattening of the articular surface, obvious bone erosion, osteosclerosis and large osteophytes are the degenerative osseous changes visualised on a panoramic radiograph. Computed tomography (CT) scans and the more recently introduced cone beam computed tomography (CBCT) scans have good sensitivity and specificity in the detection of these osseous changes. The soft-tissue components of the joint, such as the articular disc, are best visualised by magnetic resonance imaging (MRI) scans.

Modern panoramic machines are equipped with TMJ-specific programmes, which help in viewing the condyle, glenoid fossa and associated hard-tissue components of TM joint more clearly compared to the standard panoramic views. These TMJ-specific programmes are called by various names such as lateral TMJ panoramic radiography [3], TMJ scenography [6], and TMJ-specific panoramic radiographs. These projections are similar to the standard panoramic projections except for the x-ray beam angulation. The x-ray beam angulation of the TMJ-specific programmes varies from manufacturer to manufacturer. Standard panoramic projections can be compared to a trans-oblique radiograph for TMJ which is a supracranial view i.e., the x-ray beam projecting the condyle from above, which images the lateral and central part of the condyle clearly when compared to medial part [7]. The standard panoramic view depicts the condyle with shape distortion and magnification [3]. This major limitation of the panoramic radiograph for TMJ imaging is due to the non-orthogonal alignment of the x-ray beam to the long axis of the condyle. The shape and horizontal and vertical angulation of the condyle varies slightly among people belonging to the same ethnicity and varies greatly between people of different ethnicity [8]. These condylar angulations, particularly the horizontal condylar angulation, play a role in the way the condyle appears on a standard panoramic radiograph.

To overcome this limitation, most of the modern panoramic units have TMJ-specific programmes for imaging the TM joint. These programmes take into account the variation in the horizontal angulation of the condyle in the population and have a fixed beam projection angle that aligns the x-ray beam almost orthogonally to the long axis of the condyle. This change in angulation of the x-

ray beam depicts the condyle more clearly compared with the standard panoramic projection. More advanced, sophisticated panoramic units have the option of changing the x-ray beam angle to match the horizontal condylar angle of the patient. This adjustment is done by taking a submento-vertebral projection, from which the horizontal condylar angle can be measured. Based on this angle, the x-ray beam angulation can be set orthogonally to the long axis of the condyle. However, most of the panoramic units do not have this option. The units have a fixed beam angle, which is based on the average horizontal condylar angle of the population.

Specialists treating patients with TM disorders usually rely on the information gathered from the imaging of the TM joint for the diagnosis and subsequent management of the patient. The information gathered from the imaging is also used to assess the outcome of the treatment strategy and follow-up of the patient. Therefore it is important for the clinician to know the amount of information available from these images of the TM joint. Studies assessing the efficacy of panoramic radiographs in the detection of the condylar osseous changes have concluded that panoramic radiographs have low sensitivity and accuracy in detecting these changes [9,10]. One study of human cadavers assessed the influence of horizontal and vertical condylar angulations on appearance of condyle in panoramic images [11]. It showed that the position of the medial and lateral poles of the condyle on panoramic images varies depending on the horizontal condylar angle. However, there is less information in the literature regarding the depiction of various parts of the condyle on lateral TMJ panoramic radiographs. This information will be helpful for the clinician who is interpreting a lateral TMJ panoramic radiograph.

Aim

This study used dried human mandibles and aimed to assess the effect of different horizontal condylar angle and the effect of different beam angle from three different units in the depiction of medial, central and lateral parts of the condyle on panoramic and lateral TMJ panoramic images.

Methods

Four dried human mandibles were used in the study. These mandibles had different horizontal condylar angulations. To measure the horizontal

condylar angulations, the mandibles were imaged such that the x-ray beam was projected directly from above using a general radiography unit (Model KXO-80G; Toshiba, Japan) with a focus-to-object distance of 100 cm. The print-out of the images of these mandibles was taken on a photographic film. Both right and left condyles were traced onto tracing paper. The line connecting the centre of the articulating surface of the right and left condyle represented the intercondylar axis. The line joining the points where the tangents drawn to the medial and lateral contour of the condyle touched the condyles represented the long axis of the condyle. The horizontal condylar angulation was determined by measuring the angle formed by the long axis of the condyle and the intercondylar axis (*Figure 1*). These measurements were carried out on all eight condyles (two per mandible). An orthodontic wire (.025 gauge) was contoured and

attached to the articulating surface of the condyle with adhesive strips and this wire extended from the medial end to the lateral end of the condyle. A 1 mm diameter stainless steel ball was attached to the medial pole of the condyle and a 2 mm diameter stainless steel ball was attached to the lateral pole of the condyle. Similarly, 1 mm and 2 mm diameter stainless steel balls were attached to the articulating surface of the condyle, which represented the medial and lateral part of the articulating surface of the condyle respectively. A thin lead foil was secured to the centre of the articulating surface of the condyle extending antero-posteriorly across the condylar surface to represent the centre of the articulating surface of the condyle (*Figure 2*). The lateral TMJ panoramic radiograph and standard panoramic radiographs of these condyles were made from three different panoramic units (*Table 1*) selecting the lowest exposure parameters. The

Figure 1. Schematic diagram showing the measurement of horizontal condylar angle. θ , horizontal condylar angle; H, long axis of the condyle; I, intercondylar axis.


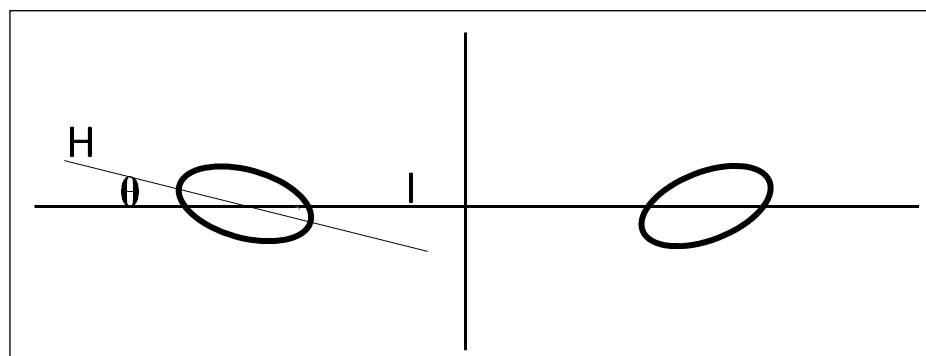


Figure 2. Frontal view of the condyle. Position of stainless steel balls on different parts of the condyle. M (1 mm steel ball), medial pole, MS (1 mm steel ball), medial part of the articulating surface of the condyle; LS (2 mm steel ball), lateral part of the articulating surface of the condyle; L (2 mm steel ball), lateral pole.

Table 1. Three panoramic units with different X-ray beam angle for lateral TMJ panoramic view

Model	Manufacturer	X-ray beam angle for TMJ-specific programmes
Hyper-XF	Asahi Roentgen Company Ltd, Kyoto, Japan	10 degrees
Orthopantomograph OP 200 D	Instrumentarium Dental, Tuusula, Finland	17 degrees
Veraviewepocs 2D	J Morita, Kyoto, Japan	20 degrees

mandibles were attached to a foamed polystyrene sheet and this assembly was attached to the chin rest of the panoramic unit with the help of adhesive tapes. Adjustments were made in the position of the mandible so that the laser light indicating the mid-sagittal plane passed through the contact between the two mandibular central incisors. The condyle was placed 25 mm anterior to the ear rods. This arrangement closely mimicked the closed mouth position in a patient. The TMJ-specific programme was selected in the panoramic unit and the lateral TMJ panoramic exposure was completed. Without changing the position of the mandible, a second exposure was made with the standard panoramic exposure setting. This procedure was carried out on all four mandibles. The images were analysed by two maxillofacial radiologists simultaneously. All the images were evaluated for the position of the medial and lateral poles of the condyle and the depiction of the medial, centre and lateral surfaces of the articulating surface of the condyle. Ethical clearance was not considered necessary for the present study because the mandible specimens analysed were used for educational purposes in the institution.

Results

The horizontal condylar angles of the eight condyles were 5, 8, 10, 10, 15, 17, 20 and 21 degrees. Thus among the eight condyles, two had 10-degree angulation. The analysis of the images showed that there was not much difference in the position of the radiopaque markers on panoramic images. The lateral part of the condyle was visualised on the anterior curvature of the condyle and the medial part on or near the posterior curvature of the condyle and the centre of the articulating surface of the condyle was depicted on the centre of the superior surface of the condyle. This image of the condyle was common for all the different horizontal condylar angles (Figure 3). Analysis of the lateral TMJ panoramic images showed that there was variation in the position of the medial and lateral poles of the condyle. The lateral pole is poste-

rior to the medial pole on lateral TMJ panoramic images when the x-ray projection angle is greater than the horizontal condylar angle (Figure 4a). The medial and lateral poles are superimposed on each other over the surface of the condyle when the x-ray projection angle and horizontal condylar angle are similar (Figure 4b). The lateral pole is placed anterior to medial pole when the x-ray beam angle is less than the horizontal condylar angle (Figure 4c). The medial and lateral parts of the articulating surface of the condyle were depicted on the upper curvature of the condyle in all images with very lit-

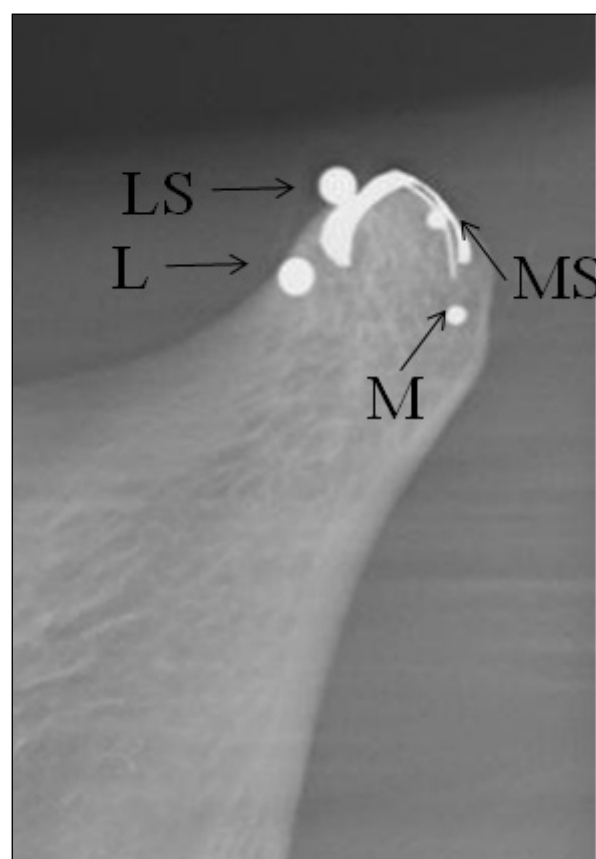


Figure 3. Standard panoramic image showing the position of various parts of the condyle. The lateral part of the condyle is depicted anterior to the medial part. M, medial pole; L, lateral pole; LS, lateral part of the articulating surface of the condyle; MS, medial part of the articulating surface of the condyle.

Figure 4. Effect of X-ray beam angle and condylar angle. Lateral TMJ panoramic image on the left and schematic representation of the projection to the condyle on the right. M, medial pole; L, lateral pole; LS, lateral part of the articulating surface of the condyle

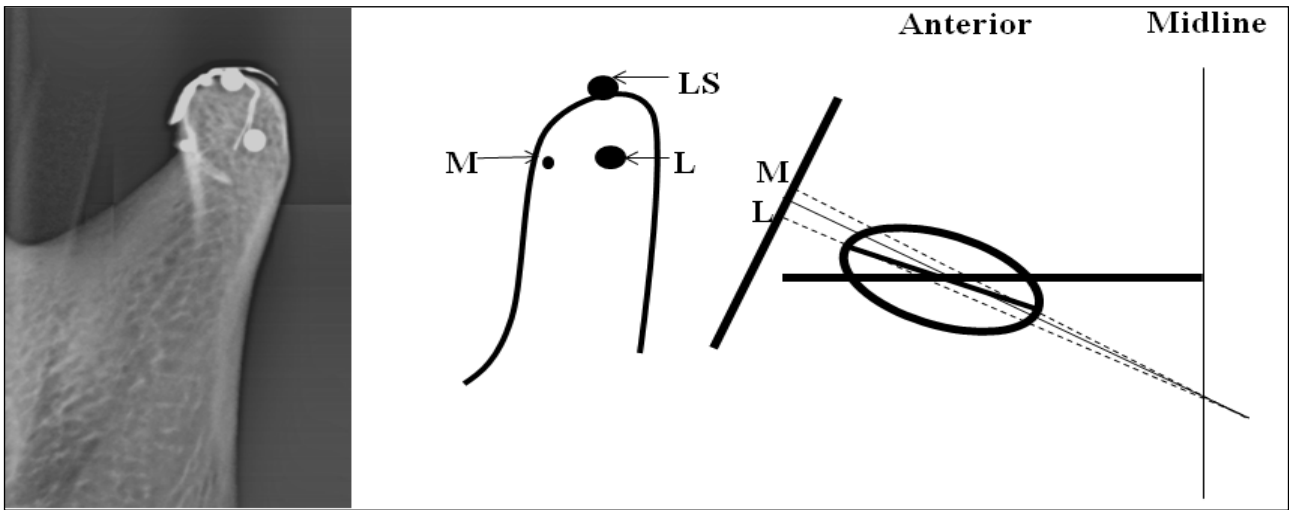


Figure 4a. Beam angle greater than condylar angle, lateral TMJ panoramic image showing the lateral pole posterior to the medial pole.

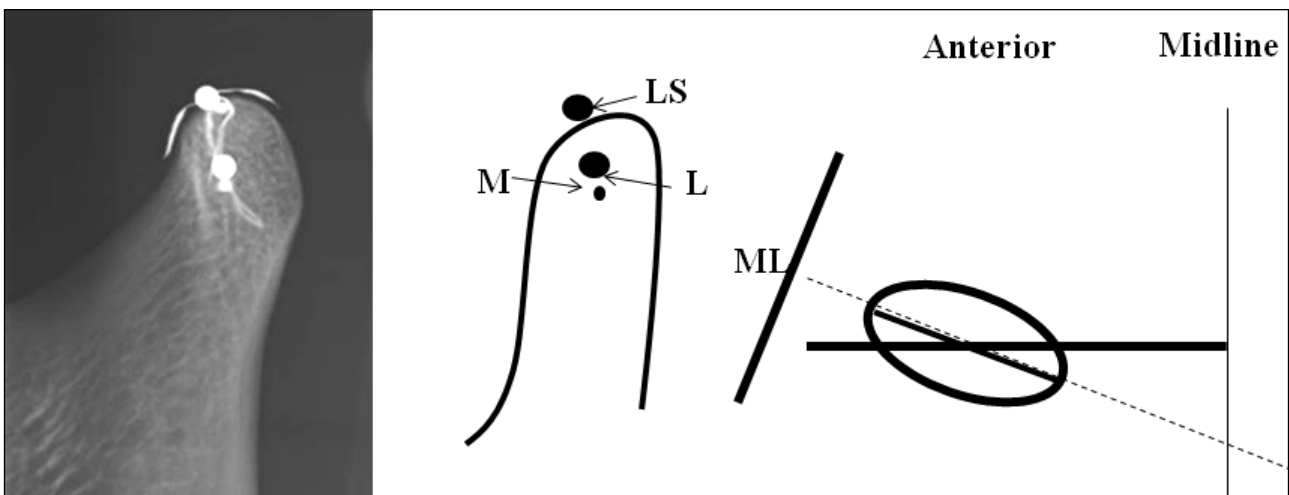


Figure 4b. Beam angle equal to condylar angle, lateral TMJ panoramic image showing the superimposition of lateral and medial pole.

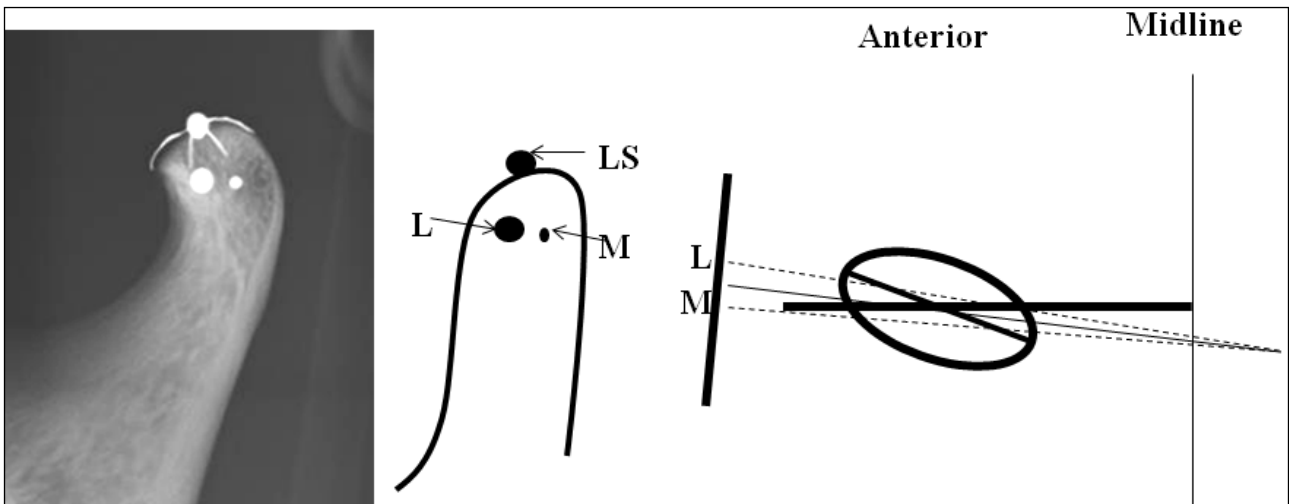


Figure 4c. Beam angle lesser than condylar angle, lateral TMJ panoramic image showing the lateral pole anterior to the medial pole

tle variation. The centre of the articulating surface of the condyle was depicted on the centre of the upper surface on the image in all images.

Discussion

Radiographic depiction of all the components of the TM joint is a challenging task due to its position in the maxillofacial skeleton. The superimposition of the base of the skull region onto the TM joint area makes accurate evaluation of TM joint bony components difficult [5,12]. Clinicians treating patients with TM disorders opt for conventional imaging modalities such as panoramic projection and, more frequently, TMJ-specific panoramic projections for initial evaluation of the components of TM joint. Most modern panoramic units have TMJ-specific programmes for imaging the TM joint. These images differ from standard panoramic images in that they depict the condyle and the articular fossa more clearly. In addition, when taken in open mouth and closed mouth position, these images give information regarding the range of motion of condyle in the articular fossa. The standard panoramic projection is almost similar in most of the panoramic units. The depiction of the condyle will be clear and with minimal distortion if the x-ray beam angle is orthogonal to the condyle i.e., along the long axis of the condyle. The TMJ-specific programmes in different models uses a beam angle that is almost near to the horizontal condylar angle of the population in general. Some panoramic units have the option of measuring the horizontal condylar angle of the patient by taking a submento-vertex projection and exposing the lateral TMJ radiographs with the x-ray beam angle corresponding to the patient's horizontal condylar angle. In the present study, the horizontal condylar angle was measured on the images in which the condyles were exposed by the x-ray projecting directly from above.

Our study analysed the differences in the appearance of different parts of mandibular condyle on both standard panoramic and lateral TMJ panoramic images. In the coronal plane, anatomically the condyle can be divided into a medial part, a lateral part, and the articulating surface of the condyle. Any of these parts can be affected by the disease process, either alone or in combination. Identifying the osseous changes of these parts of the condyle is important in order to decide on the treatment protocol for the patient with a TMJ disorder. In the current study, panoram-

ic radiographs—irrespective of the model—demonstrated similar positioning of the medial and lateral poles and medial, centre and lateral parts of the condyle. The central part was depicted on the centre of the superior surface on the panoramic image, the lateral part on the anterior curvature and the medial part on the posterior curvature of the condyle. In panoramic technique the x-ray beam projects the TM joint as an oblique section [13]. The radiographic image of the TM joint varies with the direction of the x-ray beam. This direction is influenced by factors such as head position, form of the condyle and size of the mandible [13]. Therefore the condyle is projected as an oblique section with medial and lateral parts of the condyle depicted on anterior and posterior parts of the condyle on the panoramic image. The medial pole is placed slightly anterior to the posterior curvature of the condyle on the image. These results are in accordance with another study [13], which used a single dry skull to analyse the accuracy of panoramic imaging in reproducing the TM joint. This oblique x-ray projection makes it difficult to visualise the medial part of the condyle accurately on panoramic projection. The current study demonstrated that the lateral part of the condyle was depicted on the anterior curvature of the condyle with minimal superimposition on to the surface of condyle. The medial pole of the condyle may be superimposed by the posterior part of the condyle which may make this area appear denser simulating an osteosclerosis [13] whereas the lateral part of the condyle is relatively clear without much superimposition and the osseous changes on this part of the condyle can be visualised more easily. The lateral TMJ radiographs can be taken in both closed and open mouth positions. The condylar osseous changes are better visualised on images in open mouth position because of the anterior movement of the condyle in open mouth position. This reduces the superimposition of the temporal component of TM joint on the condyle.

The current study analysed the condyles with different horizontal angulations by lateral TMJ panoramic radiographs. The positions of medial, central and lateral part of the condyle varied according to the horizontal condylar angulations, and the x-ray beam angulation from the panoramic unit. The x-ray beam angulation for lateral TMJ panoramic imaging is different in different panoramic models. Our study demonstrated that the position of the lateral pole of the condyle on lateral

TMJ panoramic images shifted posteriorly and the medial pole was anterior to the lateral pole when the horizontal condylar angle was less than the beam projection angle of the panoramic unit. The distance between the medial and lateral poles decreased with the decrease in the difference between horizontal condylar angle and x-ray beam angle. When the horizontal condylar angle was more than the x-ray beam angle, the lateral pole was projected anteriorly to the medial pole and the distance between the lateral and medial pole decreased as the difference in the angulation decreased. In orthogonal projections i.e. when the x-ray beam angle and the horizontal condylar angles are almost similar, the medial and lateral poles of the condyles superimpose on each other and the lateral part of the condyle is more clearly visualised when compared to the medial part. When the x-ray beam is non-orthogonal to the condyle, the condylar poles are separated by varying distances from each other. When using the 20-degree x-ray beam angle to image the 5-degree angle condyle, the medial pole is slightly anterior to the lateral pole which projects the medial pole anterior to the lateral pole on the image. The medial and lateral poles of the 20-degree condyle are almost at the same level because the x-ray beam is orthogonal to the condyle. When a 10-degree x-ray beam images a 20-degree condyle, the lateral pole of the condyle is anterior to the medial pole relative to the beam and this depicts the lateral pole anterior to the medial pole on the image.

The better visualisation of the lateral part of the condyle than medial part is because the lateral part is closer to the detector than the medial part. This observation is important because when evalu-

ating a lateral TMJ panoramic radiograph. Osseous changes on the medial part of the condyle may go unnoticed leading to false-negative results. The clinician should bear in mind that the detection of condylar osseous changes depends not only on the severity of the changes but also on the position of these changes on the condyle.

Conclusion

This study demonstrated that apart from other factors, the depiction of mandibular condyle on lateral TMJ panoramic radiograph depends on the horizontal condylar angle and the x-ray beam angle, which varies among different manufacturers. Therefore these limitations have to be considered when interpreting the integrity of the mandibular condyle on lateral TMJ panoramic radiographs.

Funding

There was no funding from any external agencies for the study.

Contributions of each author

- SBV designed and performed the study, analysed the results, and prepared the manuscript.
- NK and AE acquired the images.
- TT and TO co-designed and executed the study, co-analysed the results and co-prepared the manuscript.

Statement of conflict of interest

To the best of the authors' knowledge, there is no conflict of interest.

References

1. Ahn SJ, Kim TW, Lee DY and Nahm DS. Evaluation of internal derangement of the temporomandibular joint by panoramic radiographs compared with magnetic resonance imaging. *American Journal of Orthodontics and Dentofacial Orthopedics*. 2006; **129**: 479-485.
2. Habets LLMH, Bezuur JN, Jimenez Lopez V, Hansson TL. The OPG: an aid in TMJ diagnostics. III. A comparison between lateral tomography and dental rotational panoramic radiography (orthopantomography). *Journal of Oral Rehabilitation*. 1989; **16**: 401-406.
3. Mawani F, Lam EWN, Heo G, McKee I, Raboud DW and Major PW. Condylar shape analysis using panoramic radiography units and conventional tomography. *Oral Surgery Oral Medicine Oral Pathology Oral Radiology Endodontology*. 2005; **99**: 341-348.
4. Hussain AM, Packota G, Major PW and Flores-Mir C. Role of different imaging modalities in assessment of temporomandibular joint erosions and osteophytes: a systematic review. *Dentomaxillofacial Radiology*. 2008; **37**: 63-71.
5. Ludlow JB, Davies KL, Tyndall DA. Temporomandibular joint imaging: a comparative study of diagnostic accuracy for the detection of bone change with biplanar multidirectional tomography and panoramic images. *Oral Surgery Oral Medicine Oral Pathology Oral Radiology Endodontology*. 1995; **80**: 735-743.
6. Hintze H, Wiese M and Wenzel A. Comparison of three radiographic methods for detection of morphological temporomandibular joint changes: panoramic, scanographic and tomographic examination. *Dentomaxillofacial Radiology*. 2009; **38**: 134-140.

7. Okeson JP. History of and examination for temporomandibular disorders. In: Okeson JP, editor. *Management of Temporomandibular Disorders and Occlusion*. Missouri, MO: Mosby Elsevier; 2008. p. 216-284.

8. Yale SH, Allison BD, Hauptfuehrer JD. An epidemiological assessment of mandibular condyle morphology. *Oral Surgery Oral Medicine Oral Pathology*. 1966; **21**: 169-177.

9. Dahlstrom L, Lindvall AM. Assessment of temporomandibular joint disease by panoramic radiography: reliability and validity in relation to tomography. *Dentomaxillofacial Radiology*. 1996; **25**: 197-201.

10. Crow HC, Parks E, Campbell JH, Stucki DS and Daggy J. The utility of panoramic radiography in temporomandibular joint assessment. *Dentomaxillofacial Radiology*. 2005; **34**: 91-95.

11. Fallon DS, Fritz GW, Laskin DM. Panoramic imaging of temporomandibular joint: an experimental study using cadaveric skulls. *Journal of Oral and Maxillofacial Surgery*. 2006; **64**: 223-229.

12. Tsiklakis K, Syriopoulos K, Stamatakis HC. Radiographic examination of the temporomandibular joint using cone beam computed tomography. *Dentomaxillofacial Radiology*. 2004; **33**: 196-201.

13. Ruf S, Pancherz H. Is orthopantomography reliable for TMJ diagnosis? An experimental study on a dry skull. *Journal of Orofacial Pain*. 1995; **9**: 365-374.