

Implant-type Tissue-engineered Cartilage for Secondary Correction of Cleft Lip-nose Patients: An Exploratory First-in-human Trial

Kazuto Hoshi^{1,2*}, Yuko Fujihara¹, Hideto Saijo¹, Yukiyo Asawa², Satoru Nishizawa³, Sanshiro Kanazawa², Sakura Uto², Ryoko Inaki², Mariko Matsuyama², Tomoaki Sakamoto², Makoto Watanabe², Madoka Sugiyama¹, Kazumichi Yonenaga¹, Atsuhiko Hikita² and Tsuyoshi Takato^{1,2}

¹Department of Sensory and Motor System Medicine, Graduate School of Medicine, The University of Tokyo, Hongo 7-3-1, Bunkyo-ku, Tokyo 113-8655, Japan

²Division of Tissue Engineering, The University of Tokyo Hospital, Hongo 7-3-1, Bunkyo-ku, Tokyo 113-8655, Japan

³Translation Research Center, The University of Tokyo Hospital, Hongo 7-3-1, Bunkyo-ku, Tokyo 113-8655, Japan

*Corresponding author: Kazuto Hoshi, Department of Sensory and Motor System Medicine, Graduate School of Medicine, The University of Tokyo, Hongo 7-3-1, Bunkyo-ku, Tokyo 113-8655, Japan, Tel: +81-3-5800-9891; E-mail: pochi-ky@umin.net

Received date: June 07, 2017; Accepted date: June 20, 2017; Published date: June 24, 2017

Copyright: © 2017 Hoshi K, et al. This is an open-access article distributed under the terms of the Creative Commons Attribution License, which permits unrestricted use, distribution, and reproduction in any medium, provided the original author and source are credited.

Abstract

Objective: Secondary correction of cleft lip-nose presents a formidable challenge in cleft lip and palate surgery. Although numerous approaches have been proposed, suitable graft materials cannot be obtained from any part of body or the artificial biomaterials. We have established implant-type tissue-engineered cartilage using a porous scaffold comprised of poly L-lactic acid. The aim of this study was to primarily assess the safety of the autologous tissue-engineered cartilage when used in the cleft lip-nose patients as an exploratory first-in-human trial, and to explore the usefulness of the cartilage.

Methods: After the acquisition of institutional and governmental permission, we used this implant-type tissue-engineered cartilage for the treatment of three cleft lip-nose patients. We examined whether or not serious adverse events had occurred by which removal of the tissue-engineered cartilage was needed, 3 years after the transplantation. We also explored the usefulness of the cartilage, as aesthetic and functional outcomes.

Results: Each tissue-engineered cartilage fulfilled the defined release criteria for transplantation. The transplantation of the tissue-engineered cartilage in all the patients was performed just as planned. After 3 years of transplantation, we did not experience any serious adverse events that were related to the tissue-engineered cartilage. As a non-serious adverse event, calcification of the tissue-engineered cartilage was found in one patient. Nose shapes improved in all the patients, and more than 2 mm of nose augmentation maintained for 3 years post-surgery, as measured in cephalogram. Although the dysfunction in facial expression or playing sports had rather increased immediately after the transplantation, the inconvenience generally recovered or improved during the post-surgical course.

Conclusion: The implant-type tissue-engineered cartilage could safely reconstruct the nasal dorsum and apex of cleft lip-noses. This tissue-engineered cartilage possibly leads to effective correction of a severe cleft lip-nose deformity with aesthetic and functional improvement.

Keywords: Tissue engineering; Cartilage; Chondrocyte; Cleft lip and palate; Nose; Scaffold; Secondary correction

Introduction

Cleft lip and palate is one of the most frequent congenital anomalies of the human body shape. One out of 500-3000 births suffer from this disease. Especially, in Japan, the rate of this disease is reported rather higher when compared to that in Africans, Americans, and Caucasians [1]. The standard treatment sequence is lip repair at 3-6 months, palate repair around 12-15 months, which is slightly before the time when active speech begins, and alveolar bone graft between 6-9 years at which upper incisor or canine is erupted [2]. Thereafter, orthodontic treatment is carried out, accompanied by orthognathic surgery if necessary, while secondary lip and nasal correction is done in the patients that continue to suffer from the deformity of a lip scar, narrower nose and nasal asymmetry. This secondary correction of the cleft lip-nose presents a formidable challenge in cleft lip and palate

surgery [3]. In order to achieve nasal symmetry and an improved nasolabial relationship, some straight graft materials with mechanical properties equivalent to that of lateral nasal cartilage or nasoseptal one should be put in the subcutaneous pocket of the nasal dorsum. This would add structural support and achieve the desired nasal projection.

Numerous grafts including autologous bone or cartilage, and artificial materials have been proposed to address the cleft-lip nose deformity [4-7]. However, suitable graft materials that possess a sufficient length and straightness for nasal reconstruction, and appropriate mechanical strength equivalent to the native cartilage, cannot be obtained from any part of the body. The artificial biomaterials including silicone implants have also not been ideal, because of their mechanical incoherence.

Tissue engineering is a novel technology that produces regenerative tissues by the use of a combination of cultured cells and scaffolds [8]. The seeding of expanded cells into the appropriate scaffolds that provide a structural framework with a mechanical strength generates

engineered tissues with clinically relevant sizes and mechanical properties. The regenerative tissues are expected to improve or replace the impaired tissues. If the scaffolds are fabricated to be rod-like shaped and cultured chondrocytes that are placed into the scaffolds can regenerate substantial cartilaginous matrices, it can make a straight tissue-engineered cartilage, which would be the ideal cartilage that repairs the cleft lip-nose deformity. However, in spite of rising expectations for tissue-engineered cartilage using the appropriate scaffolds, its application for patients has not yet been reported in a clinical setting. As conventional regenerative medicine of cartilage, autologous chondrocyte transplantation has been used all over the world to treat and repair the focal defect of articular cartilage [9]. The transplant is generated from a small cartilage biopsy sample taken from the patient through expansion in the presence of specific growth factors or serum, but without application of any scaffolds.

Among the various types of scaffolds, those made of biodegradable polymers effectively provide the regenerative tissues with a good mechanical strength, although those of animal-derived materials, such as collagen and hyaluronan, become fragile when they are placed in water. Many biodegradable polymers have been investigated as the raw materials of the scaffolds [10]. However in reality, the scaffolds of polymers have never been used in a clinical application, because they evoked severe tissue reactions when used in the body [11,12]. Otherwise, after years of research, we found that the use of polymers that undergo a rapid breakdown after transplantation interfered with the maturation of the regenerative cartilage, because it caused a severe foreign body reaction during the immediate period after transplantation, which is a stage that is important for the establishment of cartilage regeneration [13]. We confirmed that poly L-lactic acid (PLLA) with a high purity, which undergoes a relatively slow

biodegradation, reduced the foreign body reaction in the early stage after transplantation [13,14]. Based on these findings, we have established tissue-engineered cartilage with a mechanical strength equivalent to that of the physiological cartilage tissue, using a scaffold system with a porous material comprised of PLLA. We term such a regenerative cartilage as the “implant type”, because it is not injected, but can be surgically implanted in the body [15].

As an exploratory first-in-human trial, we used this implant-type tissue-engineered cartilage for the treatment of three cleft lip-nose patients. We aimed to primarily assess the safety of the autologous tissue-engineered cartilage, 3 years after the transplantation, at a time when the PLLA is almost totally biodegraded. We examined whether or not serious adverse events had occurred by which removal of the tissue-engineered cartilage was needed. We also explored the usefulness of the cartilage, as aesthetic and functional outcomes, using exploratory evaluation indicators, such as improvement of facial features, satisfaction level of patients, and activity of daily life.

Materials and Methods

Study design and patients

We planned to recruit three patients with a nasal deformity caused by cleft lip and palate at the University of Tokyo Hospital (Tokyo, Japan). Table 1 lists the full inclusion and exclusion criteria. This study conformed to the Declaration of Helsinki. It followed the guidelines for clinical research using human stem cells formulated by the Ministry of Health, Labour and Welfare of Japan, and was approved by the Ethics Committee of the University of Tokyo and Minister of Health, Labour and Welfare of Japan. All patients gave written informed consent.

Inclusion criteria	Patients of cleft lip and palate with severe nasal deformity requiring nasal augmentation and nasal tip correction, and with bilateral/lateral deformity in nasal septum
	Age ≥ 20 and <40 years
	Body weight ≥ 40 kg
Exclusion criteria	Classified as Class 3 or higher in the ASA physical status by the American Society of Anesthesiologists
	Possessing or possibly possessing malignant neoplasm
	Suffering from diabetes mellitus
	Possibility of sepsis or bacteremia
	Possibility of recurring infections around the surgical sites (ear or nose)
	Received surgical treatments at the surgical sites (nose or cartilage) within one year before operation
	Pregnant or possibility of pregnancy, and lactating
	Possibility of syphilis, hepatitis B, hepatitis C, human immunodeficiency virus, or adult T cell leukemia
	Suffering or suffered from autoimmune diseases, such as rheumatoid arthritis, psoriatic arthritis, systemic lupus erythematosus, dermatomyositis, polymyositis, Hashimoto's thyroiditis, Graves' disease, polyarteritis, scleroderma, ulcerative colitis, Crohn's disease, Sjögren's syndrome, Reiter's syndrome, or mixed connective tissue disease. Or, having a family member suffering or suffered from those diseases
	Past history of anaphylactic reaction
Past history or possibility of hypersensitivity or allergy to collagen preparations, lactic acid polymer preparations, fibroblast growth factor preparations, insulin preparations, penicillin, and streptomycin	

	Taking following medications within 3 months before collecting autologous blood; FGF-2 preparations, parathyroid hormone preparations, insulin-like growth factor-I preparations, insulin preparations, growth hormone preparations, female hormone preparations (except cosmetics), male hormone preparations, interleukin-1 receptor antagonist, thyroid hormone preparations, vitamin D preparations (except supplements) or steroids preparations (except topical products)
	Unable to fill the questionnaire due to psychiatric disorder
	Judged to be improper by a principal investigator, sub-investigators or the committee for assessing transplantation eligibility.

Table 1: Inclusion and exclusion criteria.

Procedures

Before biopsy of the auricular cartilage, we obtained 800 mL of venous blood from the patients to prepare the autologous serum. The autologous serum was separated using the Serum Collection Set CELLAID® (JMS, Hiroshima, Japan) according to the protocol of the manufacturer. The blood sample was coagulated within the sample bag, then centrifuged at 2000XG for 7 min. Totally, 390 mL of the autologous serum was obtained, which was transported to the Cell Processing Center of the University of Tokyo Hospital, and stored at -30°C before use.

To isolate the chondrocytes, we harvested the autologous auricular cartilage under general anesthesia. The approximately 1 cm long-skin incision was placed on the backside of an ear (Figure 1A). A 5-10 mm cartilage biopsy sample was obtained after exfoliation of the perichondrium (Figure 1B), followed by closure of the skin incision with non-absorbable sutures. At this surgery, we also inserted the silicone implant that had a dome-like shape of 50 mm long, 6 mm wide and 3 mm thick. This shape was identical to that of the implant-type tissue-engineered cartilage. The silicone implant supported the preparation of the transplantation bed in the nasal dorsum. The marginal incision of the bilateral nostrils was connected by a transcolumellar incision (gull-in-flight incision). A pocket was dissected in the nasal dorsum, which allowed direct vision of the cartilaginous and bony vault. Between the medial crura of the bilateral greater ala cartilage, the frontal end of the nasal septum cartilage was found, while bilateral sides of the nasal septum cartilage were dissected on the subperichondral layers. The bilateral lateral nasal cartilage and the nasal septum cartilage were disconnected by surgical scissors and the entire picture of the nasal septum cartilage was exposed. The curved septum, which is usually convexed to the cleft side, was completely removed by a rotary scalpel, maintaining the antero-superior margin of the nasal septal cartilage. The removed cartilage was trimmed and retransplanted between the bilateral medial crura of the ala cartilage for the structural support of the columela. The periosteum on the nasal bones was raised by raspatory to enable the transplant to lie in direct contact. The pocket was opened by a nasal elevator, while the silicone implant was inserted. If necessary, the scar of the upper lip was corrected. The lip switch flap (Abbe flap) was also combined in order to extend the shorter bridge of the nose.

We transported the cartilage biopsy sample to the cell processing center of the University of Tokyo Hospital for transplant manufacturing according to the defined operating procedures. In the cell processing center, the cartilage biopsy sample was cut into pieces and digested in a 0.6% collagenase (Collagenase Type I, Worthington Biochemical Corporation, Lakewood, NJ, USA) solution for 12-24 h at 37°C. The cell count was performed by a NucleoCounter® NC-100TM (Chemometec, Allerød, Denmark) according to a validated procedure and established cell viability using propidium iodide.

After confirming that the number of isolated chondrocytes was greater than 300,000, they were seeded in a gelatin-coated 100-mm plastic culture dishes (Nippi, Tokyo, Japan) at a density of a 1270 cells/cm² and cultured in the DMEM F/12 containing 5% human serum, 100 ng/mL FGF-2, and 5 µg/mL insulin, in a 37°C/5% CO₂ incubator [16]. The medium was changed twice per week. Passages were performed by treatment with TrypLE™ select (Thermo Fisher Scientific, Waltham, USA) when the cells were approaching confluence at day 9-11 of the culture. The cell count was again performed by the NucleoCounter® NC-100TM. We reseeded the chondrocytes at the density of 1270 cells/cm² on the culture dishes, and cultured them for an additional 16-25 days with the same content of culture medium. After the chondrocyte harvest in which the cell number was greater than 240 million (more than 80% cell viability), we placed the expanded cells in the porous body of the PLLA scaffold (pore size: approximately 200 µm, porosity: approximately 95%) with the dome-like shape of 50 mm long, 6 mm wide and 3 mm thick (KRI, Kyoto, Japan) at the density of 10⁸ cells/mL [14]. In order to hold the cells within the scaffold, atelocollagen hydrogel (Atelocollagen implant, Koken, Tokyo, Japan) was mixed with the harvested chondrocytes before application to the porous scaffold [17]. The mixture of the chondrocytes and atelocollagen gradually penetrated into the scaffold using a pipetter. We prepared two constructs of the tissue-engineered cartilage per patient, designated as the original and duplicate (Figure 1C).

We undertook regular sterility controls throughout the manufacture. Bacterium, fungus and micoplasma tests were done for the culture media of each patient in the microbiology laboratory; one after collagenase digestion, one in the subculture, one at cell harvest, and every time of medium changes. Quality control tests for release of the transplants included establishment of the absence of any contamination of the culture media, less than 333 EU/mL of endotoxin measured by ELISA, confirmation of a white and glossy visual appearance on the transplant, and structural stability by a cantilever test in which one end of dome-shaped construct was picked up with tweezers and the construct was tried to be horizontally held in the air, checking for less than a 13 mm drooping at the other end. Based on these criteria, two constructs were shipped, one of which was transplanted by the surgeons.

For four to five weeks after biopsy of the auricular cartilage, under the general anaesthesia, the silicone implant in the subcutaneous pocket of the nasal dorsum was removed from the same gull-in-flight incision. Following the sufficient perfusion of saline, the tissue-engineered cartilage construct was inserted in the subcutaneous pocket without any trimming of the construct (Figure 1D). Very close attention was paid in order to avoid destruction of transplant.

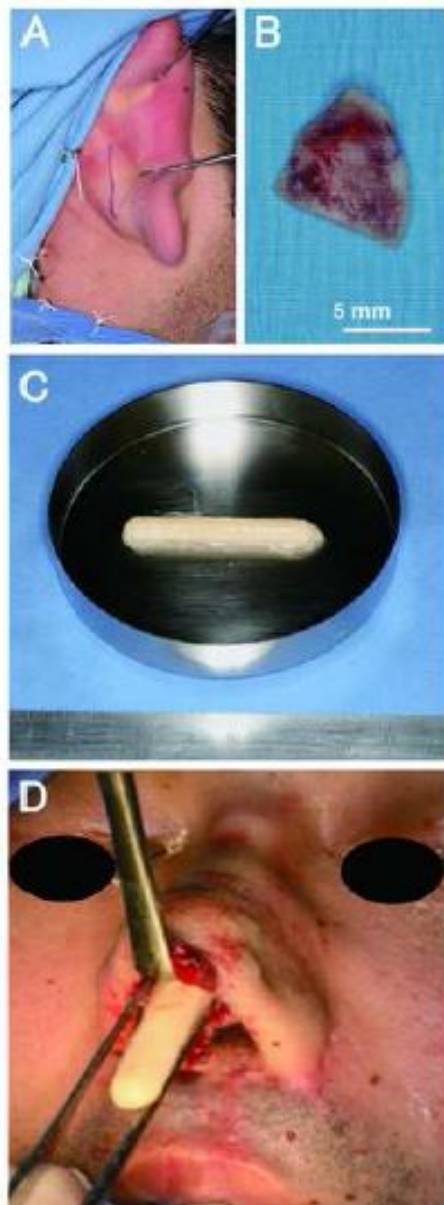


Figure 1: Production and transplantation of implant-type tissue-engineered cartilage. An auricular cartilage (5-10 mm) fragment was obtained from a 1-cm incision in the backside of the patient's ear and was used as a cell source for the engineered tissue (A and B). The tissue-engineered cartilage had a dome-like shape, with 5 cm long, 6 mm wide and 3 mm thick (C). It was inserted into the nasal dorsum (D).

Outcomes

The primary outcome of this study was safety that was confirmed based on the incidence of serious adverse events requiring the removal of the tissue-engineered cartilage after transplantation, due to pain, infection, graft failure or other reasons. As the secondary outcome, the effectiveness was additionally assessed based on exploratory evaluation

indicators, such as improvement of facial features, satisfaction level of patients, and activity during daily life. We examined the improvement of facial features as the degree of nasal augmentation in the lateral views of the roentgenographic cephalogram. Before and 3 months, 6 months, 1 year, 2 years, and 3 years after the nasal reconstruction, we took roentgenographic cephalograms. In the lateral views, the skin surface line was outlined. The Frankfort horizontal plane was assigned to the X axis and the vertical was assigned to the Y axis. The Frankfort horizontal plane and nasion were matched between the trace of the cephalograms before and after nasal reconstruction, and the distance in the X direction of the skin surface lines was measured at the interval of 5 mm in the Y direction.

The patient satisfaction was measured by self-assessment using the Darriford Appearance Scale 59 (DAS59), Japanese version [18]. The DAS59 indicated factorial sub-scores (general self-consciousness of appearance, social self-consciousness of appearance, sexual and bodily self-consciousness of appearance, negative self-concept, and facial self-consciousness of appearance). Depression was evaluated by the Self-rating Depression Scale (SDS), Japanese version [19]. The activity of daily life was evaluated by self-assessment with the visual analogue scale in terms of blowing nose, lying face down, forcefully breathing through the nose, no restriction to facial expression, washing face without difficulty, wearing glasses without difficulty, and playing rough sports, all of which are possible complaints after conventional treatment by the secondary open rhinoplasty using autologous iliac bones [20].

These outcomes were assessed by 36 months of transplantation. This study was registered with the UMIN-CTR, number UMIN000005472.

Results

Between Dec 13, 2010 and Feb 6, 2012, we enrolled one woman and two men aged 21-25 years who presented with either right cleft lip, left cleft lip and palate, or bilateral cleft lip and palate. For obtention of autologous serum, a total of 800 mL of whole blood was taken from either patient #1 or #2. The blood was collected twice or three times. In the patient #3, the date of transplantation for the tissue-engineered cartilage was postponed for one week, due to deterioration of the nasal acune. Accompanied with elongation of the culture period, a 400-mL blood collection was added. After the blood collection, no patients showed anemia.

The sufficient number of chondrocytes was isolated from the auricular cartilage biopsy samples (#1, 2.10×10^6 viable cells from 0.23 g auricular cartilage, #2, 5.25×10^5 cells: 0.08 g, and #3, 2.36×10^6 cells: 0.44 g) after collagenase digestion. Expansion of the chondrocytes led to a mean of 1.14 billion cells per patient (patient #1 1.20 billion in viable cell number and 97.7% in viability, #2, 1.50 billion, 98.0%, #3, 0.732 billion and 87.1%) (Figure 2). The cell numbers were more than sufficient for the production of two tissue-engineered cartilage constructs per patient. Sterility tests during the manufacturing process showed no microbiological or mycoplasma contamination for any batches. All the constructs of the implant-type tissue-engineered cartilage on shipping maintained the initial scaffold size and shapes and had a white and glossy appearance. The cantilever tests had proved sufficient mechanical strength for all the constructs. They were sufficiently stable when manipulated with tweezers. Therefore, each tissue-engineered cartilage fulfilled the defined release criteria for transplantation.

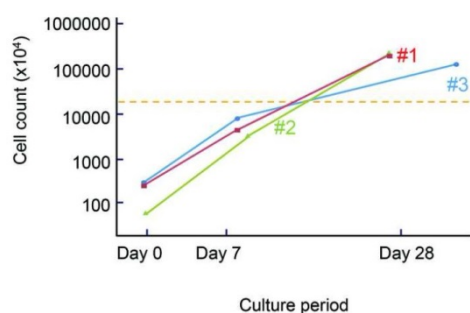


Figure 2: Growth curve of cultured auricular chondrocytes from the patients. In all patients, the cell numbers were greater two hundred forty million at around one month, which was the goal of the culture.

The transplantation of the tissue-engineered cartilage in all the patients was performed just as planned. During the insertion of the tissue-engineered cartilage in patient #1, the original construct was kinked due to an excessive load on the tissue-engineered cartilage. We carefully placed the duplicate construct and it was adequately transplanted. To improve the aesthetic outcome in all of the patients, the scar of the upper lip was corrected. A lip-switch flap was added in patient #2 in order to gain the volume for the upper lip. Only in patient #3, because deterioration of nasal acune was found immediately before date of elective surgery for transplantation, the date was postponed for 1 week for the purpose of avoiding surgical site infection. The construct was transplanted 5 weeks after the biopsy in this patient.

By 3 years of transplantation, we had not experienced any serious adverse events that were related to the tissue-engineered cartilage. As a non-serious adverse event, calcification in the tissue-engineered cartilage was found in patient #3. No obvious pain or itch had been complained of in and around the nose and mouth of all the patients during the observation period.

In order to evaluate the improvement in the facial features, we measured the degree of nose augmentation by comparing the lateral views of the roentgenographic cephalogram between before and after the transplantation. In all the patients, more than 2 mm of augmentation was observed at 3 months after transplantation, and maintained for 3 years post-surgery (Figure 3).

Patient satisfaction and improvement from the psychological distress and dysfunction that is characteristic of disfigurements, deformities and aesthetic problems of appearance were evaluated by DAS59. The score of the general self-consciousness of appearance was shown to gradually improve within 3 years in all the patients. Other scores also tended to improve, suggesting that patient satisfaction likely went up (Figure 4A). The mental status, especially depression, of the patients was analyzed by SDS. Patient #1 showed an increase in the SDS score, although in the other patients, they were maintained or improved after transplantation of the tissue-engineered cartilage (Figure 4B).

As for the activity of daily life, inconvenience regarding the patient's nose was evaluated by VAS. Principally, the patients had not complained very much of any inconvenience at pre-surgery, although the dysfunction in facial expression or playing sports had rather increased immediately after the transplantation. However, the

inconvenience generally recovered or improved during the post-surgical course (Figure 5).

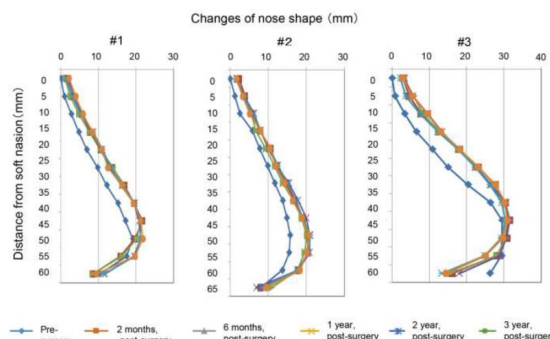


Figure 3: Nose augmentation evaluated by cephalogram. In the lateral images, the shape of the soft tissue was blotted. The Frankfurt horizontal plane was assigned the X axis, while the vertical was assigned the Y axis.

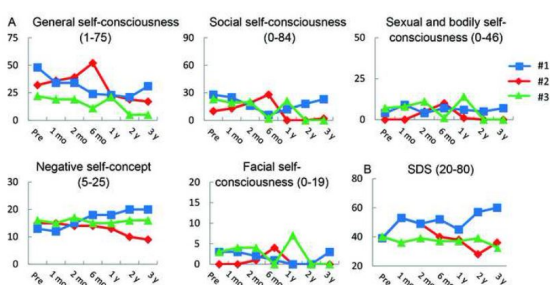


Figure 4: Patient satisfaction and mental status. The factorial subscores in DAS59 are between 1-75 in general self-consciousness of appearance, 0-84 in social self-consciousness of appearance, 0-46 in sexual and bodily self-consciousness of appearance, 5-25 in negative self-concept, and 0-19 in facial self-consciousness of appearance. The patient satisfaction goes up as the scores decrease. The SDS score ranged between 20 and 80. Greater than 55 suggest depression.

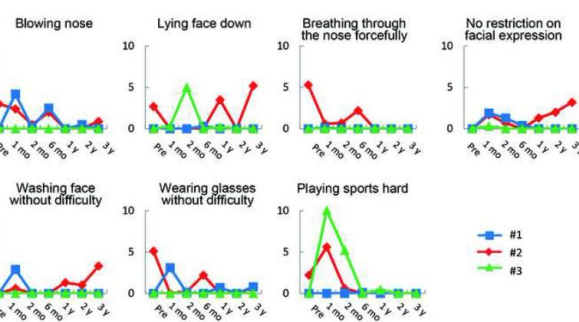
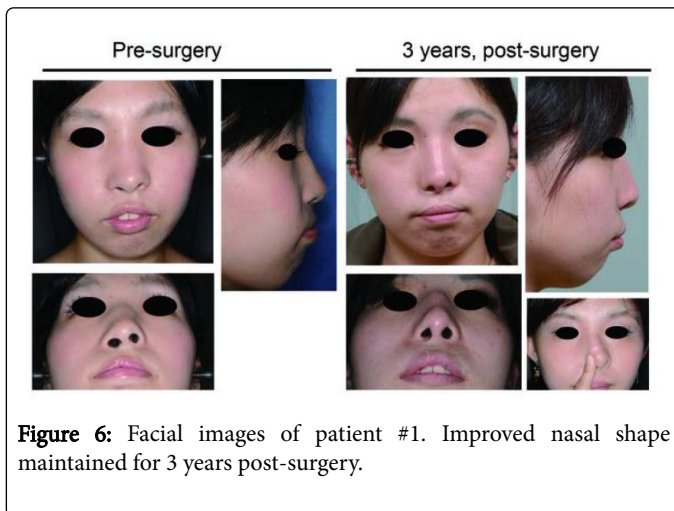

Figure 5: Inconvenience regarding the patient's nose evaluated by VAS. Zero is the best condition, while 10 is the worst.

Patient presentation

A twenty-five year old female (patient #1) was suffering from a right cleft lip. Three years post-surgery, the shape of nose was improved (Figure 6). The nose after transplantation was sufficiently elastic (Figure 6, bottom right).



One year and six months post-surgery, we did a secondary correction of the lip and nasal ala as the patient requested. At that time, a little sample of the transplanted tissue-engineered cartilage could be obtained in the vicinity of the nasal apex, and was pathologically examined. In the HE staining, the cells were surrounded by abundant matrices and formed lacunae, while deep metachromagia from toluidine blue staining showed a substantial accumulation of proteoglycan in the extracellular matrices, indicating cartilage regeneration (Figure 7A and B).

The twenty-one year old male (patient #2) was suffering from a bilateral cleft lip and palate. In addition to transplanting the tissue-engineered cartilage, a lip switch flap was performed, resulting in an improved nose shape (Figure 8, top portion). Patient #3 was a 22-year old male suffering from a left cleft lip and palate. The nasal shape was also improved (Figure 8, bottom portion).

In this patient, we observed calcified material that might have been caused by a previous operation before this surgery (Figure 9, Pre-surgery). We removed the calcified material and then transplanted the tissue-engineered cartilage. However, 6 months post-surgery, calcification was again detected, while it did not disappear by 3 years (Figure 9). Although the patient felt no pain or itch, we continue to carefully follow this concern.

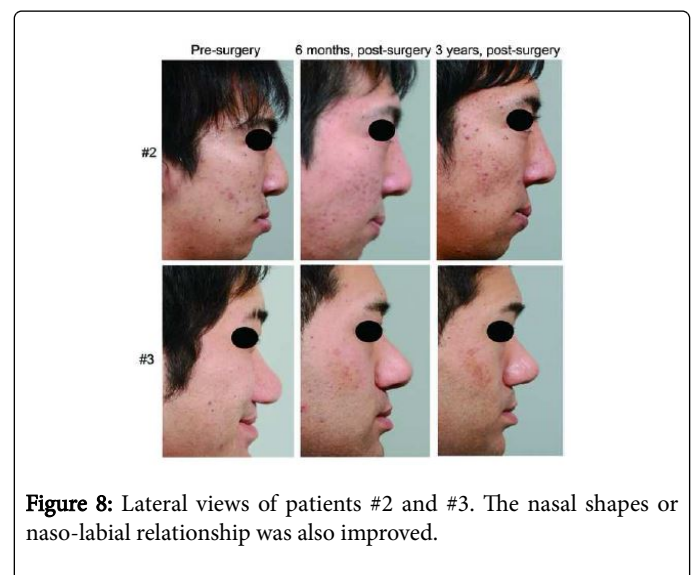
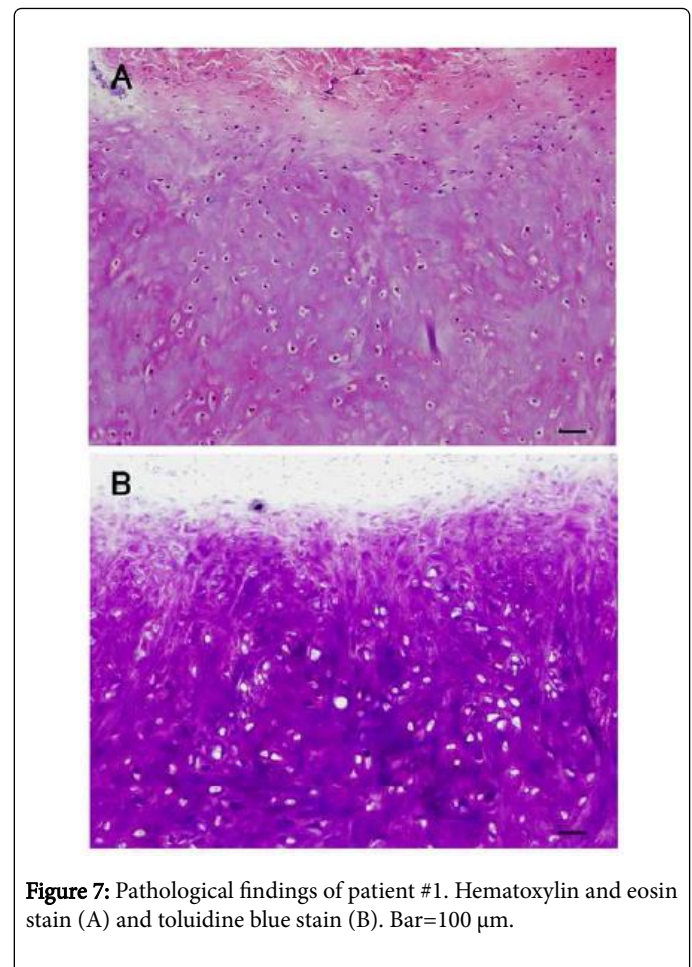
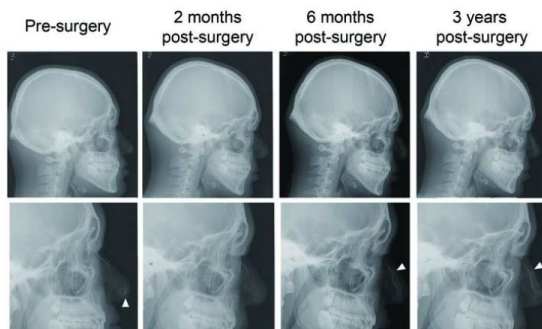



Figure 9: Evaluation by X rays (patient #3). Arrowheads indicate calcification of pre-and post-surgery.

Discussion

For the reconstructive purposes of a cleft lip-nose deformity, the subcutaneous tissue of the nasal dorsum had classically been elevated by iliac bones, costal cartilage or an auricular one, because of its capacity to resist contraction, improve contouring, and increase the height and volume of the nose [4,21]. Notably, chondrocyte-based products in clinical use for articular cartilage repair consist of cell suspensions or of cells mixed with animal-derived biomaterials [22]. However, they do not possess a 3D structure and firmness, or were not formed by an abundant cartilaginous extracellular matrix, which insufficiently met with the conditions for the transplants used in the reconstruction of the cleft lip-nose deformity. Thus, the tissue-engineered cartilage using the biodegradable polymer scaffold was expected as an alternative of conventional transplants.

To clinically assess the tissue-engineered cartilage as an alternative, protocols for the production of structurally stable transplants should be first validated. To obtain an acceptable quality and reproducibility of the tissue-engineered cartilage, we had preclinically determined the content of the media supplements for cell expansion [16], investigated the optimal composition and structure of the scaffold [14], and a suitable density of cell seeding within the porous three-dimensional scaffolds [17]. These findings were embedded within the manufacturing protocol of this cartilage. In this study, the tissue-engineered cartilage met all the criteria of quality control in every patient, which suggested that the protocol worked well.

Our first-in-human clinical trial suggested that use of autologous tissue-engineered cartilage using the PLLA scaffold in the secondary correction of the cleft lip-nose was safe, because we did not observe any serious adverse event such that the tissue-engineered cartilage was removed due to infection, allergy, tumorigenicity, or some other reasons, in our small cohort. Regarding the tumorigenicity, we never experienced any abnormal swelling or formation of nodules, either of which suggested the formation of a tumor. As previous studies of clinical results on regenerative therapy using autologous chondrocytes [23] reported no findings related to sarcomas, we do not consider this issue a high priority.

In this study, the biodegradation of PLLA could not be evaluated, because there were no invasive methods to analyze the volume or the molecular weight of PLLA scaffold in the patients. The PLLA is slowly degraded and it takes more than several years to disappear from the

body after transplantation [24]. The influence by disappearance of the PLLA should be thoroughly investigated in a future clinical study from various standpoints of tissue reaction, mechanical strength, progression of deformity, or histological changes. Especially, the nasal deformity accompanied with the PLLA biodegradation might be one issue to be carefully observed during the post-surgical course. However, the percentage of PLLA scaffold in total volume of transplant was low enough to be less than 5%, considering the porosity of the scaffold. We speculate that the space in which the PLLA was degraded was filled with fibrous tissue [25,26]. If the PLLA space is replaced by fibrous tissues, its percentage will be less than 5% and have little impact on the whole size of the constructs. As aseptic inflammation had been reported to occur more than 5 years after surgery in the case of using PLLA reconstruction plates [11], we continue with a longer observation. However, we hardly have an acute anxiety about it, because the reaction to PLLA seems polymer volume-dependent and the content of the PLLA to the whole transplant was very low.

As a non-serious event, calcification in the transplants was found in one patient of this series. It decreased the elasticity of the nose and may cause some complaints around the nose apex. We have to carefully follow the development of the symptoms or changes in the size and density of the calcification. The mechanisms of the calcification remain unknown yet. The calcification material, which was speculated as calcified autologous cartilage, had already been present in the subcutaneous tissue of the nose apex since pre-surgery. Although a presurgical blood test disclosed normal concentration of serum calcium and inorganic phosphate, the specific circumstances by which local calcification occurred in the nose apex must continue to be investigated. In that patient, the period of chondrocyte culture was one week longer than that of other patients, because the transplantation of tissue-engineered cartilage was postponed, due to local deterioration of the acune. The decrease in cell viability, following severe inflammation in the body, produces calcification in the case of frozen shoulders [27]. Although the chondrocyte viability had been ranged acceptable in the shipping test of the tissue-engineered cartilage in patient #3, the influence on chondrocytes by long-term culture may not be excluded as one of the causes.

Correction of the nasal shapes, represented by augmentation of the nasal dorsum, was satisfactory in our clinical study (Figure 3). The effect of augmentation was noticed immediately after transplantation and had maintained for 3 years. The degree of augmentation contained some variation depending on the patients. Although the thickness of the transplants was 3 mm, one out of three patients (Figure 3, #1) seemed to have more than a 5-mm augmentation from 2 months of surgery. This gain may contain an oblique effect, by which the changes in the X direction between the two lines before and after surgery were overestimated, when compared with the original thickness that corresponded to the shortest distance of these two lines. Actually, the angle of the nasal dorsum to the Y axis was more oblique in patient #3 compared to those in patients #1 and #2 (Figure 3). In contrast, only one patient indicated an approximately 2 mm augmentation (Figure 3, #2), and it may be less than the original thickness of the cartilage transplants. This discrepancy may be due to compensation by the elasticity of the soft tissue around the transplant.

The deposition of the cartilaginous matrix after transplantation was substantial in the transplant, as shown in Figure 7. It suggested that the cells seeded within the scaffold possessed the ability to produce the cartilage matrices, even after long-term culture. As the turnover of the cartilage matrices were regarded to very much slower compared to that

of bones [28,29], the regenerated cartilage is expected to maintain its shape and mechanical strength for a longer period. Thus, the transplantation of tissue-engineered cartilage was regarded sufficient to provide an adequate and durable reconstruction of the nose apex and dorsum. The amelioration of the nose shapes in the cleft lip-nose patients, including the equalization of asymmetry in the bilateral nasal ala, augmentation and straightening of the nasal dorsum, as well as improvement of the nasolabial relationship suggested a sufficient mechanical strength of the tissue-engineered cartilage.

Although the patient number was very low in this study, and DAS59 hardly showed a statistically significant difference, it tended to show improvement in the general self-consciousness of appearance, suggesting the usefulness of this cartilage. In function, nose blowing or breathing through the nose became easier post-surgery compared with that before surgery (Figure 5). Because there were no reference values for the quantitative tests, we should confirm the usefulness of the cartilage compared with the counterpart of conventional treatment, such as cantilever reconstruction of the cleft lip-nose using autologous iliac bones, in future.

One of the advantages in this cartilage was considered to be a decrease in the donor-site morbidity. In this procedure, the surgical wound on the donor site was confined to be approximately 1 cm (Figure 1A), and persistent pain and deformity of the auricles were not problems for either patient. Compared with conventional treatment using autologous iliac bones in which the wound is usually more than 5 cm long, the wound from the auricular cartilage biopsy was much smaller. As iliac bone application evokes severe pain and temporary gait disturbance [30], the post-surgical influence was really diminished in the treatment with the tissue engineered cartilage.

In conclusion, we have reported for the first time that tissue-engineered cartilage can safely reconstruct the nasal dorsum and apex of cleft lip-noses. This tissue-engineered cartilage will possibly lead to effective correction of a severe cleft lip-nose deformity with aesthetic and functional improvement. Our study has opened the way to a confirmatory trial in which the long-term outcome of this procedure will be investigated in multiple institutes. To realize this, further studies will be needed in the field of a preservation method or a carry-in-and-out system for 3D tissue-engineered constructs containing a numerous number of cells.

Acknowledgement

We appreciate Dr. Hirokazu Tsuno, Mr. Yutaka Nagura and Dr. Ryo Orii for their valuable support in the blood sampling or general anaesthesia, and Mr. Motohiro Harai for his useful discussion about quality control and the delivery system. We also thank Dr. Misaki Takei and Ms. Michiko Ishihara for their technical assistance. This study was supported by Grants-in-Aid for Medical Research and Development Programs Focused on Technology Transfer (AMED A-STEP, D07-05), and Research Project for Practical Applications of Regenerative Medicine (AMED).

References

1. Natsume N, Kawai T (1986) Incidence of cleft lip and cleft palate in 39,696 Japanese babies born during 1983. *Int J Oral Maxillofac Surg* 15: 565-568.
2. de Ladeira PR, Alonso N (2012) Protocols in cleft lip and palate treatment: systematic review. *Plast Surg Int* 2012: 562892.

3. Pawar SS, Wang TD (2014) Secondary cleft rhinoplasty. *JAMA Facial Plast Surg* 16: 58-63.
4. Takato T, Yonehara Y, Mori Y, Susami T (1995) Use of cantilever iliac bone grafts for reconstruction of cleft lip-associated nasal deformities. *J Oral Maxillofac Surg* 53: 757-762.
5. Bashir M, Malik A, Khan FA (2011) Comparison of suture and graft techniques in secondary unilateral cleft rhinoplasty. *J Craniofac Surg* 22: 2172-2175.
6. Masuoka H, Kawai K, Morimoto N, Yamawaki S, Suzuki S (2012) Open rhinoplasty using conchal cartilage during childhood to correct unilateral cleft-lip nasal deformities. *J Plast Reconstr Aesthet Surg* 65: 857-863.
7. Balaji SM (2013) Costal cartilage nasal augmentation rhinoplasty: Study on warping. *Ann Maxillofac Surg* 3: 20-24.
8. Jafari M, Paknejad Z, Rad MR, Motamedian SR, Eghbal MJ, et al. (2017) Polymeric scaffolds in tissue engineering: a literature review. *J Biomed Mater Res B Appl Biomater* 105: 431-459.
9. Jiang YZ, Zhang SF, Qi YY, Wang LL, Ouyang HW (2011) Cell transplantation for articular cartilage defects: principles of past, present, and future practice. *Cell Transplant* 20: 593-607.
10. Asghari F, Samiei M, Adibkia K, Akbarzadeh A, Davaran S (2017) Biodegradable and biocompatible polymers for tissue engineering application: a review. *Artif Cells Nanomed Biotechnol* 45: 185-192.
11. Bergsma JE, de Bruijn WC, Rozema FR, Bos RR, Boering G (1995) Late degradation tissue response to poly(L-lactide) bone plates and screws. *Biomaterials* 16: 25-31.
12. Cao Y, Rodriguez A, Vacanti M, Ibarra C, Arevalo C, et al. (1998) Comparative study of the use of poly(glycolic acid), calcium alginate and pluronics in the engineering of autologous porcine cartilage. *J Biomater Sci Polym Ed* 9: 475-487.
13. Asawa Y, Sakamoto T, Komura M, Watanabe M, Nishizawa S, et al. (2012) Early stage foreign body reaction against biodegradable polymer scaffolds affects tissue regeneration during the autologous transplantation of tissue-engineered cartilage in the canine model. *Cell Transplant* 21: 1431-1442.
14. Tanaka Y, Yamaoka H, Nishizawa S, Nagata S, Ogasawara T, et al. (2010) The optimization of porous polymeric scaffolds for chondrocyte/atelocollagen based tissue-engineered cartilage. *Biomaterials* 31: 4506-4516.
15. Hoshi K, Fujihara Y, Asawa Y, Nishizawa S, Kanazawa S, et al. (2013) Recent trends in cartilage regenerative medicine and its application to oral and maxillofacial surgery. *Oral Sci International* 10: 15-19.
16. Takahashi T, Ogasawara T, Kishimoto J, Liu G, Asato H, et al. (2005) Synergistic effects of FGF-2 with insulin or IGF-I on the proliferation of human auricular chondrocytes. *Cell Transplant* 14: 683-693.
17. Yamaoka H, Tanaka Y, Nishizawa S, Asawa Y, Takato T, et al. (2010) The application of atelocollagen gel in combination with porous scaffolds for cartilage tissue engineering and its suitable conditions. *J Biomed Mater Res A* 93: 123-132.
18. Harris DL, Carr AT (2001) The Derriford Appearance Scale (DAS59): a new psychometric scale for the evaluation of patients with disfigurements and aesthetic problems of appearance. *Br J Plast Surg* 54: 216-222.
19. Zung WW (1965) A Self-Rating Depression Scale. *Arch Gen Psychiatry* 12: 63-70.
20. Yonehara Y, Takato T, Matsumoto S, Mori Y, Nakatsuka T, et al. (2000) Correction of cleft lip nasal deformity in Orientals with a cantilevered iliac bone graft. *Scand J Plast Reconstr Surg Hand Surg* 34: 137-143.
21. Ortiz Monasterio F, Ruas EJ (1989) Cleft lip rhinoplasty: the role of bone and cartilage grafts. *Clin Plast Surg* 16: 177-186.
22. Marlovits S, Zeller P, Singer P, Resinger C, Vecsei V (2006) Cartilage repair: generations of autologous chondrocyte transplantation. *Eur J Radiol* 57: 24-31.
23. Wood JJ, Malek MA, Frassica FJ, Polder JA, Mohan AK, et al. (2006) Autologous cultured chondrocytes: adverse events reported to the United States Food and Drug Administration. *J Bone Joint Surg Am* 88: 503-507.

24. Walton M, Cotton NJ (2007) Long-term in vivo degradation of poly-L-lactide (PLLA) in bone. *J Biomater Appl* 21: 395-411.
25. Fujihara Y, Takato T, Hoshi K (2010) Immunological response to tissue-engineered cartilage derived from auricular chondrocytes and a PLLA scaffold in transgenic mice. *Biomaterials* 31: 1227-1234.
26. Fujihara Y, Takato T, Hoshi K (2014) Macrophage-inducing FasL on chondrocytes forms immune privilege in cartilage tissue engineering, enhancing in vivo regeneration. *Stem Cells* 32: 1208-1219.
27. ElShewy MT (2016) Calcific tendinitis of the rotator cuff. *World J Orthop* 7: 55-60.
28. Maroudas A (1975) Glycosaminoglycan turn-over in articular cartilage. *Philos Trans R Soc Lond B Biol Sci* 271: 293-313.
29. Parfitt AM (2000) The mechanism of coupling: a role for the vasculature. *Bone* 26: 319-323.
30. Tuchman A, Brodke DS, Youssef JA, Meisel HJ, Dettori JR, et al. (2016) Iliac Crest Bone Graft versus Local Autograft or Allograft for Lumbar Spinal Fusion: A Systematic Review. *Global Spine J* 6: 592-606.