

Hla Typing in Epidermolysis Bullosa Patients: Relevancy to Gluten Sensitivity

Annicchiarico G^{1*}, Morgese MG^{2,3}, Fiore T⁴, Mauro S⁵, Garofalo L⁶, Aceto G⁷, Tampoia M⁸, Bonamonte D⁶, Minelli M⁹ and Brunetti L⁷

¹Regional Coordination for Rare Diseases- Ares Puglia, Via Caduti di tutte le Guerre 15, 70125 Bari, Italy

²Residency Program of Hospital Pharmacy, University of Bari "A. Moro", Via Orabona 4, 70124, Bari, Italy

³Department of Experimental and Clinical Medicine, University of Foggia, Viale L. Pinto 1, 71122 Foggia, Italy

⁴Department of Anaesthesia and Intensive Care, University of Bari "A. Moro", Piazza Giulio Cesare, 11, 70124 Bari, Italy

⁵Department of Genetics, Hospital of Lecce "Vito Fazzi", P. F. Muratore - 73100 Lecce, Italy

⁶Department of Biomedical Science and Oncology-Section of Dermatology, University of Bari "A. Moro", Piazza Giulio Cesare, 11, 70124 Bari, Italy

⁷Department of Paediatrics, Biomedicine of Developing Age, "B. Trambusti", University of Bari "A. Moro", Piazza Giulio Cesare, 11, 70124 Bari, Italy

⁸Department of Clinical Pathology, University of Bari "A. Moro", Piazza Giulio Cesare, 11, 70124 Bari, Italy

⁹Outpatient Service of Clinical Immunology and Allergology, City of Lecce Hospital - GVM Care & Research, Via Prov. per Arnesano km 4, 73100 Lecce Italy

Abstract

Background: Epidermolysis bullosa (EB) is an inherited genetic disease affecting skin adhesion at dermal or epidermal level or in the basement membrane zone. EB is present in three major forms: simplex, junctional and dystrophic. This latter is very often associated to non-cutaneous manifestation such as gastrointestinal complication and renal damage. Aim of this study was to classify EB patients based on an assigned severity score and individuate precipitating factor, such as HLA predisposing to gluten sensitivity, responsible of the different course of the extracutaneous manifestation of the pathology.

Methods: By using a cross sectional design, 36 EB patients were screened based on the Birmingham severity score and HLA typing was performed in order to discover possible associations. HLA typing test was performed by PCR and statistical method of analysis was the χ^2 test. Controls (n=341) were healthy volunteer subjects.

Results: From a total of 36 patients, 24 were diagnosed of the more sever form of EB, the dystrophic one. The assigned scores ranged from 11 to 90, while the 12 simplex patients received a score from 0-2. In regard to HLA typing, we found that in EB patients the 21.62% expressed a DQ2.2 HLA, while controls only 5.87% ($P < 0.0005$ χ^2 test). No statistically significant difference was found among the other aplotypes.

Conclusion: Although, no difference was found in regard to HLA-DQ2.5, the strongest aploptype associated to celiac disease, we found that in EB patient there was a higher incidence of HLA-DQ2.2 that in a condition of chronic intestinal inflammation, as in these patients is likely to be, may predispose to sensitivity to gluten ultimately leading to immune mediated-organ damage.

Keywords: Epidermolysis bullosa; Inflammation; Gluten free diet; HLA

Background

Epidermolysis bullosa (EB) is a family of severe skin adhesion defects, namely genodermatoses, characterized by disruption of the epidermal-dermal junction. EB may be present as dominant or recessive autosomal, and is generally featured with skin and mucosa fragility, with blistering at the dermal and epidermal levels or in the basement membrane zone. This complex pathology is a rare disease and its prevalence in the population is reported to range from 1:20 000 in Scotland to 1:100 000 in Italy and 1:130 000 in the U.S.A [1]. Unfortunately, there is no cure for EB; however the current therapeutic approaches are aimed at controlling infections, anaemia, as well as the nutritional status, and at monitoring of renal damage and for skin cancer prevention.

Based on the level at which the junction is compromised, namely above, within or below the basement membrane, EB has been divided into 3 wide categories: (a) the simplex form or epidermolytic blistering and tissue separation within the basal keratinocytes; (b) the junctional form, with lucidolytic blistering and tissue separation within the lamina lucida of the dermal-epidermal basement membrane; and (c) the dystrophic form with dermolytic blistering and tissue cleavage below the lamina densa within the upper part of the papillary dermis.

More recently a forth category has been introduced, the Kindler syndrome, which is a mixed form of the disease characterized by a

combination of features of inherited blistering skin disorders (eg, dystrophic epidermolysis bullosa) and congenital poikiloderma (e.g., Rothmund-Thompson syndrome) [2].

The dystrophic form of EB (DEB), either recessive or dominant, is characterized by abnormalities in the anchoring fibrils and attachment structures at the dermal-epidermal junction. DEB results in several different phenotypes ranging from less to more severe clinical manifestations. A big effort has been made in the way of generating a unique severity score able to uniform clinical data. In light of this, Moss and colleagues in 2009 have developed an useful tool, the Birmingham EB severity score (BEBS), allowing to assign an index to all EB clinical manifestations in a simple, valid, comprehensive and reliable way [3].

***Corresponding author:** Dr. Giuseppina Annicchiarico, Regional coordination for rare diseases - Ares Puglia, Via Caduti di tutte le Guerre 15, 70125 Bari, Italy, Tel: 0039080 9188139; Fax: 0039080; E-mail: coordinamento.malattierare@regione.puglia.it

Received July 31, 2013; **Accepted** September 21, 2013; **Published** September 29, 2013

Citation: Annicchiarico G, Morgese MG, Fiore T, Mauro S, Garofalo L, et al. (2013) Hla Typing in Epidermolysis Bullosa Patients: Relevancy to Gluten Sensitivity. J Genet Syndr Gene Ther 4: 182. doi:10.4172/2157-7412.1000182

Copyright: © 2013 Annicchiarico G, et al. This is an open-access article distributed under the terms of the Creative Commons Attribution License, which permits unrestricted use, distribution, and reproduction in any medium, provided the original author and source are credited.

All forms of DEB result from mutations in the gene encoding type VII collagen, COL7A1, the major component of anchoring fibrils at the dermal-epidermal junction [4]. DEB is characterized by many phenotypes and lately, various genotype-phenotype correlations have been hypothesized in order to explain such differences, and several mutations in COL7A1 have been reported.

However, a wide variety of non-cutaneous manifestations are present in different variants of EB, such as corneal erosions, Enamel hypoplasia, scarring alopecia, pseudo-syndactylia, and late onset muscular dystrophy. The lesions, that interest also mucosal sites, result in erosions and scars in the epithelium of tracheo-bronchial, oesophageal, and genitourinary tract leading to stenosis and functional sequelae [5]. Among possible consequences of the disease, scientific literature has been populated with case reports indicating the risk of renal complications in DEB patients [6]. In particular, IgA nephropathy (IgAN) has been reported in the above cited articles, indicating that deposition of clustered IgA may represent a serious complication in these patients, indeed renal failure is an important cause of death in this population of patients, in particular such complication represents a cumulative risk of 12.3% at age of 35, and is the second cause of death in these patients after skin cancer [7]. On the other hand, recent updates on IgAN have underlined a higher incidence of IgAN in Celiac patients leading to hypothesize that an enhanced sensitivity to gluten may be related to the development of such pathology. Furthermore, a gluten free diet has been shown to ameliorate the prognosis of IgAN patients [8]. Gluten peptides can be presented in HLA-DQ2 and HLA-DQ8 molecules on antigen presenting cells. Gluten-specific CD4+ T cells in the lamina propria respond to these peptides, and this likely enhances cytotoxicity of intraepithelial lymphocytes against the intestinal epithelium. The estimated risk effect of HLA-DQ2 and HLA-DQ8 on CD development is calculated to be ~35% [9]. We have recently published a report showing that in two DEB patients, the introduction of a gluten free diet, along with small dose of cortisone, was able to ameliorate both organ damage, renal function in particular, and skin manifestation of the pathology [10]. In line with these evidences, in the present study we decided to evaluate the presence of HLA haplotype suggestive of celiac disease or gluten sensitivity pathology in EB patients. We hypothesized that in these patients undiagnosed gluten sensitivity might lead to organ damage, in particular renal damage, thus we measured HLA typing, in order to hypothesize that a gluten free diet might result useful in this class of patients.

Methods

Patients

A total of 36 EB patients, 14 male, 22 female, were included in the present study. Patients were based on EB diagnosis were classified in EBS (6 patients, 4 male and 2 female), EBS Dowling-Meara (6 patients, 2 male and 4 female), and EBDR (24 patients, 8 male and 16 female). The diagnosis of EB was achieved by clinical assessment, accompanied by immunofluorescence mapping, transmission electron microscopy and genetic analyses. This study was approved by the Institutional

Ethics Committee and informed consent was obtained from all subjects/parents enrolled in the study.

Study design

Due to the rarity of EB pathology, we followed a cross section study, including all the patients afferent to the Dermatological Ward, University of Bari "A. Moro".

Severity score

Clinical manifestations of the disease were described and scored according to BEBS as reported by Moss et al. [3]. Briefly, the score was composed of multiple point assignment based on the severity of the clinical feature. In particular, the score consisted of sum of single pondered score attributed for: nail involvement (0-5), area of skin involvement (0-50), mucosal involvement-mouth, eyes, larynx, oesophagus (0-5), scarring of hands (0-5), skin cancer (0-5), chronic wound presence (more than 6 months, 0-5), alopecia due to EB (0-5), nutritional compromise (0-5). Taking into account that higher score are generally typical of older patients, in order to allow consistent comparisons, subjects were further sub-classified on age basis (0-5; 6-17; 17 and older).

HLA typing

Samples of peripheral blood were taken from each individual and genomic DNA was extracted using standard methods. DQA1*05, DQA1*0201, DQA1*0301, DQB1*02 and DQB1*03 genotyping was performed by polymerase chain reaction (PCR) amplification, using sequence-specific primers (Expect ram). Primers designed on a conserved region of DRB gene were used as controls. The specific PCR products were analyzed on 2% agarose gels and visualized under a UV transilluminator after the ethidium bromide staining.

Statistical analyses

The χ^2 test was used to compare the frequencies of HLA between study groups and controls in 2x2 Tables 1-4.

Results and Discussion

In the present study we have evaluated 36 patients diagnosed of Epidermolysis bullosa. The patients were further classified according to EB specific diagnosis in simplex, simplex Dowling-Meara and dystrophic. All enrolled patients were given a score according to BEBS. This severity score allows classifying clinical manifestation of the pathology only related to skin involvement, with the exception referred to the nutritional compromise score that can be considered a useful index of general wellness. Patients with simplex form of EB received 0 points while all subjects with Dowling-Meara diagnosis had total points of 2. In this latter case the score of 2 was associated to chronic wounds present mostly at sole level, while all the other scores were absent and therefore corresponded to 0 points. On the other hand, the dystrophic sub-group was composed of 24 patients with age ranging from 1 to 55 years. The points attributed were from 11 to 90. It is worth to note

Progressive pt number	Sex	Age	Nails	% Area damaged	mouth	eyes	Larynx	Oesophagus	Scarring of hands	Skin cancer	Chronic wound (>50%)	Scarring alopecia	Nutritional compromise	Total
1	M	1	2	30	3	2	0	2	1	x	x	x	0	40
2	F	2	3	40	5	5	0	5	1	x	x	x	5	64
3	F	3	4	35	3	3	0	3	3	x	x	x	5	56
4	F	6	5	30	3	3	0	2	4	0	2	0	4	53

Table 1: EBDR score, according to BEBS score, for patients with age ranging from 0 to 6 years.

Progressive pt number	Sex	Age	Nails	% area damaged	mouth	eyes	Larynx	Oesophagus	Scarring of hands	Skin cancer	Chronic wound (>50%)	Scarring alopecia	Nutritional compromise	Total
5	F	9	2	2	0	0	0	0	0	0	1	0	0	5
6	M	12	5	40	3	3	0	5	5	0	x	1	5	67
7	F	15	5	35	4	5	0	2	3	0	2	1	3	60
8	F	16	3	5	0	0	0	4	0	0	1	4	0	17
9	M	5	3	0	0	2	3	x	x	x	5	5	40	40

Table 2: EBDR score, according to BEBS score, for patients with age ranging from 7 to 17 years.

Progressive pt number	Sex	Age	Nails	% area damaged	Mouth	Eyes	Larynx	Oesophagus	Scarring of hands	Skin cancer	Chronic wound (>50%)	Scarring alopecia	Nutritional compromise	Total
10	F	19	5	40	4	3	0	2	3	0	2	1	3	63
11	M	19	5	40	4	4	0	3	5	0	3	2	4	65
12	M	22	5	40	4	4	0	3	5	0	3	2	4	70
13	F	25	5	20	3	3	0	3	2	0	2	3	5	46
14	F	25	5	40	5	5	0	5	5	0	4	4	5	78
15	F	27	5	35	5	5	0	4	5	0	4	3	3	69
16	F	28	5	40	5	5	5	0	5	5	0	4	4	78
17	F	28	5	35	5	5	0	4	5	0	4	3	3	69
18	F	32	5	50	5	5	0	5	5	0	5	5	5	90
19	M	33	5	40	5	5	0	4	5	3	5	4	3	79
20	M	33	5	20	0	0	0	2	1	0	2	3	0	33
21	M	42	5	20	4	0	0	1	2	3	2	0	1	38
22	F	44	5	20	0	0	0	4	1	3	4	0	2	39
23	F	49	1	5	2	0	0	3	0	0	0	0	0	11
24	F	55	3	20	2	0	0	4	0	0	2	0	5	36

Table 3: EBDR score, according to BEBS score, for patients with age older than 17 years.

that this severity score is not pondered according to the age of affected subject. In this regard we have sub-classified the enrolled subjects based on age range. Indeed, we found a total score from 40 to 64 in age range 0-5 years (total of 4 patients, Table 1); a total score from 5 to 67 in age range 6-17 years (Table 2), and total score from 11 to 90 in age range over 18 (Table 3). This age-based distinction allows making few considerations. First of all, as shown in Table 1, for scarring of hands, skin cancer, chronic wound (>50%), and scarring alopecia parameters it was reported a X symbol instead of a 0 value. Such decision was made in order to emphasize that these kinds of parameters are very unusual to be found at that age stage. Consequently, a score of 64 at the age of 2 years (progressive patient 1, Table 1) is surely sign of a more severe phenotype, and such result can be comparable with the score of 90 assigned to patient 18 in (Table 3). In this regard this score could be improved by dividing the scoring in two sections. The first should include all clinical manifestation of the pathology that involves the skin. The second part of the score should be focused to monitor general wellness. In particular, the following parameters might be included: pain perception according to PRS or VAS scale for paediatric age or NRS scale in adults, asthenia, free and autonomous ambulation, pruritus, general inflammation state. To improve this scoring method we feel to suggest a correction factor that might weight the severity of the score according to the age of the patient.

Unfortunately, EB patients, with particular reference to dystrophic case, may be at risk for developing one or more extracutaneous complications [11]. Such complication may involve either epithelial associated tissues or other organs. Within epithelial associated tissue involvement the external eye, ear, nose, upper airway, and gastrointestinal and genitourinary tracts are mostly reported. This broad range of severity for complications suggests that the optimal management must result in a multidisciplinary approach, avoiding to consider EB as a disease

affecting only skin and mucosal areas [11,12]. In addition, with respect to other organ involvement, some epidermolysis bullosa subtypes are at risk for severe injury of the bone marrow, musculoskeletal system, heart, kidney, and teeth, and for the development of squamous cell carcinoma, basal cell carcinoma, or malignant melanoma. [12]. In particular, several renal complications have been reported for DEB in the recessive form, such as amyloidosis, due to high amyloid a deposition, post-infection glomerulonephritis, upper and lower urinary tract obstruction and IgAN [13,14]. With respect to IgAN, several case reports have populated the literature describing case of recessive DEB patients diagnosed of this renal pathology. [5,6,15]. IgAN is a glomerular disease characterized by prevalent mesangial IgA deposits, frequently is associated with macroscopic haematuria at level of mucosal infections [16,17]. Emerging hypothesis revealed that in IgAN suffering subjects mucosal immune system is dealing with continuous antigenic challenge which leads to the production of nephritogenic IgA, and common microbial or food antigens may play the role of eliciting agents [18]. In this light, previous publications have shown a beneficial effect of a gluten-free diet in these patients by reducing the levels of anti-gliadin IgA [8,19]. Moreover, glomerular mesangial deposits of IgA occur frequently in untreated celiac disease and it seems that they are in some way associated with circulating IgA-class antibodies and immune complexes [20].

On the other hand, gastro-intestinal problems in EB are very common with subtype specificity for some of these complications. It has been proposed that the occurrence of diarrhoea, Protein Losing Enteropathy and colitis in the context of EB, although not highlighted previously, may arise secondarily to antigenic exposure in the gut lumen as a result of mucosal fragility [21]. Indeed, in a recent animal model of EB acquisita, it has been shown that COL7, which is defective in DEB, is expressed in different portions of the gut and that anti-COL7 antibodies

		Controls	EB	Controls%	EB%
DQ2.5	DQA1*0105/ DQB1*0201	27	3	7.92%	8.1%
DQ2.2	DQA1*0201/ DQB1*0202	20	8	5.87%	21.62%*
DQ2T	DQA1*0201/ DQB1*0202				
DQA1*0505/ DQB1*0301	39	2	11.44%	5.41%	
DQ8	DQA1*0301/ DQB1*0302	9	2	2.64%	5.41%
DQ2-8	DQB1*02/ DQB10302	3	0	0.88%	0
DQ7	DQA1*0505/ DQB1*0301	138	14	40.47%	37.83%
Neg	X/X	105	7	30.79%	18.91%
total		341	36		

Table 4: HLA-DQ of EB versus control patients, χ^2 test revealed that only DQ2.2 was present in EB patients with higher prevalence.

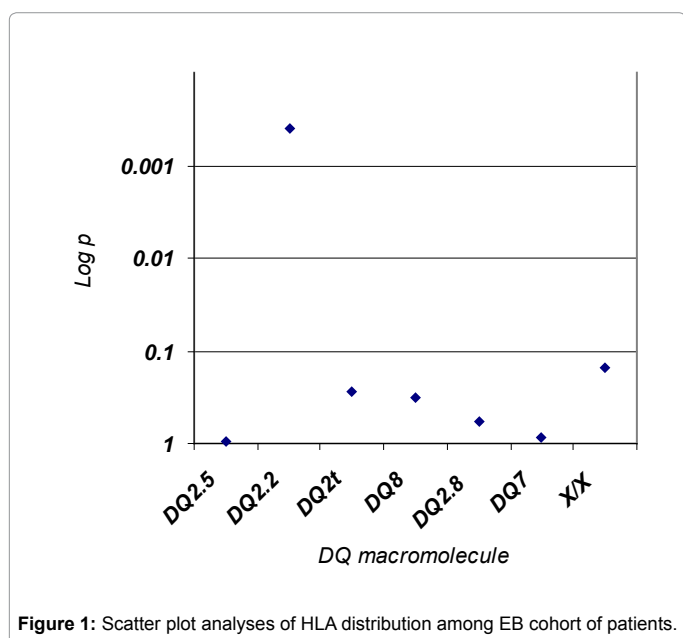


Figure 1: Scatter plot analyses of HLA distribution among EB cohort of patients.

induce distinct gastrointestinal tissue damage [22]. This evidence is particularly interesting since indicates that a state of chronic intestinal inflammation might be present in DEB patients as a result of chronic mechanical or antigenic insult. In line with this hypothesis Inflammatory Bowel Disease was described in individual cases of either EBS [11], and DEB [23] and, diarrhoea has been shown as the predominant GI symptom in a short series of children with severe RDEB and JEB [24]. Given that in dystrophic patients, chronic gut inflammation is likely to be present, considering that defective collagen VII is present across the intestine [25] we hypothesize that in these patients insults originated from food antigens might precipitate extra epithelial manifestation of the disease. In this perspective, we decided to evaluate if in our DEB patients was present a HLA expression typical of celiac disease or non celiac gluten sensitivity. In our population we found that 21.62% of EB patients had DQ2.2 allotype while in control group it was only 5.87%. This difference was statistically significant ($p < 0.0005$, χ^2 test, Table 4 and Figure 1). DQ2.5, the allotype mostly associated with celiac disease, was present in 8.1% of EB and in 7.92% of controls, thus no difference was found. DQ8 was present in 5.41% of EB and in 2.64%

of controls, although the trend was toward the increase this difference was not significant from a statistical point of view. In regard to the more common DQ7 and negative alleles, no difference was evidenced. HLA-DQ2.5 is the strongly associate with the risk of developing CD, however it has been reported that in a small class of patients gluten-dependent enteropathy periodically presents in adults with low-risk alleles [26]. It can be argued that our results might be affected by a bias related to the small numerosity of the sample. However, it should be underlined that this pathology is absolutely very rare (1:100.000 in Italy) therefore, 36 patients is quite a large number. Furthermore, it should be underlined that in this category of patients chronic inflammation state is expected to be present at the level of the intestinal mucosal. In turn high release of pro-inflammatory cytokines is likely to occur, such as interferon γ or interleukin 2 and 15. Interestingly, IFN- γ has been reported to boost either the expression of HLA DQ2/8 or of transglutaminase 2 amplifying the responsiveness to gluten peptides [27,28]. Indeed, increased serum levels of interleukin-6, immunoglobulin and acute phase protein have been reported in patients with the severe clinical form of EB [29].

Gluten free diet has been shown to be beneficial in either gut related and not related pathology such as IgAN and asthmatic non celiac patients with intestinal symptoms [8,30]. It is still controversial how immunogenic gluten peptides from the intestinal lumen reach the lamina propria where they can prime gluten-specific T cells. It has been suggested that gluten peptides can be transported during transient increased intestinal permeability during enteroviral infections [31] or by IgA-mediated retrotranscytosis via the interaction with the transferrin receptor CD71 [32]. It is worth to note that celiac disease and EB share some clinical manifestations such as anaemia, malnutrition, difficulty to thrive, delayed puberty, chronic fatigue, and dental enamel defects [12,33]. Therefore, it should be of interest testing if even EB patients may obtain some beneficial results from gluten-free diet. In this regard, we have recently reported the usefulness of gluten free diet in two dystrophic EB patients that were encountering renal dysfunction, such as proteinuria [10]. In particular, in these patients the absence of gluten from diet not only reversed the proteinuria, but also improved significantly their general health status (reduction in fatigue, pruritus, achievement of free deambulation).

In conclusion, in the present study we have reported that in EB patients a possible association with gluten sensitivity, non celiac disease, can be hypothesized. Moreover, we believe that in these subjects the use of gluten free diet might result beneficial in order to reduce the organ damage risk. Indeed, the exposure to gluten in these patients may contribute to worsen organ damage, in particular renal function, leading to hospitalization up to loss of capacity to freely deambulate. To screen for gluten sensitivity and an early administration of gluten free diet in the population of EB patients with high score for pathology (BEBS) and in particular to those with higher nutritional compromise, should be considered as a novel therapeutic approach and might help to change the course of the disease as well as EB extracutaneous complications.

Authors' Contribution

G.A. and M.G.M. wrote the manuscript; M. T., S. M. and M.M. performed the molecular analyses, L.B., D. B. and G. A. were responsible of sample collection and patients' care. G. A., T. F., M. M. and L. B. were responsible of study design.

Acknowledgement

We would like to thank the contribution given by Dr. Maria Palmisano for her uninterrupted work and care given to the patients involved in the study. Moreover,

we would like to thank Dr Michele Lattarulo for his support to the research presented at any moment.

References

1. Tabolli S, Sampogna F, Di Pietro C, Paradisi A, Uras C, et al. (2009) Quality of life in patients with epidermolysis bullosa. *Br J Dermatol* 161: 869-877.
2. Fine JD, Eady RA, Bauer EA, Bauer JW, Bruckner-Tuderman L, et al. (2008) The classification of inherited epidermolysis bullosa (EB): Report of the Third International Consensus Meeting on Diagnosis and Classification of EB. *J Am Acad Dermatol* 58: 931-950.
3. Moss C, Wong A, Davies P (2009) The Birmingham Epidermolysis Bullosa Severity score: development and validation. *Br J Dermatol* 160: 1057-1065.
4. Christiano AM, Ryyänen M, Uitto J (1994) Dominant dystrophic epidermolysis bullosa: identification of a Gly→Ser substitution in the triple-helical domain of type VII collagen. *Proc Natl Acad Sci U S A* 91: 3549-3553.
5. Tammaro F, Calabrese R, Aceto G, Lospalluti L, Garofalo L, et al. (2008) End-stage renal disease secondary to IgA nephropathy in recessive dystrophic epidermolysis bullosa: a case report. *Pediatr Nephrol* 23: 141-144.
6. Cuesta-Estellés G, Escobedo-Rumoroso JM, Garcés-López L, Pérez-García A (1998) Epidermolysis bullosa and chronic renal failure. *Nephrol Dial Transplant* 13: 2133-2134.
7. Fine JD, Johnson LB, Weiner M, Stein A, Cash S, et al. (2004) Inherited epidermolysis bullosa and the risk of death from renal disease: experience of the National Epidermolysis Bullosa Registry. *Am J Kidney Dis* 44: 651-660.
8. Coppo R, Roccatello D, Amore A, Quattrocchio G, Molino A, et al. (1990) Effects of a gluten-free diet in primary IgA nephropathy. *Clin Nephrol* 33: 72-86.
9. Hunt KA, Zhenakova A, Turner G, Heap GA, Franke L, et al. (2008) Newly identified genetic risk variants for celiac disease related to the immune response. *Nat Genet* 40: 395-402.
10. Annicchiarico G, Morgese MG, Brunetti L, Tampoia M, Garofalo L, et al. (2012) Improvement of renal function in epidermolysis bullosa patients after gluten free diet: two cases. *Eur Rev Med Pharmacol Sci* 16 Suppl 4: 138-141.
11. Fine JD, Mellerio JE (2009) Extracutaneous manifestations and complications of inherited epidermolysis bullosa: part I. Epithelial associated tissues. *J Am Acad Dermatol* 61: 367-384.
12. Fine JD, Mellerio JE (2009) Extracutaneous manifestations and complications of inherited epidermolysis bullosa: part II. Other organs. *J Am Acad Dermatol* 61: 387-402.
13. Hogg RJ, Silva FG, Wyatt RJ, Reisch JS, Argyle JC, et al. (1994) Prognostic indicators in children with IgA nephropathy—report of the Southwest Pediatric Nephrology Study Group. *Pediatr Nephrol* 8: 15-20.
14. Horn HM, Tidman MJ (2002) The clinical spectrum of dystrophic epidermolysis bullosa. *Br J Dermatol* 146: 267-274.
15. Kawasaki Y, Isume M, Takano K, Suyama K, Imaizumi T, et al. (2008) IgA nephropathy in a patient with dominant dystrophic epidermolysis bullosa. *Tohoku J Exp Med* 214: 297-301.
16. Oortwijn BD, Roos A, Royle L, van Gijlswijk-Janssen DJ, Faber-Krol MC, et al. (2006) Differential glycosylation of polymeric and monomeric IgA: a possible role in glomerular inflammation in IgA nephropathy. *J Am Soc Nephrol* 17: 3529-3539.
17. Oortwijn BD, van der Boog PJ, Roos A, van der Geest RN, de Fijter JW, et al. (2006) A pathogenic role for secretory IgA in IgA nephropathy. *Kidney Int* 69: 1131-1138.
18. Coppo R, Camilla R, Amore A, Peruzzi L, Daprà V, et al. (2010) Toll-like receptor 4 expression is increased in circulating mononuclear cells of patients with immunoglobulin A nephropathy. *Clin Exp Immunol* 159: 73-81.
19. Roccatello D, Coppo R, Cavalli G, Piccoli G, Amprimo MC, et al. (1990) Wheat protein antigens and effector cells of aspecific immunity. *J Clin Lab Immunol* 31: 167-173.
20. Pasternack A, Collin P, Mustonen J, Reunala T, Rantala I, et al. (1990) Glomerular IgA deposits in patients with celiac disease. *Clin Nephrol* 34: 56-60.
21. Freeman EB, Köglmeier J, Martínez AE, Mellerio JE, Haynes L, et al. (2008) Gastrointestinal complications of epidermolysis bullosa in children. *Br J Dermatol* 158: 1308-1314.
22. Ishii N, Recke A, Mihai S, Hirose M, Hashimoto T, et al. (2011) Autoantibody-induced intestinal inflammation and weight loss in experimental epidermolysis bullosa acquisita. *J Pathol* 224: 234-244.
23. Sehgal VN, Rege VL, Ghosh SK, Kamat SM (1977) Dystrophic epidermolysis bullosa. Interesting gastro-intestinal manifestations. *Br J Dermatol* 96: 389-392.
24. Shah MD, Berman WF (1993) Endoscopic balloon dilation of esophageal strictures in children. *Gastrointest Endosc* 39: 153-156.
25. Chen M, O'Toole EA, Sanghavi J, Mahmud N, Kelleher D, et al. (2002) The epidermolysis bullosa acquisita antigen (type VII collagen) is present in human colon and patients with crohn's disease have autoantibodies to type VII collagen. *J Invest Dermatol* 118: 1059-1064.
26. Harmon GS, Lebeck LK, Weidner N (2011) Gluten-dependent enteropathy and atypical human leukocyte antigen alleles. *Hum Pathol* 42: 1112-1116.
27. Bayardo M, Punzi F, Bondar C, Chopita N, Chirido F (2012) Transglutaminase 2 expression is enhanced synergistically by interferon- γ and tumour necrosis factor- α in human small intestine. *Clin Exp Immunol* 168: 95-104.
28. Tjøn JM, van Bergen J, Koning F (2010) Celiac disease: how complicated can it get? *Immunogenetics* 62: 641-651.
29. Kawakami Y, Oyama N, Ohtsuka M, Nakamura K, Kaneko F (2005) Increased serum levels of interleukin-6, immunoglobulin and acute phase protein in patients with the severe clinical form of inherited epidermolysis bullosa. *J Dermatol* 32: 503-505.
30. Massari S, Liso M, De Santis L, Mazzei F, Carlone A, et al. (2011) Occurrence of nonceliac gluten sensitivity in patients with allergic disease. *Int Arch Allergy Immunol* 155: 389-394.
31. Stene LC, Honeyman MC, Hoffenberg EJ, Haas JE, Sokol RJ, et al. (2006) Rotavirus infection frequency and risk of celiac disease autoimmunity in early childhood: a longitudinal study. *Am J Gastroenterol* 101: 2333-2340.
32. Matysiak-Budnik T, Moura IC, Arcos-Fajardo M, Lebreton C, Ménard S, et al. (2008) Secretory IgA mediates retrotranscytosis of intact gliadin peptides via the transferrin receptor in celiac disease. *J Exp Med* 205: 143-154.
33. Avşar A, Kalayci AG (2008) The presence and distribution of dental enamel defects and caries in children with celiac disease. *Turk J Pediatr* 50: 45-50.