

## Hidden Penis in Children: Evaluation of Outcomes and Review of the Literature

Ruankha Bilommi\*

Department of Pediatric Urology, Mitra Keluarga Group General Hospital, YARSI Medical Faculty, Jakarta, Indonesia

### Abstract

**Background:** There are many categories in hidden penises usually differentiation among the terms includes: concealed (before circumcision), trapped (cicatricial or scarred) after circumcision, and buried (associated with adolescence and obesity).

**Methods:** From December 2014 to August 2015, we evaluated 10 patients (6 months–10 years old) with buried penises, concealed penises, trapped penises and webbed penises that were surgically. All the patients were scheduled for regular follow-up at 1, 4, and 12 weeks postoperatively.

**Results:** 10 patients underwent surgical repair, all buried and concealed patients had penile degloving and penile fixation. All patients reported much improved urinary function, and all patients stated that they were pleased or very happy with their outcome

**Conclusions:** Children with hidden penis are can be psychologically affected and have a risk for social trauma. The wide variety of approaches to correcting this problem reflects the different perceptions of etiology. Treatment for hidden penis should aim to restore an aesthetic and functional penis.

**Keyword:** Children; Hidden; Lymphedema; Penis

### Introduction

When a penis appears absent or too small, we call the condition Hidden penis. There are many categories in hidden penises; buried penis, webbed penis, concealed penis, and trapped penis. Several classification systems have been proposed, although none has been universally adopted in the literature. Usually, differentiation among the terms includes: concealed (before circumcision), trapped (cicatricial or scarred) after circumcision, and buried (associated with adolescence and obesity) [1].

The buried penis is widely regarded as a condition which is difficult to manage both in children and in adults. Buried penis was first described by Keyes in 1919 as follows: “absence of the penis exists when the penis, lacking its proper sheath of skin, lies buried beneath the integument of the abdomen, thigh or scrotum” Buried penis in adults may have a congenital component in some cases but is largely regarded as being an acquired condition as a consequence of obesity [1-3].

Various etiologic factors have been proposed to explain congenital buried penis. Recent literature favors digenetic dartos tissue with abnormal attachments proximally and to the dorsal cavernosum. A prominent prepubic fat pad is also a common primary factor, in addition to digenetic dartos fascia. Secondary buried penis may be the result of an overzealous circumcision with subsequent cicatricial scar (trapped penis), a large hernia, or a hydrocele. Another possible cause of buried penis in the adult is genital lymphedema. This may be idiopathic, iatrogenic (from prior surgery), or acquired due to filariasis [1-4].

In children, presentation is often driven by parental concerns over urinary symptoms and penile size. The complex interaction of significant physical and psychological symptoms of patients with a buried penis means that treatment must be tailored to the individual. Indeed, within the literature, no single operative technique has been described to meet all patients' needs. Algorithms have been advocated for treatment of adults with buried penis to take into account the different surgical approaches to this problem. Consideration for surgical reconstruction necessitates earnest discussion with the family

regarding the potential functional, cosmetic and psychosocial outcome of surgical reconstruction [5,6].

### Patients and Methods

From December 2014 to August 2015, we evaluated 10 patients (6 months-10 years old) with buried penises, concealed penises, trapped penises and webbed penises that were went to surgery. There are ten cases; 2 had buried penises, 3 had concealed penises, 4 had trapped penises and 1 patient had webbed penis. All cases were evaluated clinically with emphasis on true length of the penis, the presence or absence of the prepuce, the length of penile skin in circumcised patients and presence of any inflammations or cicatrizing scars following circumcision Establishing the diagnosis of concealed penis and its category, as buried, webbed or trapped, can be done with clinical examination only.

Great care was directed to preoperative penile hygiene especially in buried and trapped penis. Surgical technique general anesthesia with endotracheal intubation was given to all cases and local anesthesia was avoided as dissection of the surgical planes could then become more difficult. Buried Penis: Cases with buried penis were repaired using technique (t.A) of a traction suture was applied to the glans, a circumferential coronal incision was done, and by using the Buck's fascia as the plane of dissection, the penis was degloved to the penopubic junction. Sharp dissection of the digenetic dartos fibers, to free the penis from its deep tethering, was carried out. Fixation was then performed by placement of absorbable sutures (polyglycolic acid

\*Corresponding author: Ruankha Bilommi, Department of Pediatric Urology, Mitra Keluarga Group General Hospital, YARSI Medical Faculty, Jakarta, Indonesia, Tel: 62 81312228237; E-mail: [ruankhabi@gmail.com](mailto:ruankhabi@gmail.com)

Received October 29, 2015; Accepted December 15, 2015; Published December 20, 2015

Citation: Bilommi R (2015) Hidden Penis in Children: Evaluation of Outcomes and Review of the Literature. Med Surg Urol 4: 156. doi:10.4172/2168-9857.1000156

Copyright: © 2015 Bilommi R. This is an open-access article distributed under the terms of the Creative Commons Attribution License, which permits unrestricted use, distribution, and reproduction in any medium, provided the original author and source are credited.

4/0 to 2/0 according to the patient's age) between the dermis of the skin shaft at the base of the penis and buck's fascia, lateral to the posterior neurovascular bundle and lateral to the urethra, thus restoring the penopubic and penoscrotal angles respectively. The circumferential incision was then closed with absorbable sutures.

Webbed penises were corrected with technique (t.B) by transverse incision was made at the penoscrotal junction and, with dissection to the deep fascia; the scrotum is allowed to assume a more caudal position. This was followed by circumferential dissection along the buck's fascia freeing the penis from its deep tethering and excising any abnormal bands. Fixation of dartos fascia and dermis of penile skin to Buck's fascia was done using polyglycolic acid sutures. The scrotal incision was closed longitudinally to create the penoscrotal angle.

Trapped penises were treated (t.C) by excising cicatricial scar that trapped the penis and complete penile degloving, the resultant bare area and remaining penile skin was assessed. Infected or scarred tissue is removed as necessary and sent for laboratory analysis. The penopubic and penoscrotal angles are reconstructed using 3-0 PDS sutures between the tunica albuginea and dartos fascia and dermis at the penile base, placed in the 12, 7, and 4 o'clock positions (Figures 1-4).

## Result

A total of 10 patients were treated for hidden penis between December 2014 to August 2015. All patients were between 6months of ages to 10 years old boy. Presentation by consisted of a range of symptoms which were in all cases multifactorial and included difficulty passing urine, aesthetic concerns, and recurrent infections of the penis itself, including recurrent phimosis. All patients underwent surgical repair 2; patients with buried penis underwent complete penile degloving, excision of the digenetic dartos fascia, fixing the penile skin at the penopubic and penoscrotal angles to avoid recurrence, while in the 1 patients with webbed penis, only reconstruction of the penoscrotal angle was performed after excision of the penoscrotal web as normal penopubic angle was already present. All trapped penises have had undergone previous penile surgery (circumcision). All patients had penile degloving and penile fixation. All patients reported much improved urinary function, particularly with regard to standing micturition which all felt able to accomplish following the surgery. Sensation over the grafts significantly varied. None reported urinary tract infections. No buried penis recurred, and all patients stated that they were pleased or very happy with their outcome.

## Discussion

Clarity in the approach to hidden penis management is hindered by the confusing use of interchangeable terminology to describe the condition. A penis may be referred to as buried, webbed, concealed, inconspicuous, or trapped. The first attempt at surgical correction

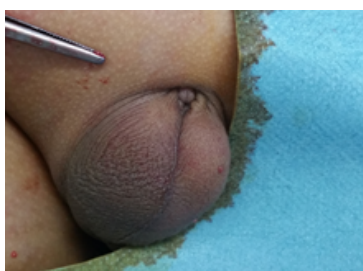
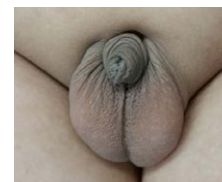
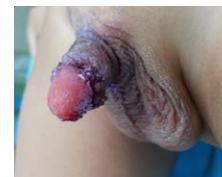Figure 1: One of our Buried penis patient 10 year boy.



A1

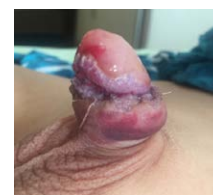

A2

Figure 2A: 8 years old boy with Concealed penises that has been done surgical repair of t.A technique that has been explained before. (A1: pre op picture, A2: post op picture).

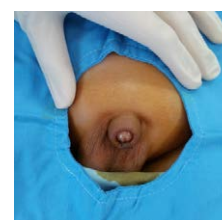


B1

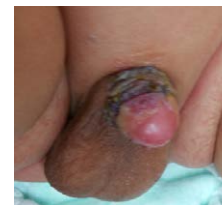

B2

Figure 2B: 10 years of concealed penis that has been done surgical repair. (B1: pre op picture, B2: post operation day 5 picture).



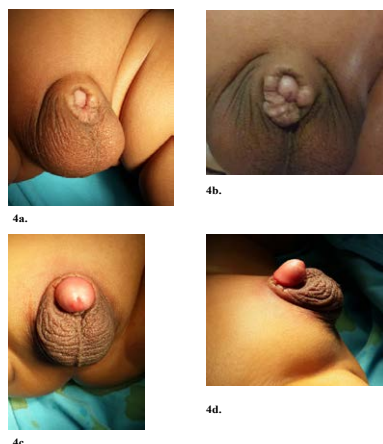
1.



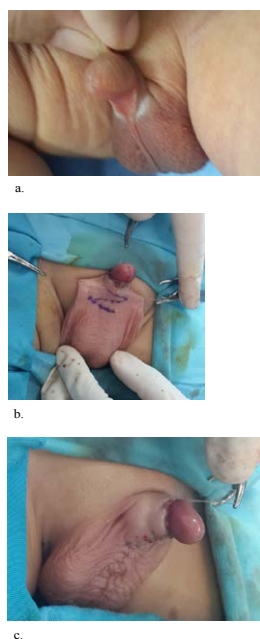
2.

Figure 3: 1. Pre operation of 2 years old boy with trapped penis. 2. Post operation picture of uthe patient that had been surgically corrected with our technique (t.C).

of this problem was done by Schloss in 1959 and in 1968; successful correction was performed by Glanz in an adult. Since that time, numerous techniques have been developed [1,3,5,6,7].



**Figure 4:** 4a & 4b: Trapped penises of under one year old boys due to siccatic post circumscisions. 4c & 4c: post operation pictures.



**Figure 5:** Webbed penis of 4 years old boy. a: pre op picture, b: intra operative picture of our surgical incision technique, C: post-operative picture.

The classification by Maizels is widely referred to, particularly in reference to pediatric buried penis, and identifies buried penis as one of three subgroups of concealed penis, along with webbed and trapped. Buried penis is defined as a penis of normal size which is concealed within the pubic tissue due to a lack of fixation of the skin at the base of the penis. By contrast, a trapped penis is secondary to scarring following penile surgery, such as circumcision, and webbed penis is a result of the disappearance of the penoscrotal angle due to abnormally distal extension of scrotal skin over the ventral surface of the penis. Elder clarifies his definition of buried penis (interchangeably used with concealed penis) in children as being caused by an inelasticity of the dartos fascia in infancy and by abundant fat on the abdominal wall in older children. Oh further distinguish between the concealed and buried penis, stating that the etiology of concealed penis lies in a deficiency of penile skin or inelasticity of the dartos fascia [1,4,5,7,8].

Buried penis by contrast is secondary to poor fixation of penile skin at the penile base or excessive suprapubic fat. The overarching consensus is thus that childhood buried penis is in the main a congenital condition which can also be seen with post-circumcision scarring. Ehrlich and Alter suggest that the term buried penis for adults refers to a penile shaft which is buried beneath the surface of the prepubic skin and to a penis which is partially or totally obscured secondary to either obesity or injudicious circumcision. Adult buried penis is viewed largely as an acquired condition with a different pathophysiology from that of children, although some authors consider that some milder forms of dysgenic dartos fascial bands may not be present until adulthood, which somewhat blurs the distinction [2,4,7,9].

Dissection of the dartos and Buck's fascia with division of chordee is commonly performed, though the approach of the dissection does vary, with some clinicians preferring to make incisions at the penopubic or penoscrotal junction with dissection distally to free the shaft, some working proximally and others using a combination. In our experience, release from distal to proximal enables clear and safe visualization of the dissection plane and of the neurovascular structures, adhesions, and chordee. Some clinicians induce artificial erections with saline to determine the adequacy of release of adhesions. Borsellino maintains that the key to correction is release of the abnormal dartos attachments and fixation of the penile skin to Buck's fascia [2,4,5,8,10].

## Conclusion

Children with hidden penis are could be psychologically effected and have a risk for social trauma. The wide variety of approaches to correcting this problem reflects the different perceptions of etiology. Treatment for hidden penis should aim to restore an aesthetic and functional penis.

## References

1. Keyes EL (1919) Phimosis-Paraphimosis-Tumors of the Penis, Appleton & Co, New York, USA.
2. Asimakopoulos AD , Iorio B, Vespasiani G, Cervelli V, Spera E (2012) Autologous split-thickness skin graft for penile coverage in the treatment of buried (trapped) penis after radical circumcision. *BJU International* 110: 602-606.
3. Jung EH, Son JH, Jang SH, Lee JW (2011) Simple anchoring of the penopubic skin to the prepubic deep fascia in surgical correction of buried penis. *Korean Journal of Urology* 52: 787-791.
4. Djordjevic M, Martins F, Bizic M, Kojovic V, Majstorovic M, et al. (2010) One stage repair of iatrogenic trapped penis, *American Urology Association Annual Meeting*, San Francisco, California, USA, 1104: 125.
5. Kojovic V, Bizic M, Majstorovic M, Korac G, Stanojevic D, et al. (2008) Genital skin flaps for reconstruction of iatrogenic trapped penis. *Eur Urol Meetings* 3: 80.
6. Perovic S, Djordjevic M, Kekic Z, Djakovic N (2002) Penile surgery and reconstruction. *Curr Opin Urol* 12: 191-194.
7. Rivas S, Romero R, Parente A, Fanjul M, Angulo JM (2011) Simplification of the surgical treatment of a hidden penis. *Actas Urologicas Espanolas* 35: 310-314.
8. Masuda H, Azuma H, Segawa N, Iwamoto Y, Inamoto T, et al. (2004) Surgical correction of buried penis after traffic accident—a case report. *BMC Urology* 4: 1-3.
9. Black PC, Friedrich JB, Engrav LH, Wessells H (2004) Meshed unexpanded split-thickness skin grafting for reconstruction of penile skin loss. *Journal of Urology* 172: 976-979.
10. Gillett MD, Rathbun SR, Husmann DA, Clay RP, Kramer SA (2005) Split-thickness skin graft for the management of concealed penis. *Journal of Urology* 173: 579-582.