

Giant Prolactinoma and Primary Amenorrhea with an Infantile Uterus: A Case Report

Munazzah Rafique^{1*}, Solaiman Alobaid² and Dania Aljaroudi²

¹Department of Obstetrics and Gynecology, Women's Specialized Hospital, King Fahad Medical City, Riyadh, Kingdom of Saudi Arabia;

²Reproductive Endocrinology and Infertility Medicine Department, Women's Specialized Hospital, King Fahad Medical City, Riyadh, Kingdom of Saudi Arabia

ABSTRACT

Giant prolactinomas are rare pituitary gland tumours found in paediatric and adolescent patients. The pituitary gland controls metabolism, growth, sexual maturation, reproduction, blood pressure, and other vital physical functions. A 15-year-old girl presented with headache, blurred vision, primary amenorrhea and significantly high prolactin (PRL) levels with baseline level of 344,727 µg/L. Turner syndrome, Müllerian agenesis, hypothalamic amenorrhea, and primary ovarian insufficiency were excluded by laboratory and radiologic tests. Initial brain computed tomography revealed a giant pituitary adenoma and ultrasonography revealed an infantile uterus. Pituitary gland resection confirmed prolactinoma. With medical treatment, menstruation was restored uterine and ovarian parameters were improved with increased endometrial thickness and ovaries showing follicles. However, symptom recurrence and resistance to treatment warranted surgical and radiological interventions. This case report calls attention to the role of prolactin in uterine development and the need to include prolactin level in key investigations in patients with primary amenorrhea.

Keywords: Giant prolactinoma; Adenoma; Amenorrhea; Pituitary gland

INTRODUCTION

The pituitary gland is a crucial structure in the hypothalamic-pituitary-gonadal axis and plays an integral role in sexual maturation during puberty [1]. Prolactin levels can increase because of medications, pituitary adenoma, hypothyroidism, or mass effects, which can compromise normal hypothalamic inhibition [2]. Prolactin tumours are the most common secreting pituitary adenoma and are frequently microadenomas (≤ 10 mm diameter) or, less commonly, giant prolactinomas (≥ 4 cm diameter) [3]. The pituitary gland grows during adolescence and its volume correlates to circulating plasma total testosterone and oestradiol levels [1]. Prolactinoma frequently occur in females with female-to-male ratio is approximately 10:1. Prolactinomas have a prevalence of 100/million population in the paediatric and adolescent age group and constitute less than 2% of all intracranial tumors [4]. Mostly patients present with infertility and menstruation dysfunction. However, if remain unrecognized and untreated they can result in significant morbidity [5]. Sex differences at presentation and tumour behaviour have been recognized, with >70% occurring

in females, while males often present with larger, more aggressive tumours [6]. Paediatric (age, <16 years) and adolescent (age, ≤ 20 years) prolactinomas are very rare and typically diagnosed in the late stage [7].

The functional diversity of prolactin is responsible for differences in the initial clinical presentation of hyperprolactinaemia [8]. Prolactinomas are functioning adenomas and can induce visual disturbances and body morphological changes [9]. Hyperprolactinaemic children present with various initial clinical presentations including growth and puberty disorders, obesity, galactorrhea, and oligomenorrhea or amenorrhea [8-10]. These symptoms are consequence of prolactin-induced suppression of gonadotrophin-releasing hormone and its negative feedback at the pituitary and gonadal levels [11]. Primary amenorrhea is defined as no menarche by age 13 when there is no pubertal development, no menarche 5 years after initial breast development, or no menses in patients aged ≥ 15 years [12]. It can be caused by chromosomal abnormalities (e.g., Turner syndrome), anatomic anomalies (e.g., Müllerian agenesis), hypothalamic amenorrhea,

Correspondence to: Munazzah Rafique, Department of Obstetrics and Gynecology, Women's Specialized Hospital, King Fahad Medical City, Riyadh 11525, Kingdom of Saudi Arabia, Telephone: (+966) 11 288 9999 Ext:21100; E-mail: munazzahr@yahoo.com

Received: February 21, 2019; **Accepted:** April 17, 2019; **Published:** April 24, 2019

Citation: Rafique M, Alobaid S, Aljaroudi D (2019) Giant Prolactinoma and Primary Amenorrhea with an Infantile Uterus: A Case Report. *Reprod Syst Sex Disord* 8: 1. doi: 10.4172/2161-038X.1000226

Copyright: © 2019 Rafique M, et al. This is an open-access article distributed under the terms of the Creative Commons Attribution License, which permits unrestricted use, distribution, and reproduction in any medium, provided the original author and source are credited.

hyperprolactinaemia, hypopituitarism (due to craniopharyngioma, other sellar tumors, pituitary stalk damage) or primary ovarian insufficiency [12].

Elevated prolactin levels inhibit the secretion and effect of gonadotrophins and necessitate the need for magnetic resonance imaging (MRI) of the pituitary [1]. Treatment of prolactinomas may involve dopamine agonist administration or surgical resection [2]. Our objective in this paper is to report a rare case of prolactinoma.

CASE REPORT

A 15-year-old girl with no relevant medical, family, or psychosocial history was admitted to the Neurology Department of King Fahad Medical City (Riyadh, Saudi Arabia) for headache. Twelve months before presentation, the patient developed frontal and temporal headache with blurred vision that was unresponsive to paracetamol. Some months later, she developed loss of concentration accompanied by fatigue. She was referred to the Reproductive Endocrinology and Infertility Medicine Department for primary amenorrhea. She had no symptoms of hypothyroidism, adrenal insufficiency, galactorrhea, or polycystic ovary syndrome.

Upon admission, the patient underwent a clinical evaluation and medical tests. On physical examination, she was alert and hemodynamically stable with no postural drop in blood pressure or features of cortisol or growth hormone excess. She was 151 cm tall, weigh 67 kg, with a body mass index (BMI) of 29.5, normal pubertal development, and no galactorrhea. Her secondary sexual characteristics and breast development were normal. However, optic discs were pale, with bilateral hemianopia. She also had mild left upper limb weakness. Laboratory test findings were as follows: elevated prolactin level, 344,727 $\mu\text{g/L}$; serum cortisol level, 186 nmol/L; serum adrenocorticotrophic hormone level, 3.0 pg/mL; thyroid-stimulating hormone level, 1.3 mIU/L; free thyroxine level, 14.1 pmol/L; luteinizing hormone level, 5.5 IU/L, follicle-stimulating hormone level, 5.6 IU/L; testosterone level, 4.9 nmol/L; and growth hormone level, 1.7 $\mu\text{g/L}$ (indicating partial anterior hypopituitarism). Abdominal ultrasonography revealed an infantile uterus (2.31 cm^2), endometrial thickness of 0.2 mm, and ovaries without follicles (Figure 1).

MRI revealed a giant invasive prolactinoma (7.2 \times 6.1 \times 7.9 cm^3) that had extended to an extra-axial tumour at the anterior skull base and the middle cranial fossa and was invading the sella turcica and right cavernous sinus. Destruction of the related base bony structures

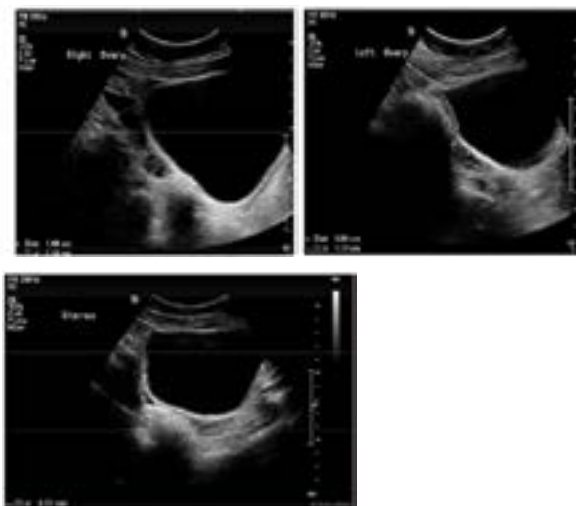


Figure 1: Abdominal ultrasonography before treatment showing an infantile uterus and ovaries.

was observed with the tumour drawn-out laterally through the right foramen ovale. Brain computed tomography showed a large extra-axial tumour with a sellar component associated with a midline shift and mild brain swelling (Figure 2).

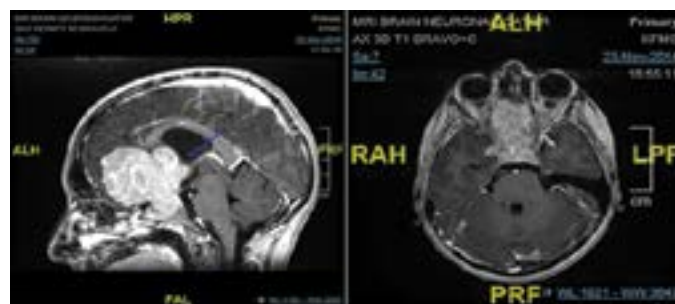


Figure 2: Pre-treatment view: An axial T2-weighted image with gadolinium revealed a large diffusely enhanced lesion invading the middle cranial fossa and cavernous sinus. Middle: sagittal T2-weighted MRI with gadolinium.

On admission in 2014, she was treated with oral cabergoline (0.5 mg four times per week), hydrocortisone, and thyroxine in standard doses. She started irregular and scanty menstruation with medical treatment. However, her headache and vision problem persisted even after 6 months of treatment; she therefore underwent surgical resection for the pituitary macroadenoma *via* a suboccipital approach. The histopathology was consistent with that of a pituitary adenoma. Subsequently, her prolactin level decreased from 344,727 to 14,114 $\mu\text{g/L}$ within 6 days, and she was discharged and advised to take cabergoline 0.25 μg twice weekly. Post-treatment MRI showed improvement (Figure 3).

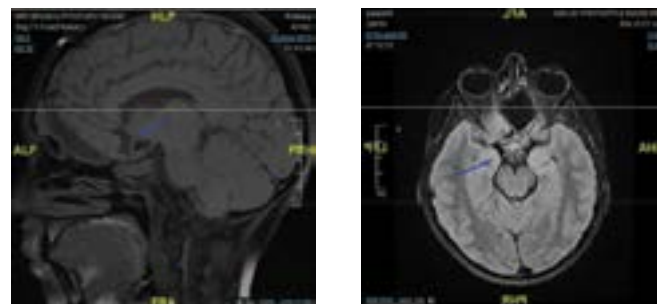


Figure 3: Postsurgical T1-weighted gadolinium images before and early post-treatment.

Moreover, post-treatment ultrasonography revealed that her uterus measured 4.55 \times 1.33 cm^2 with an endometrial thickness of 2 mm and both ovaries contained small follicles. These findings showed improved uterine and ovarian dimensions (Figure 4).

However, within 2 years of surgery despite of being on maximum dose of cabergoline (2 mg/week), she experienced bilateral hemianopia, headache, secondary amenorrhea, and increased prolactin level of 38,531 $\mu\text{g/L}$. MRI showed an interval increase in lesion size, particularly in that of the sellar components, with the most significant increase seen in the craniocaudal dimension. The lesion invaded the bilateral cavernous sinuses and sphenoidal sinus with suprasellar extension and encasement of the cavernous segment of both the internal and anterior cerebral arteries, which maintained patent flow. A multidisciplinary team diagnosed an atypical giant pituitary macroadenoma with a post-resection residual tumour that showed significant progression in size since the previous MRI. Therefore, external beam radiation therapy was

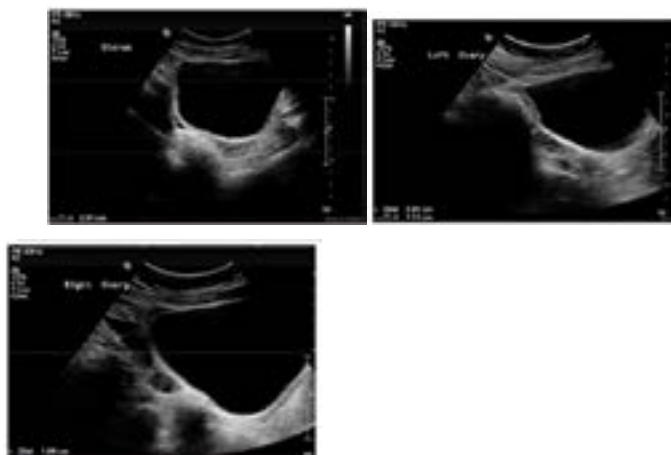


Figure 4: Uterus and ovaries after treatment. Ultrasonography revealed that her uterus measured 4.55×1.33 cm² with an endometrial thickness of 2 mm and both ovaries contained small follicles.

started, and her visual symptoms improved; a follow-up brain MRI showed a minimal decrease in lesion size (Figure 5).

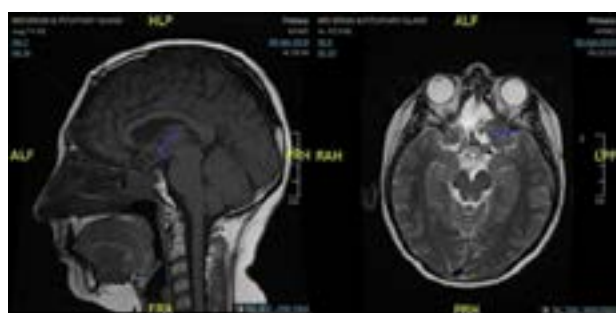


Figure 5: Post-radiotherapy coronal T2-weighted post gadolinium comparative images showing a significant reduction in tumour volume.

DISCUSSION

Giant prolactinomas are rare and usually present in men, while microprolactinomas predominate in women. Contrarily, our patient was an adolescent female. Some studies have suggested that pituitary tumours are more aggressive and invasive in paediatric patients than in adults [13], comparable to our patient.

An assessment of secondary sexual characteristics by Tanner stages, are widely used to evaluate growth and developmental age during adolescence that helps in evaluating physical growth and detecting certain diseases and disorders associated with adolescence. These stages of growth correlate highly with other pubertal events [14]. Paediatric prolactinomas are frequently associated with delayed puberty as high prolactin levels affect hypothalamic-gonadotropic activity [13,14]. The most common symptoms of prolactinoma are gynaecomastia and hypogonadism in males and primary amenorrhea and galactorrhea in females [13,15]. In women after puberty, symptom duration mainly reflects disease duration. However, the influence of sex on tumour behaviour and response to treatment remains unclear [16]. The main complaint of our patient was impaired vision and headache, and she was later referred for primary amenorrhea.

Kanter et al. reported increased invasiveness of adenomas when symptom onset was during pubertal years compared with cases wherein symptoms first appeared after puberty [17]. This was consistent with

our case wherein symptoms appeared in the prepubertal stage and were reported almost 1 year after onset. Invasive macro adenomas generally invade adjacent structures, but do not metastasize [3]. Although the cystic components of prolactinomas are well defined, an invasive giant prolactinoma is extremely rare. Patients with prolactinoma and higher prolactin values ($>4,000$ mU/L) have a reduction in serum levels of both FSH and LH, consistent with direct pituitary gonadotrope dysfunction [18].

Dopamine agonist administration is the first-choice treatment for paediatric and adult prolactinomas. Resistance to medication, intolerable side effects, and non-adherence to medication are major problems in medical treatment [16]. Although the response of giant macroprolactinomas to medical therapy is unpredictable [7], our patient showed a moderately reduced prolactin level within 6 weeks of treatment with a high-dose dopamine agonist [19]. Hyperprolactinemia is more common in females, and cabergoline is highly effective and practical to use in adolescents due to its biweekly dosing. Surgery should be considered in childhood [20]. However, symptom persistence warranted surgical resection. The role of surgery in the treatment of these lesions is limited. Complete surgical resection is difficult and biochemical cure is rare [18]. The degree of cavernous sinus invasion is often significant, precluding complete resection. However, we chose surgical treatment for the giant tumour with a large suprasellar extension and mass effect in our patient. The observed clinical improvement later on decreased due to the increased residual size of the treatment-resistant adenoma. Prolactin level is a good indicator of tumour recurrence in the follow-up period [21].

Subsequently, serum prolactin levels in our patient increased. Radiotherapy was started due to symptom recurrence and cavernous sinus invasion by the tumour after multidisciplinary team discussion. However, the follow-up MRI showed no change in the adenoma size. Generally, giant macroprolactinomas are sensitive to dopamine agonist therapy; as in our patient who showed improved visual symptoms, menstruation, uterine parameters, and prolactin levels. Nonetheless, surgery may often be necessary for giant prolactinomas, which are usually refractory to treatment.

CONCLUSION

In our patient, menstruation was restored and uterine parameters improved with high-dose cabergoline treatment. However, her other symptoms persisted. Secondary amenorrhea can occur in the setting of a giant invasive macroprolactinoma; therefore, prolactin levels should be a routine part of the hormonal evaluation of primary amenorrhea.

AUTHOR CONTRIBUTIONS

RM compiled endocrine data and authored the manuscript. JD and AS co-authored the manuscript and performed the literature search. All authors were directly or indirectly involved in the care of the patient. JD is the physician principally responsible for the care of the patient and co-authored the manuscript.

ACKNOWLEDGEMENTS

Reproductive Endocrine and Infertility and Medicine Department.

CONFLICTS OF INTEREST

No conflicts of interest.

FUNDING

This study received no funding.

ETHICAL APPROVAL

The IRB approved the study protocol.

CONSENT

Informed consent was obtained from the patient for publication of this case report and any accompanying images.

GUARANTOR

Dr. Dania Al-Jaroudi.

REFERENCES

1. Wong AP, Pipitone J, Park MTM, Dickie EW, Leonard G, Perron M, et al. Estimating volumes of the pituitary gland from T1-weighted magnetic-resonance images: effects of age, puberty, testosterone, and estradiol. *Neuroimage*. 2014;94:216-221.
2. Pickett CA. Diagnosis and management of pituitary tumors: recent advances. *Prim Care*. 2003;30:765-789.
3. Martins AN, Hayes GJ, Kempe LG. Invasive pituitary adenomas. *J Neurosurg*. 1965;22:268-276.
4. Ciccarelli A, Daly AF, Beckers A. The epidemiology of prolactinomas. *Pituitary*. 2005;8:3-6.
5. Levin G, Rottenstreich A. Prolactin, prolactin disorders, and dopamine agonists during pregnancy. *Hormones*. 2018;19:1-3.
6. Furtado SV, Saikiran NA, Ghosal N, Hegde AS. Giant, solid, invasive prolactinoma in a prepubescent boy with gynecomastia. *Pediatr Neurol*. 2010;42:72-74.
7. Chentli F, Akkache L, Azzoug S. Pediatric and adolescent prolactinomas: Comparison between males and females. *Annales d'Endocrinologie*. 2013;74:422.
8. Saranac L, Zivanovic S, Radovanovic Z, Kostic G, Markovic I, Miljkovic P. Hyperprolactinemia: different clinical expression in childhood. *Horm Res Paediatr*. 2010;73:187-192.
9. Molitch ME. Anterior pituitary. In Goldman's Cecil Medicine. 24th ed. Philadelphia: Saunders. 2011.
10. Practice Committee of American Society for Reproductive Medicine. Current evaluation of amenorrhea. *Fertil Steril*. 2008;90:19-25.
11. Speroff L, Fritz MA. Clinical gynecologic endocrinology and infertility. 7th ed. Philadelphia: Lippincott Williams & Wilkins. 2005;pp:401-464.
12. Reindollar RH, Novak M, Tho SP, McDonough PG. Adult-onset amenorrhea: a study of 262 patients. *Am J Obstet Gynecol*. 1986;155:531-543.
13. Colao A, Loche S, Cappa M, Di Sarno A, Landi ML, Sarnacchiaro F, et al. Prolactinomas in children and adolescents. Clinical presentation and long-term follow-up. *J Clin Endocrinol Metab*. 1998;83:2777-2780.
14. Spear BA. Adolescent growth and development. *J Acad Nutr Diet*. 2002;1:23.
15. Howlett TA, Wass JA, Grossman A, Plowman PN, Charlesworth M, Touzel R, et al. Prolactinomas presenting as primary amenorrhoea and delayed or arrested puberty: Response to medical therapy. *Clin Endocrinol*. 1989;30:131-140.
16. Delgrange E, Trouillas J, Maiter D, Donckier J, Tourniaire J. Sex-related difference in the growth of prolactinomas: A clinical and proliferation marker study. *J Clin Endocrinol Metab*. 1997;82:2102-2107.
17. Kanter SL, Mickle JP, Hunter SB, Rhoton AL. Pituitary adenomas in pediatric patients: are they more invasive? *Pediatr Neurosci*. 1985;12:202-204.
18. Abbara A, Clarke SA, Nesbitt A, Ali S, Comninou AN, Hatfield E, et al. Interpretation of serum gonadotropin levels in hyperprolactinemia. *Neuroendocrinology*. 2018;1.
19. Verhelst J, Abs R, Maiter D, Vandeweghe M, Velkeniers B, Mockel J, et al. Cabergoline in the treatment of hyperprolactinemia: a study in 455 patients. *J Clin Endocrinol Metab*. 1999;84:2518-2522.
20. Eren E, Törel AE, Işgüven ŞP, Çelebi EB, Berberoğlu M, Şıklar Z, et al. Clinical and Laboratory Characteristics of Hyperprolactinemia in Children and Adolescents: National Survey. *J Clin Res Pediatr Endocrinol*. 2018.
21. Mankahla N, Peya B, Semple P, Ross IL. A giant invasive prolactinoma complicated by a cerebrospinal fluid leak: A short case report. *Interdiscip Neurosurg*. 2017;9:45-47.