

Female Urethral Diverticulum: Diagnosis, Treatment and Outcome

Marcelo Di Gregorio^{1*}, Francis Lorge¹, Michaël Dupont¹, Cassandra da Cunha Farias Paulino de Moraes², Livia Carneiro Nascimento², Agostinho de Sousa Machado Júnior² and Helena Juliana Nagy²

¹Department of Urology, CHU UCL Namur, Belgium

²Department of Gynecology, Hospital das Clínicas of Pernambuco, Brazil

Abstract

Objectives: To share our experience regarding the handling of symptomatic or asymptomatic female urethral diverticula. Clinical presentation, diagnostic methods, and therapeutic strategies are reviewed.

Methods: This was a retrospective analysis involving eight female patients with urethral diverticula who were followed up in our urology department between 2007 and 2015. Preoperative assessment included clinical examination and cystoscopy, voiding cystourethrogram, or magnetic resonance imaging. Postoperative follow-up visits were scheduled at 3, 6, and 12 months.

Results: Diagnosis was based on anamnesis and physical examination, and then confirmed by complimentary exams such as voiding cystourethrogram and magnetic resonance imaging. All patients experienced symptomatic relief and improved esthetic outcome after surgery. Magnetic resonance imaging was instrumental in confirming the diagnosis and in planning the surgical approach. Surgical excision of the diverticulum and reconstruction resulted in good aesthetic and functional outcomes. There were no major postoperative complications.

Conclusions: Previously unrecognized female urethral diverticula can now be more easily detected using magnetic resonance imaging. In our small series, surgical excision and reconstruction was associated with good clinical outcome.

Keywords: Female urethral diverticulum; Lower urinary tract symptoms; MRI; Urethral surgery; Voiding cystourethrogram

Abbreviations: UD: Urethral Diverticulum; LUTS: Lower Urinary Tract Symptoms; VCUG: Voiding Cystourethrography; DBU: Double-Balloon Urethrography; MRI: Magnetic Resonance imaging; SUI: Stress Urgency Incontinence

Background

The female urethra, a vascular and spongy structure located between the bladder and urethral orifice, may be the site of numerous abnormal structures. One of these is the urethral diverticulum (UD). Its reported incidence varies from 1 to 6% [1]. While it may occur at all ages, UD are typically seen in women aged 30 to 50 years [2]. Although their exact physiopathology is still unclear, UD are assumed to originate from pathologic processes involving the periurethral glands, as reported by Raz et al. [3]. Repeated infections may cause a herniation into the periurethral fascia. This expansion often occurs posteriorly in relation to the urethra, resulting in the classic anterior vaginal wall mass, which can be palpated on physical examination. Exceptionally, the lesions may also expand laterally or even anteriorly.

Most patients complain of non-specific problems or suffer from lower urinary tract symptoms (LUTS). The most common of these have been termed the three “Ds”, referring to dysuria, post-void dribbling, and dyspareunia. The condition is frequently overlooked or misdiagnosed. Various diagnostic tests have been reported, such as cystoscopy, voiding cystourethrography (VCUG), double-balloon retrograde urethrography (DBU), transvaginal, transperineal and endourethral ultrasound, magnetic resonance imaging (MRI), as well as virtual computed tomography urethroscopy.

Standard treatment consists of operative excision and reconstruction. The surgical interventions currently in use include transurethral marsupialization, open marsupialization, excision with reconstruction, and endoscopic unroofing [4-6].

This paper seeks to share with the readers our experience regarding the handling of the symptomatic and asymptomatic female UD. Various diagnostic methods are discussed, in particular issues pertaining to MRI and VCUG. Lastly, the different therapeutic approaches to cure this condition are presented.

Methods

Ethics: Agreement of Ethics Committee with Internal number CE Mont-Godinne 104/2015 and Belgian number: B039201525838

This was a retrospective analysis concerning all UD cases seen in our urology department between January 2007 and September 2015. Internal reviewed board acceptance was asked and obtained, and informed consent of the patients was waived, because it was a retrospective study based on clinical data. Data was collected from clinical charts and electronic records. Clinical evaluation comprised patient history (onset, duration, and nature of symptoms), physical examination, urine analysis and culture, urethroscopy, as well as radiological imaging studies including VCUG and pelvic MRI. MRI performed at our institution was done on a 1.5-T or 3-T system (Symphony TIM or Verio, Siemens Medical Systems, Erlangen, Germany) using a torso and spinal phased array coils. Axial, coronal,

*Corresponding author: Marcelo Di Gregorio, CHU UCL Namur, Site Godinne, 1 Av Gaston Thérèse, B-5530 Yvoir, Belgium, Tel: +32 81 42 34 78; Fax: +32 81 42 34 79; E-mail: marcelo.digregorio@uclouvain.be

Received March 12, 2016; Accepted April 21, 2016; Published April 29, 2016

Citation: Di Gregorio M, Lorge F, Dupont M, de Moraes CCFP, Nascimento LC, et al. (2016) Female Urethral Diverticulum: Diagnosis, Treatment and Outcome. Gynecol Obstet (Sunnyvale) 6: 374. doi:10.4172/2161-0932.1000374

Copyright: © 2016 Di Gregorio M, et al. This is an open-access article distributed under the terms of the Creative Commons Attribution License, which permits unrestricted use, distribution, and reproduction in any medium, provided the original author and source are credited.

and sagittal T2 turbo spin-echo sequences with 4mm slice thickness and axial T2 turbo spin-echo sequence with spectral fat saturation were performed through the female perineum. Patients with pre-existing stress, urge, or mixed urinary incontinence also underwent pad-testing and urodynamic evaluation.

All surgical operative reports were thoroughly analyzed, and postoperative complications as well as follow-up visit findings were assessed. Two consultant surgeons performed all of the operative procedures. Follow-up visits were held at our medical consultation 3, 6, and 12 months post-intervention. Assessments comprised symptom relief, anatomical results, and postoperative continence status. Cure was defined as complete resolution of symptoms and optimal anatomical outcome.

Results

Patient population

Eight consecutive women with UD admitted to our urology

department were evaluated during the 8-year study period. UD was symptomatic in seven patients, and asymptomatic in the remaining one. Mean patient age was 44 years, ranging from 26 to 57. The most common presenting symptoms were dyspareunia, dysuria, urinary frequency/urgency, post-void dribbling, reported by four patients, recurrent urinary tract infections, and pain, each being reported by three patients (Table 1). Urethral pain was described as burning, sticking, pressure, aching, or spasms. Vaginal discharge was recorded in two cases. The full pathognomonic triad of dysuria, dyspareunia, and post-void dribbling was noted in only four patients.

The mean time interval between symptom onset and definite diagnosis was 2 years, ranging from 2 months to 3 years. Three patients had a history of incontinence with urodynamic evaluation. On average, two physicians (range 1 to 3), including general practitioners, gynecologists, and urologists, had been previously consulted. Their formulated diagnoses were vulvo-vestibulitis, urethral syndrome, and stress urinary incontinence.

Pelvic examination conducted in our urology department revealed

	1	2	3	4	5	6	7	8
Age (years)	26	57	46	46	26	54	54	31
BMI (kg/m ²)	18	21	19	25	19	33	25	26
Symptoms								
Dysuria	+	+	-	-	-	-	-	-
Post-void dribbling	-	+	+	+	-	-	+	-
Dyspareunia	-	-	-	+	+	+	+	+
Pollakuria	+	+	-	-	-	-	+	+
Lower urinary tract infections	+	+	+	-	-	+	-	+
Vaginal discharge	+	-	-	-	-	-	-	-
Vaginal mass	+	+	+	+	+	+	+	+
Urinary incontinence	-	+	-	+	-	-	+	+
Gravidity and parity status	G0P0	G1P1	G4P3A1	G1P0A1	G0P0	G1P1	G3P3	G1P1
Complementary exam								
Cystography	-	+	-	+	+	+	+	+
MRI	+	+	-	+	+	+	+	+
Ultrasound	+	-	-	-	-	+	+	-
Cystoscopy	-	+	-	+	+	+	+	-
Urodynamic test	-	+	-	+	-	+	+	-
Pad Test	-	+	-	+	-	-	+	-
Urethral diverticulum characteristics								
Location	Distal	Mid	Mid	Mid	Distal	Distal	Mid	Distal
Number	1	1	1	1	1	1	1	2
Size (mm)	26 × 35	12 × 18	NA	14 × 19	9 × 11	8 × 11	11 × 10	3 × 6 and 8 × 11
Anatomic configuration	Spherical	Horseshoe-shaped	Spherical	Spherical	Spherical	Spherical	Spherical	Spherical
Site of communication to the urethral lumen	Proximal	Mid	Mid	Mid	Distal	Distal	Mid	Distal
Date of surgery	July 2007	June 2009	October 2009	July 2010	December 2010	October 2013	February 2015	September 2015
Operative time	70'	133'	110'	60'	73'	65'	60'	70'
Intraoperative complications	None	None	None	None	None	None	None	None
Post-operative complications	None	None	None	None	None	None	None	None
Duration of hospitalization following surgery	5	5	5	3	3	2	2	2
Follow up status	Normal	Normal	Normal	Normal	Normal	Normal	Normal	Normal

Table 1: Symptoms in our patient series (n=8).

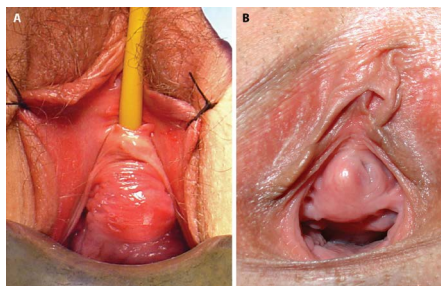


Figure 1: Physical examination: A) Ventral diverticulum B) Para-urethral diverticulum

a distinctly palpable periurethral mass in all eight cases. The suspicion for UD was based on patient anamnesis and physical examination (Figure 1) in seven symptomatic patients, and on clinical examination only in the remaining, asymptomatic patient. In two patients, there was a milky discharge following gentle compression of the periurethral mass (Figure 2A). Cystoscopy allowed for ostia visualization in the distal urethra in two cases. One of these cases is illustrated in Figure 2B.

In three patients, diagnosis was confirmed by means of VCUG conducted under fluoroscopic control in the standing position, and in most of the cases by MRI (Figures 3A-3C). All diverticula were shown to be simple imaginations. The mean diverticulum size was 1, 5 cm (range 0.6-3.5 cm).

Surgical approach

In all eight cases, the same surgical approach for diverticulectomy was applied using a vaginal flap technique. Patients were placed in the lithotomy position. Prior to surgery, a 16-Fr urethral catheter was inserted. An inverted “U” incision was then performed on the anterior vaginal wall, with its apex approximately 1 cm proximal to the urethral meatus. An anterior vagina wall flap was raised to the level of the bladder neck. The urethra was dissected, and flaps were developed laterally and posteriorly. The periurethral fascia was opened, and the diverticulum was then grasped and carefully dissected back up to its origin at the urethra level (Figures 4A and 4B). In selected cases, the UD had to be first opened so as to facilitate dissection from the surrounding tissues (Figure 4C). In more complex cases, it proved necessary to excise a small, inflamed portion of the urethral wall, in proximity of the ostia (Figure 4D).

The urethra was reconstructed over a 14-Fr Foley catheter and closed with a 4/0 absorbable suture, in a way that there were no tension on the urethral tissue. Then, a three-layer closure (urethral wall, periurethral fascia, and vagina wall) was performed in a watertight, tension-free fashion, with no overlapping sutures. The periurethral fascial flaps were re-approximated with an absorbable suture in a perpendicular orientation to the urethral closure line in order to avoid the risk of postoperative urethrovaginal fistula formation or UD recurrence. Lastly, the anterior vaginal wall flap was repositioned and reapproximated with absorbable suture, thus representing the third layer closure.

To prevent infection, perioperative antibiotics were continued for 7 days post-surgery. Control VCUV study was carried 7 days after the intervention, showing leakage in no patient. Urethral catheter was removed after the control VCUV. Anticholinergic were administrated until 24 hours prior to removing the urethral catheter.

Patient follow-up

At follow-up, symptomatic relief and esthetical resolution were

reported in all cases. No major complications were noted. There were no infections, no stone formation, and no malignant transformation noted. To date, neither urethrovaginal fistula, neither urethral stricture nor UD recurrence has been observed.

Discussion

Female UD is a rare clinical condition, which is often overlooked or misdiagnosed because of lack of clinical awareness. As stated by Fortunato et al., a full history and thorough physical examination are the first steps in the patient screening process [7]. In over 80% of

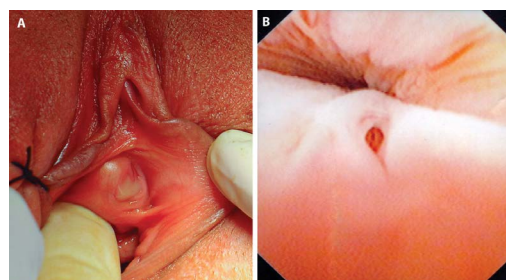


Figure 2: A) Manual compressions of the diverticulum and meatal discharge was milky appearance B) The ostia were same-times identified through cystoscopy.

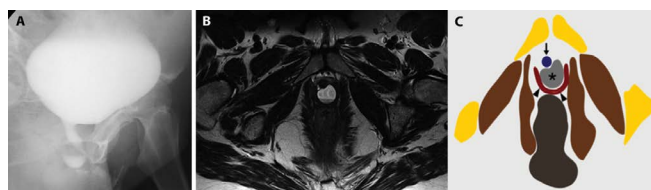


Figure 3: A) Voiding cystourethrography, oblique view B) MRI axial T2 weighted image at the level of pubis level C) Corresponding schematic view with urethral diverticulum (asterisk), vagina (black arrowheads) and urethra (black arrow).

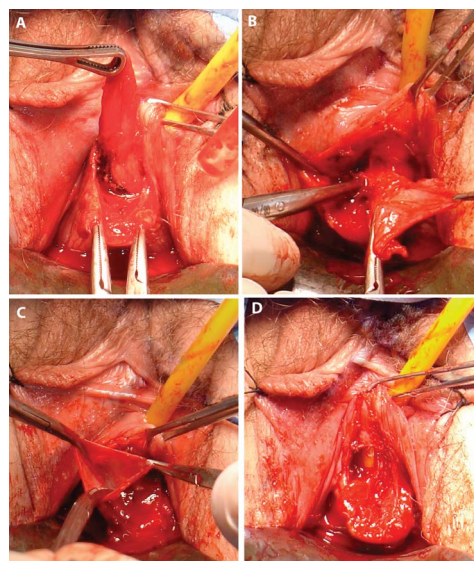


Figure 4: A and B) Diverticulum tracted to approach de neck dissection C) Open the urethral diverticulum for facilitating dissection D) Adherent or inflamed portion of the urethra wall has to be removed near the ostia area.

patients periurethral masses are present [8]. It should be noted that 2 to 11% of UD's may be totally asymptomatic. This was the case in one of our patient: the UD was incidentally found on routine pelvic examination, without any associated symptoms. In all our eight patients, a periurethral mass was palpable. It should, however, be noted that all periurethral masses do not necessarily constitute UD. Differential diagnosis must eliminate other disorders, such as ectopic ureterocele, urethral carcinoma, vaginal wall inclusion cyst, Gartner's duct cyst, Skene's gland abscess, periurthral fibroma, urethral varices, as well as other conditions [9]. Another differential diagnosis that must be ruled out is the pseudo-diverticulum that develops following diverticulectomy or other urethral surgery types [10].

Cystourethroscopy is a valuable tool to eliminate other causes of the patient's lower urinary tract symptoms. During cystoscopy, when performed, we attempted to gently strip the urethra distally in an effort to express purulent material or urine from UD cavity. In two cases, cysto-urethroscopy allowed us to visualize the UD ostium, which is not always possible by means of MRI. Of note is that a timely diagnosis is of paramount importance: a delay in UD diagnosis >12 months was reported to be associated with a high risk of postoperative complications [11].

Radiological studies are very useful in the screening process, yet no single study can be considered the gold standard for UD diagnosis. In the past, the DBU was commonly employed to assess location, extent, size, number, and configuration of UD, with sensitivity rates as high as 65% [12]. Currently, VCUG, ultrasound, and MRI are the preferred imaging tools [13]. VCUG may provide excellent UD imaging. Being widely available and familiar to most radiologists, this imaging technique involves, however, ionizing radiation. Ultrasonography is performed using the transvaginal, transperineal, or transurethral approach. While being less invasive, relatively inexpensive, and devoid of ionizing radiation exposure, this imaging tool is, however, operator-dependent. In addition, ultrasound does not provide precise surgical anatomy. Contrary to ultrasound, MRI exhibits a high degree of tissue contrast, is completely independent of voiding, and involves no ionizing radiation [14]. Various coils can be used: endovaginal, endorectal, endoluminal and external. On T2-weighted images, UD appear as areas of increased signal intensity [15]. On account of its multiplanar capabilities and excellent soft-tissue contrast, MRI provides superior information for the surgical approach by accurately delineating the extent and anatomical landmarks relative to the perineum, and specifically to the urethra [16].

In our case series, most of patients underwent both VCUG and MRI for diagnostic confirmation, with MRI showing higher sensitivity compared to VCUG. In our view, MRI is increasingly becoming the method of choice for UD diagnosis and preoperative planning. The technique's disadvantages include high cost, moderate accessibility, and the need for experienced radiologists. The contraindications to MRI are metallic foreign body fragments, claustrophobia, and pace-makers. Less invasive than conventional urethroscopy, virtual computed tomography urethroscopy is another imaging tool, with good results for visualizing the UD orifice [17].

Only two of our patients underwent urodynamic evaluation, as they complained of stress urgency incontinence (SUI). We share LiAnn et al. opinion regarding the risk of concomitant SUI management, and especially that of urethral erosion if the sling is positioned over the urethral reconstruction site [18]. Another element that needs to be highlighted is the difficulty of urodynamic evaluation in differentiating between paradoxical incontinence and true SUI. Of our two patients with SUI prior to surgery, incontinence complaints persisted following surgery in one case, postoperative kinesitherapy proved efficient. In the

other patient, transobturator tape suspension was effective in curing incontinence.

Surgical UD management in patients with minimal complaints is still a matter of debate, but we would like to draw the reader's attention to several reports concerning malignant transformation of UD into carcinomas [19]. While surgical treatment is clearly indicated in symptomatic cases, surgery can also be challenging, particularly in cases involving large or multiple diverticula [9]. The most common complications in relation with UD surgery include infection, recurrent diverticulum formation, urethrovaginal fistula, urethral stricture, and stress urinary incontinence [20]. The reported risk factors for surgical failure are purulent content, large UD size, proximal location, lateral or horseshoe shape, delayed diagnosis, or previous urethral surgery. The L/N/S/C3 classification, proposed by Leach et al., allowed us to easily assess all preoperative factors [21]. This system is based on defining key characteristics of the diverticulum: location (L), number (N), size (S), anatomic configuration (C), site of communication to the urethral lumen, and continence status. After a thorough evaluation including the use of the Leach classification system, decision was made to proceed to surgical management in all five cases.

Concerning surgical management, complete excision of both diverticular sac and neck, along with meticulous dissection, and layered repair, while preserving the periurethral fascia, are the crucial steps to achieve satisfactory results and definitive cure by means of a single operation. Since the original report by Hey in 1805 [22], various surgical procedures for UD management have been reported. Three major approaches may be distinguished:

- 1) Transurethral (endoscopic) approach:
 - A- incision of the ostia communications;
 - B- unroofing of the diverticula sac;
 - C- fulguration;
 - D- incision and obliteration with oxidized cellulose or polytetrafluoroethylene.
- 2) Marsupialization of the diverticulum sac into the vagina.
- 3) Excision of the diverticulum and reconstruction.

The third approach, probably the most commonly used at present, was the technique of our choice in our eight patients. The procedure's principles can be summarized in three steps: 1) complete excision of the diverticulum; 2) use of a vaginal skin flap; 3) multilayer closures without overlapping suture lines. The main challenge consists in an adequate mobilization of the periurethral fascia, since the tissues often adhere to the underlying diverticular wall. Another crucial feature is to develop the proximal and distal periurethral facial flaps and to reflect them off the underlying diverticulum, exposing the diverticulum circumferentially down to its urethral communication before removing it completely. The urethral defect is closed longitudinally over a catheter with a continuous locking suture in two layers. By avoiding excessive tension, this technique reduces the risk of abnormal scarring and stricture formation. The periurethral fascia is then closed using a running suture, with apposition of the vaginal mucosa. Of paramount importance is that suture lines be not superimposed in order to reduce or prevent postoperative fistula formation. In complex cases, the use of a Martius fat pad graft may be instrumental in preventing fistula formation and improving repair. Care should be taken in conducting a postoperative VCUG in order to rule out any extravasation from the urethral closure site.

Our study has some limitations, which are mainly related to its small sample size (n=8) and the retrospective nature of the analysis. Despite these shortcomings, the results observed in our third-level hospital (non-tertiary referral centre) are encouraging, as the clinical post-surgery outcome was satisfactory in all eight patients, and there were no significant postoperative complications.

Conclusions

Female UDs are probably much more common than previously thought. The suspicion should always be high in the clinician's mind when confronted with women presenting lower urinary tract symptoms, such as urinary frequency, postvoid dribbling, urinary tract infections, or periurethral mass. A thorough history, coupled with a full clinical examination, VCUG, MRI, endoscopic examination, should be conducted in order to confirm the diagnosis. In our series, MRI proved particularly useful for diagnosis and defining anatomical landmarks and guiding the surgical procedure. The three-layer vaginal flap technique, carried out in all eight patients, was associated with an excellent success rate, without major complications.

Competing Interests

The authors declare that they have no competing interests (Financial or Non- financial).

Authors' Contributions

MDG conceived, coordinated and designed of study. MD participated in its design and helped to draft the manuscript. FL helped in coordination and draft corrections. All authors read and approved the final manuscript.

Acknowledgements

The authors acknowledge Christian Deneffe for pictures edition and Pr. Luc Michel for last corrections.

References

1. Patel AK, Chapple CR (2006) Female urethral diverticula. *Curr Opin Urol* 16: 248-254.
2. Wright JL, Miller JL (2005) Female Urethral Diverticulum: Diverse Presentation and Surgical Results. *J Pelvic Med Surg* 11: 191-194.
3. Rovner SE (2008) Urethral diverticula. In : *Female Urology*. Elsevier Health Sciences.
4. Davis BL, Robinson DG (1970) Diverticula of the female urethra: assay of 120 cases. *J Urol* 104: 850-853.
5. Spence HM, Duckett JW Jr (1970) Diverticulum of the female urethra: clinical aspects and presentation of a simple operative technique for cure. *J Urol* 104: 432-437.
6. Spencer WF, Stroom SB (1987) Diverticulum of the female urethral roof managed endoscopically. *J Urol* 138: 147-148.
7. Fortunato P, Schettini M, Gallucci M (2001) Diagnosis and therapy of the female urethral diverticula. *Int Urogynecol J Pelvic Floor Dysfunct* 12: 51-57.
8. Crescenze IM, Goldman HB (2015) Female urethral diverticulum: Current Diagnosis and Management. *Curr Urol Rep* 16: 71.
9. Reeves FA, Inman RD, Chapple CR (2014) Management of symptomatic urethral diverticula in women: a single-centre experience. *European urology* 66: 164-172.
10. Leng WW, McGuire EJ (1998) Management of female urethral diverticula: a new classification. *J Urol* 160: 1297-1300.
11. Venyo A, Gopall A (2012) Female urethral diverticula: A review of the literature. *WebmedCentral UROLOGY* 3: WMC003428.
12. Lee JW, Fynes MM (2005) Female urethral diverticula. *Best Pract Res Clin Obstet Gyneacol* 19: 875-893.
13. Arbor A (2016) Urethral diverticulum in the female: a meta-analysis of modern series. *Minerva Gynecologica* 68: 186-210.
14. Hahn WY, Israel GM, Lee VS (2004) MRI of female urethral and periurethral disorders. *AJR Am J Roentgenol* 182: 677-682.
15. Han DH, Jeong YS, Choo MS, Lee KS (2007) Outcomes of surgery of urethral diverticula classified using magnetic resonance imaging. *Eur Urol* 51: 1664-1670.
16. Johnson KC, Rovner ES (2015) *Repair of Urethral Diverticula*. In *Female Pelvic Surgery* 165-177 Springer New York.
17. Chou CP, Huang JS, Yu CC, Pan HB, Huang FD (2005) Urethral diverticulum: diagnosis with virtual CT urethroscopy. *Am J Roentgenol* 184: 1889-1890.
18. Handel LN, Leach GE (2008) Current evaluation and management of female urethral diverticula. *Curr Urol Rep* 9: 383-388.
19. Hickey N, Murphy J, Herschorn S (2000) Carcinoma in urethral diverticulum: magnetic resonance imaging and sonographic appearance. *Urology* 55: 588-589.
20. Porpiglia F, Destefanis P, Fiori C, Fontana D (2002) Preoperative risk factors for surgery female urethral diverticula. *Our experience*. *Urol Int* 69: 7-11.
21. Leach GE, Sirls LT, Ganabathi K, Zimmern PE (1993) L N S C3: a proposed classification system for female urethral diverticula. *Neurourol Urodyn* 12: 523-531.
22. Hey W (1805) *Practical observations in surgery*. Humpheys, Philadelphia, USA.