

Epithelial Ingrowth: Visual Acuity and Astigmatism Results One Year after YAG Laser Treatment

Fuentes-Paez Graciana*, Soler Tomas Jr and Burillo S Ddo

Hospital Quirón Teknon, Clínica Oftalnova, Desp 198-199, Barcelona, Spain

*Corresponding author: Graciana Fuentes Páez; Calle Vilana 12 Desp 198.199, Barcelona, 08006, Spain, Tel: 34 933933198; Email: fupaez@yahoo.com

Received date: Jul 06, 2015; Accepted date: Sep 09, 2015; Published date: Sep 12, 2015

Copyright: © 2015 Graciana F et al. This is an open-access article distributed under the terms of the Creative Commons Attribution License, which permits unrestricted use, distribution, and reproduction in any medium, provided the original author and source are credited.

Abstract

Purpose: To assess the response of YAG laser for epithelial ingrowth in LASIK patients undergoing re-treatment with flap re-lift, after one year.

Materials and Methods: Prospective case series of LASIK patients with a symptomatic decrease in VA due to epithelial ingrowth (grades II-III), after retreatment with flap relift, with YAG laser (0.6-0.8 mJ) and followed-up during one year. Variables included pre and post YAG laser uncorrected visual acuity (UCVA, decimal scale), spherical equivalent (SE), topography astigmatism (SimK, 3.00 mm, and 5.00 mm zones). Data was registered and analyzed using Microsoft® Excel® 2013 (Microsoft Corporation), reported as mean, standard deviation (SD), and compared using paired t-student ($p \leq 0.05$ for significance).

Results: Nine patients were followed-up, for one year, 5 men and 4 women with mean age 46.8 ± 11.7 years. Pre/post results were: UCVA $0.75 \pm 0.12/0.96 \pm 0.09$ ($p=0.03$), astigmatism $0.5 \pm 0.68/0.10 \pm 0.22D$ ($p=0.03$), SE $0.48 \pm 0.46/0.25 \pm 0.42D$ ($p=0.24$), topography astigmatism $2.0 \pm 0.85/1.4 \pm 0.45D$ ($p=0.02$), Km $39.3 \pm 2.7/39.4 \pm 2.4D$ ($p=0.50$). For pseudophakic patients pre/post mean UCVA $0.75 \pm 0.24/0.83 \pm 0.17$ ($p=0.22$), SE $0.03 \pm 0.80D / 0.06 \pm 0.13D$ ($p=0.94$), astigmatism $0.49D \pm 0.59/0.13D \pm 0.25D$ ($p=0.94$), topographic astigmatism $2.8 \pm 1.7D/2.5D \pm 1.1D$ ($p=0.34$).

Conclusions: YAG laser treatment for symptomatic epithelial ingrowth, in LASIK patients after retreatment with flap relift, significantly improved UCVA and decreased subjective and topographic astigmatism. Clinical and topographical improvement in pseudophakic patients was not clinically significant.

Keywords: Cornea; Epithelial ingrowth; LASIK; YAG laser

Introduction

Epithelial ingrowth is a common complication presenting after flap re-lift, particularly when risk factors, as buttonholes, basal membrane dystrophies, debris, or interface bleeding, are present [1-3]. Clinical evolution is usually unpredictable and treatment is determined according to Machat's classification, grades I-III [1]. Epithelial ingrowth can go unnoticed or trigger symptoms, which include decreased VA, halos, and photophobia, and cause irregular astigmatism, flap border irregularity or even flap melting [1-7]. Grade II-III treatments include short-term observation, flap re-lifting and debridement (with or without mitomycin, alcohol, amniotic membrane, sutures, flap amputation, phototherapeutic keratectomy) and, more recently, YAG laser [1-9]. The latter treatment has been reported to successfully eliminate epithelial nests and improve visual acuity (VA) [9]. We report clinical and topographic results in patients with grade II-III epithelial ingrowth 1 year after treatment with YAG laser photodisruption.

Materials and Methods

Case series of patients with a symptomatic decrease in VA due to epithelial ingrowth (grades II-III), after LASIK retreatment, were followed up to one year after YAG laser treatment. Variables recorded

included pre and 1 year post YAG laser photodisruption uncorrected visual acuity (UCVA), spherical equivalent (SE), topography astigmatism (SimK, 3.00 mm, and 5.00 mm zones) using the ORBSCAN DP-3002 model, v [3-14]. (Technolas Perfect Vision, GmbH), and subjective refraction. After 6 months, topographic astigmatism was recorded for comparative purposes. Before the procedure, tetracaine chlorhydrate (1 mg) and oxybuprocaine (4 mg) (*Colircusí Anestésico Doble, Alcon Cusí S.A., El Masnou, Barcelona NdYAG laser (Alcon Surgical 3000 LE) was instilled in the eye to be treated. YAG laser was then directly performed (0.6-0.8 mJ) on the interface until most of the surface was covered and avoiding impact overlapping. 8-9 Post YAG laser treatment included topical tobramycin and dexamethasone (*Tobradex*®, Alcon Cusí, El Masnou- Barcelona) t.i.d. for 5 days and 0.4% hyaluronic acid (Aquoral, Farmigea S.p.A, Pisa, Italy) 5 times a day during one month. Data was recorded and analyzed using Microsoft® Excel® 2013 (Microsoft Corporation). Results were recorded as means, standard deviation (SD), and variables compared using paired t-student test.

Results

Nine LASIK patients with symptomatic epithelial ingrowth, after flap re-lift, were treated with YAG laser photodisruption and followed-up for one year. We studied 5 men and 4 women, mean age of 46.8 ± 11.7 years, 5 right eyes, 4 left eyes, and mean time before UCVA decrease, due to ingrowth, was 11.8 ± 12.7 months. No complications

were recorded during the procedure. Two patients had undergone previous surgical flap re-lifting and epithelium debridement before the YAG laser procedure, and 4 were pseudophakic. Evaporative dry eye syndrome, ocular Rosacea, or both, were observed in 3 patients who underwent YAG laser, exclusively. These were treated with lid hygiene and artificial tears during at least 6 months. One case required an additional YAG laser procedure, one month after performing the first YAG laser, due to lack of clinical improvement.

One case (65-year old pseudophakic woman) presented with corneal erosion, which was successfully treated with artificial tears, during 3 months. Her UCVA increased from 0.8 to 0.9 (no improvement in best corrected visual acuity; BCVA) and topography astigmatism decreased from 3.1D to 2.8D, one year after treatment. Table 1 reviews pre and post YAG laser results for all patients, after 12 months. Figure 1 compares case by case topographic astigmatism results after 6 and 12 months. Figure 2 displays mean topographic results one year after YAG laser for Sim K, on the 3.0mm and 5.0mm zones. Figure 3 shows pre and post YAG laser topographic astigmatism results in pseudophakic patients. Clinical and topographical follow-up of an epithelial ingrowth case treated exclusively with YAG laser is shown on Figure 4.

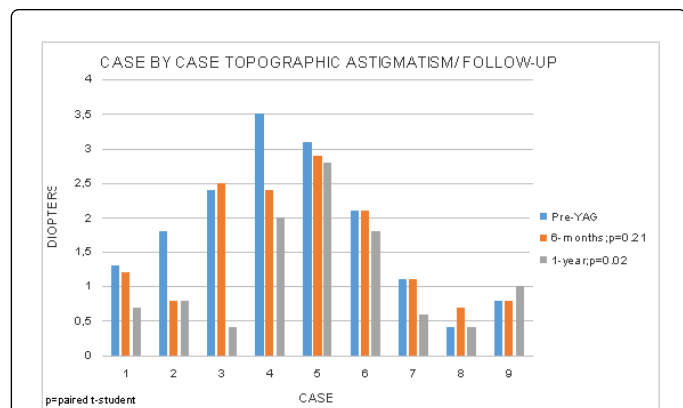


Figure 1: Case by case topography astigmatism results, pre, 6 months, and 1-year post YAG laser. Statistically significant changes were recorded after one year.

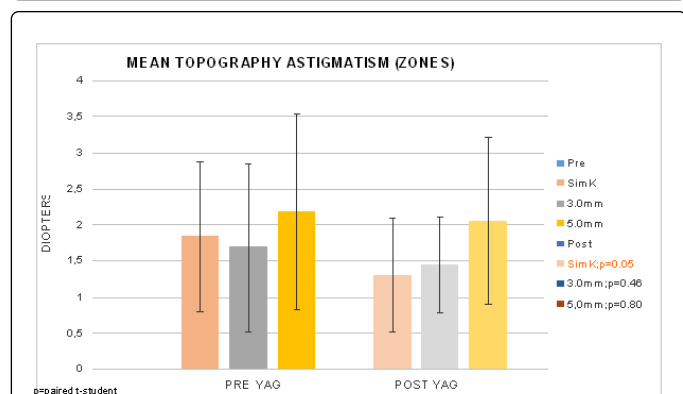


Figure 2: Corneal topographic astigmatism after one year; SimK, 3.0 mm, and 5.0 mm zones. Mean 3.0 mm and 5.0 mm zones astigmatism reductions zones was not statistically significant.

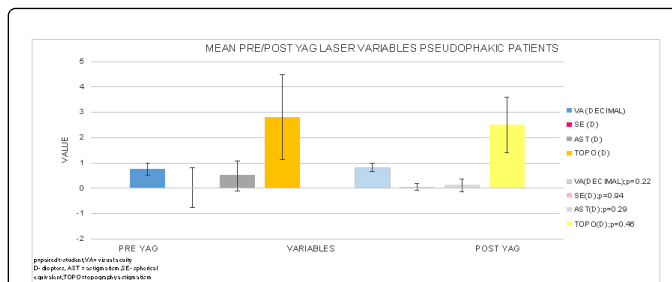


Figure 3: Mean results for pseudophakic patients. VA improvement astigmatism reduction (both subjective and topographic) were not statistically significant.

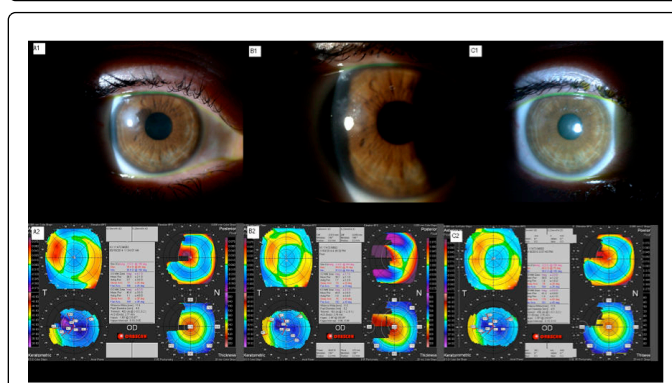


Figure 4: Clinical and topographic evolution of a case. A1 illustrates grade III epithelial ingrowth; A2: Corneal topography shows 3.5D astigmatism and a flattened profile corresponding to the ingrowth area B1 illustrates the post YAG laser clinical aspect and 2.4D corneal astigmatism, B2. C1 portrays a corneal translucent residual leukoma, one year after YAG laser. C2 shows 2.0D corneal astigmatism and a more regular anterior surface, after one year; mean Km from 38.5 to 39D.

Results for patients who had previously undergone unsuccessful flap re-lift and debridement, one year after YAG laser treatment, were: for the first case, pre-YAG laser uncorrected VA (UCVA) increased 0.6 (1.0 BCVA with +2.0 -1.0 × 180°; 1.9 D topography astigmatism) to post YAG laser UCVA 1.0 (1.2 BCVA with +0.75 and 1-3D topography astigmatism). In the second case, UCVA increased (0.5 to 0.9; no improvement in BCVA) and topography astigmatism decreased from 1.5 D to 0.6 D after one year.

Discussion

Post LASIK epithelial ingrowth is a fairly common complication, up to 32%, particularly after retreatment, flap complications, bleeding, etc., and treatment is determined by clinical evolution [1-3]. According to Machat's classification, grade I epithelial ingrowth (thin, transparent line, 1-2 cells, well limited, within 2mm of flap border, and non-progressive) requires observation and treatment for grades II (thicker nest, within 2 mm of flap border, no demarcation line and transparent cells without ocular surface pathology) and III (confluent greyish-white opacities well beyond 2 mm of the flap border, geographic areas made of up white necrotic cells, flap border

irregularities/thick flap margins) is surgical (flap re-lifting and debridement) [1].

Mean Results (N=7 eyes)	UCVA (Decimal)	Astigmatism (Diopters)	Spherical Equivalent (Diopters)	Topography Power (Diopters)	Astigmatic Km (Topography) (Diopters)
PRE-YAG	0.75 ± 0.12	0.50 ± 0.68	0.48 ± 0.46	2.0 ± 0.85	39.3 ± 2.7
POST-YAG	0.96 ± 0.09	-0.10 ± 0.22	0.25 ± 0.42	1.40 ± 0.45	39.4 ± 2.4
*p=*paired student t-	p=0.03	p=0.03	p=0.24	p=0.02	p=0.50

Table 1: Pre and post YAG laser mean results show statistically significant improvement in VA and astigmatism (both subjective and topography), after one year.

Histopathology has reported that early epithelial ingrowth resembles normal corneal epithelium, multilayered squamous epithelium, while late ingrowth are made up of clumps of amorphous material with scarce cells [10]. Classical treatment consists in flap re-lifting and surface debridement with or without sutures, phototherapeutic keratectomy, alcohol or mitomycin use, amniotic membrane, or even flap amputation [1-7]. YAG laser has been recently reported as a successful treatment for epithelial ingrowth, with important visual and topography profile improvement [8-9]. YAG laser high powered pulse induces plasma formation and shock wave photodisruption [11]. Eighty to 100% improvement in VA and topographic surface regularity have been reported in patients with epithelial ingrowth treated with YAG laser [8-9]. We report statistically significant improvement in mean VA, 0.75 to 0.96 (p=0.03). Nine out of 10 cases reported VA improvement of at least 1 line and in one case VA decreased one line. The latter had dry eye syndrome due to ocular rosacea and has been treated with artificial tears. All pseudophakic patients improved their VA, though not significantly.

Mean subjective and topography astigmatism decreased significantly, and topographic astigmatism improved in 90% of cases. The patient which failed to improve had been diagnosed with ocular rosacea and treated for dry eye syndrome. Mean topography astigmatism for the 3.0 mm and 5.0 mm zones also decreased but results were not statistically significant. Mean subjective and topography astigmatism also decreased in pseudophakic patients, though not statistically significant.

Previous flap re-lifting and mechanical debridement had been unsuccessful in two of our cases, which were later treated with YAG laser. UCVA and topography astigmatism also improved, one year after YAG laser treatment.

Our results show that YAG laser photodisruption for epithelial ingrowth, as a first treatment option or after failed surgical treatment, significantly improved UCVA and both subjective and topographic astigmatism, after 1-year follow up.

References

- Machat JJ, Slate S, Probst SE (1999) *The Art of LASIK* (2nd edn.) Thorofare, NJ SLACK, pp. 427-433.
- Pérez-Santonja JJ, Ayala MJ, Sakla HF, Ruíz-Moreno JM, Alió JL (1999) Retreatment after laser in situ keratomileusis. *Ophthalmology* 106: 21-28.
- Caster AI, Friess DW, Schwendeman FJ (2010) Incidence of epithelial ingrowth in primary and retreatment laser in situ keratomileusis. *J Cataract Refract Surg* 36: 97-101.
- Lahners WJ, Hardten DR, Lindstrom RL (2005) Alcohol and mechanical scraping for epithelial ingrowth following laser in situ keratomileusis. *J Refract Surg* 21: 148-151.
- Taneri S, Koch JM, Melki SA, Azar DT (2005) Mitomycin-C assisted photorefractive keratectomy in the treatment of buttonholed laser in situ keratomileusis flaps associated with epithelial ingrowth. *J Cataract Refract Surg* 31: 2026-2030.
- Kymionis G, Ide T, Yoo S (2009) Flap amputation with phototherapeutic keratectomy (PTK) and adjuvant mitomycin C for severe post-LASIK epithelial ingrowth. *Eur J Ophthalmol* 19: 301-303.
- Azar G, Doan S, Cochereau I, Gabison EE (2010) Management of post-LASIK recurrent epithelial ingrowth with flap melting using annular amniotic membrane graft. *J Cataract Refract Surg* 36: 2207-2208.
- Ayala MJ, Alió JL, Mulet ME, De La Hoz F (2008) Treatment of laser in situ keratomileusis interface epithelial ingrowth with neodymium:yttrium-aluminum-garnet laser. *Am J Ophthalmol* 145: 630-634.
- Ayala MJ, Alió JL, Mulet ME, De La Hoz F (2008) Treatment of laser in situ keratomileusis interface epithelial ingrowth with neodymium:yttrium-aluminum-garnet laser. *Am J Ophthalmol* 145: 630-634.
- Kim JM, Goel M, Pathak A (2014) Epithelial ingrowth - Nd:YAG laser approach. *Clin Experiment Ophthalmol* 42: 389-390.
- Asano-Kato N, Toda I, Hori-Komai Y, Takano Y, Dogru M, et al. (2005) Histopathological findings of epithelial ingrowth after laser in situ keratomileusis. *Cornea* 24: 130-134.
- Steinert RF, Puliato CA (1985) *The Nd:YAG laser in ophthalmology: principles and clinical applications of photodisruption*. WB Saunders, Philadelphia.