

Effectiveness of Ponseti Method for the Treatment of Congenital Talipes Equinovarus: Personal Experience

Vito Pavone^{*}, Gianluca Testa, Flavia Alberghina, Ludovico Lucenti and Giuseppe Sessa

Departments of General Surgery and Medical-Surgical Specialties, University of Catania, Italy

^{*}Corresponding author: Vito Pavone, Departments of General Surgery and Medical-Surgical Specialties, Orthopedics Section, University of Catania, Via Plebiscito 628, Catania, 95124, Italy, Tel: +390957435240; Fax: +39095350611; E-mail: clinortopedica@virgilio.it

Rec date: Jul 28, 2015, Acc date: Sep 04, 2015, Pub date: Sep 08, 2015

Copyright: © 2015 Pavone V, et al. This is an open-access article distributed under the terms of the Creative Commons Attribution License, which permits unrestricted use, distribution, and reproduction in any medium, provided the original author and source are credited.

Abstract

Congenital talipes equinovarus, also known as clubfoot, is a relatively common skeletal deformity characterized by an excessively turned-in foot and a high medial longitudinal arch.

Three different forms of this disorder have been identified: positional or postural, idiopathic, and teratogenic or syndromic. The etiopathogenesis of this anomaly is not clearly known. Two genes, PITX-1 and RBM-10, have recently been reported to play direct or indirect roles in the pathogenesis of clubfoot. Clinical diagnosis is at a glance; X-ray analysis is initially unnecessary but should be used after treatment to follow the outcome.

Various surgical or nonsurgical methods of treatment have been applied to treat this disorder, including the Kite, Cincinnati, Bensahel/Dimeglio, and Turco techniques. Actually the Ponseti method has been considered the gold standard technique for treatment of this disorder.

We treated 132 children affected by clubfoot using the Ponseti method, with good/excellent results in 94% of the treated feet. Our experience confirms the effectiveness of the Ponseti method in the treatment of clubfoot.

Keywords: Congenital talipes; clubfoot; Etiology; Diagnosis; Treatment; Ponseti method

Introduction

Congenital talipes equinovarus (CTEV), also known as congenital clubfoot, is one of the most common congenital skeletal deformities and involves malalignment of the calcaneo-talar-navicular complex. CTEV is characterized by irreducible equinus, varus of the hindfoot, adduction of the forefoot, cavus, and an “empty” heel pad with associated calf muscle atrophy. To describe this anomaly, the acronym CAVE is used to indicate the main components of this condition, cavus-adductus-varus-equinus, that underlie the anatomic condition of plantar flexion (cavus) of the first ray. Most commonly, clubfoot presents as an isolated anomaly (idiopathic CTEV) but can also be associated with different disorders and malformative syndromes, such as distal arthrogryposis, myotonic dystrophy, chromosomal defects, sacral agenesis, spinal muscular atrophy, spina bifida, myelomeningocele and skeletal lower limb abnormalities [1,2].

From an etiological point of view, three different forms of CTEV have been recognized: positional or postural, idiopathic, and teratogenic or syndromic. The positional clubfoot is a molding abnormality due to the abnormal position that the foot held in the uterus; it is flexible at the physical examination and usually heals spontaneously. In the idiopathic form, the deformity is linked to non-specific single muscle-skeletal involvement while the child is otherwise normal, presenting a primary and local dysplasia of the affected tissue. In the teratogenic or syndromic category the clinical features are linked to an underlying complex disorder, the anomaly is much more rigid and more difficult to treat.

This anomaly causes severe emotional problems in the parents of affected children; therefore, finding a correct and rapid treatment is relevant. There are various surgical and non-surgical methods to treat CTEV, but the results reported in the literature [3-8] suggest that the Ponseti method has become the gold standard of care for treatment of CTEV. We have applied this technique to treat CTEV for many years. The aim of this study is to report our experience regarding the Ponseti treatment regimen.

Material and Methods

From June 2005 to September 2014, 132 patients (207 idiopathic clubfeet) were enrolled at the Orthopaedic Clinic of Catania University and followed prospectively up to December 2014: 91 patients were male and the anomaly was bilateral in 65 cases (49.2%).

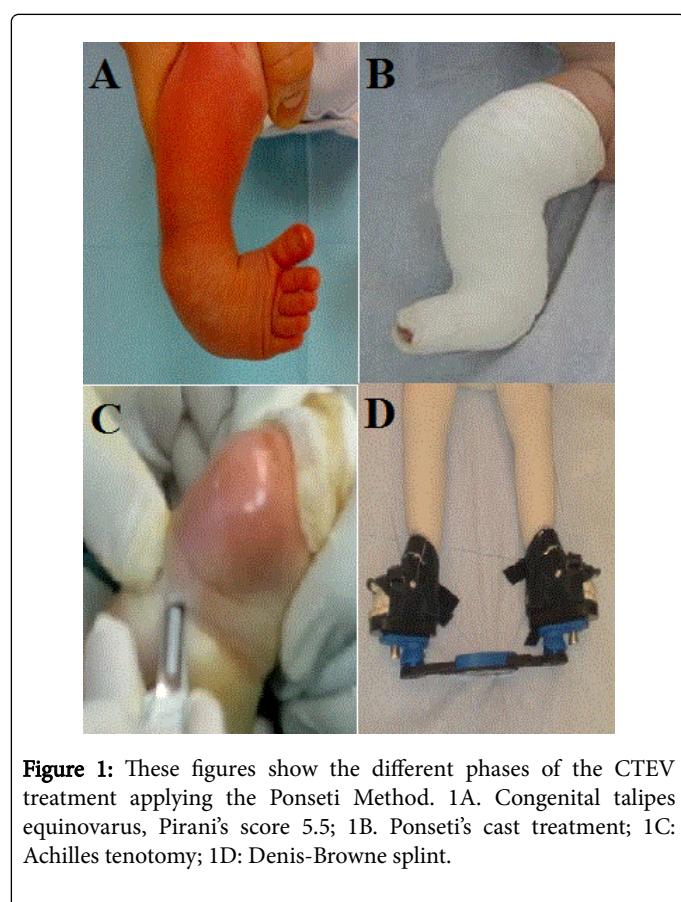
General examination was performed to rule out the possible complex syndromic malformations sometimes associated with CTEV; particular attention was dedicated toward excluding underlying neuromuscular disorders.

All the patients were treated with the Ponseti Method, according to this sequence: corrective manipulations, serial casting, tenotomy and bracing.

The mean age at onset of treatment was 107 days (range 4-210 days) and the mean severity of the clubfoot deformity, assessed by the Pirani Severity score [9], was 5.56 points (range 4.3-6 points). Clinical evaluation of the deformity was performed using the functional Ponseti Scoring System [3].

Results

Mean follow-up was 69 months. The total numbers of Ponseti casts before tenotomy, details of the tenotomy, and compliance with the CTEV brace were recorded. On average, 6.6 (range 4-13) casts were necessary before performing the tenotomy. Tenotomy was carried out by a single surgeon (V.P.) in a total of 155 feet (74.9%), always performed in an operating room, with the patient under general anesthesia, by a percutaneous approach. Achilles tenotomy was performed after the foot had been abducted to at least 60° and when there were less than 10° of dorsiflexion. The mean post-operative Pirani score was 0.35, showing good/excellent results in 194 (93.7%) feet (Figures 1A-1D). Only 5 patients (3.8%), 8 clubfeet (3.9%), relapsed. Poor compliance with the Denis Browne splint was thought to be the main cause of failure (Table 1).



Discussion

CTEV is the most common abnormality of the musculoskeletal system. The incidence of CTEV is between 1 and 2 per 1000 live births within the Caucasian population, but there are significant racial variations; CTEV is more common in the Polynesian population and less common in the Chinese [1,2,10]. The incidence of CTEV in Sicily was previously reported by Pavone et al. [11]: among the 801,324 newborns recorded in Sicily between January 1991 and December 2004, the prevalence of clubfoot was 1.03 per 1000 births, in accord with the most recent data from the literature [3].

Different genetic, developmental, and environmental factors predispose the etiopathogenesis of congenital clubfoot [11-15]. Family

studies demonstrated a higher prevalence among first-degree relatives and a concordance of 33% among monozygotic twins, which decreased to 3% for dizygotic twins. Genetic susceptibility can also explain the double incidence of CTEV among males in comparison to females [13]. A five-generation family with members affected by asymmetrical right-sided predominant idiopathic CTEV with autosomal dominant inheritance with incomplete penetrance was reported by Gurnett et al. [15]. In the same family, other members showed other limb malformations, including patellar hypoplasia, oblique talus, tibia hemimelia, and preaxial polydactyly. In this family, a single missense mutation in PITX-1, a bicoid-related homeodomain transcription factor involved in limb formation, played a relevant role in the pathogenesis of these limb abnormalities [15]. The genes involved in congenital joint contractures characterize specific syndromes, including distal arthrogyposis. Moreover, anomalies in chromosomal deletions and duplications have been thought to be responsible for CTEV [14]. RNA binding motif protein 10 (RBM-10) mutations were related to TARP syndrome, in which the patient shows talipes equinovarus in association with an atrial septal defect and Robin sequence [14].

Patients	132
Feet	207
Males	91 (68.9%)
Bilaterality	65 (49.2%)
Initial Pirani's score	5.56 (4.3-6)
Mean follow-up	69 months
Mean age at start of treatment	107 (4-210) days
Mean number of casts	6.6 (4-13)
Tenotomy (feet)	155 (74.9%)
Good/Excellent outcomes (feet)	194 (93.7%)
Relapses (feet)	8 (3.9%)

Table 1: Summary of case series treated with the Ponseti Method.

Recently, an important role in the etiopathogenesis of CTEV was related to mal development of the anterior tibial artery and its derivative with the dorsal pedis artery, presumably leading to muscular and arterial hypoplasia. On the other hand, the presence of muscular atrophy in some patients with CTEV is well-known and recognizable before starting treatment [12].

The diagnosis is clinical even if prenatal detection may be important to differentiate the idiopathic and syndromic forms of CTEV. Diagnostic evaluation is typically represented by clinical pictures with hindfoot varus and equinus and forefoot cavus and adductus. The degree of flexibility is variable and almost all the patients show signs of calf atrophy.

The most widely-used classification of CTEV is based on six clinical signs, three for the midfoot (curvature of the lateral border, severity of the medial crease, and medial talar head cover) and three for the hindfoot (rigidity of equinus, severity of posterior crease, and emptiness of the heel). Attributing one point for severe, 0.5 for moderate, and 0 for no deformity, the Pirani score ranges from 0 to 6, where 6 indicates the highest severity of malformation [9].

Radiographic evaluation is not necessary and most experts prefer to use radiological assessment after the treatment to follow the outcome. In this case, anteroposterior and lateral view radiograms are recommended [7].

For the treatment of congenital clubfoot, various techniques have been proposed that are more or less invasive (Figure 2). The previous bloodless approach was often unsatisfactory and many surgeons preferred to proceed with an open approach that became popular in the 1980s.

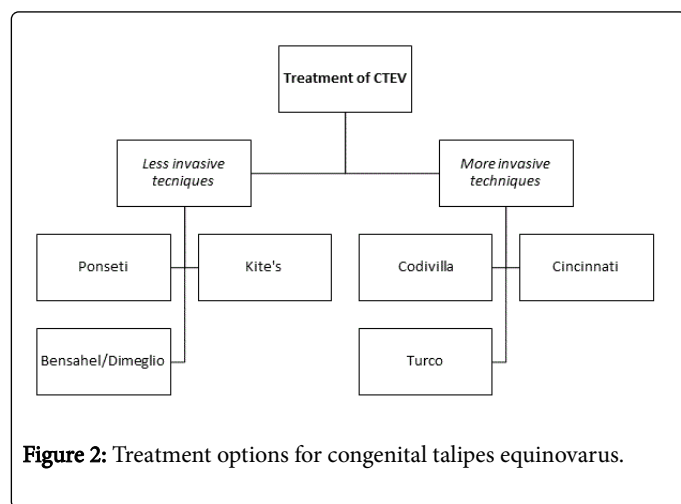


Figure 2: Treatment options for congenital talipes equinovarus.

In 1932, Kite [16], in opposition to the methods used at that time, published a gentler manipulation method aimed at correcting each component of the deformity separately, not simultaneously: adduction correction consisted of foot abduction with the fulcrum in the midfoot and support in the calcaneocuboid joint, while varus correction was performed with hindfoot eversion with wedges or plaster cast changes. The subsequent manipulations aimed to force the abduction and pronation of the forefoot. After adduction and inversion correction, the forefoot and hindfoot equinus deformities were corrected with progressive dorsiflexion [16,17]. However, Kite's method, manipulation techniques, and different plaster cast techniques resulted in complications such as incomplete correction of the deformities, with complications consisting of feet with residual cavus, "rocker-bottom" feet, lateral torsion of the ankle, flattening and deformation of the upper side of the talar body, navicular subluxation, ligament and capsular rigidity, and others. Because of the poor results performed with the technique reported by Kite, some orthopedists resumed surgical treatment when there was resistance to correction by the conservative technique [17].

The emphasis on non-operative management stimulated interest in French method [18], which requires daily manipulations of the newborn's clubfeet by a skilled physiotherapist and temporary immobilization with elastic and non-elastic adhesive taping. Most of the improvement occurs during the first three months of treatment. If successful, the program continues and is performed daily by the parents until the child is walking. A study of patients with moderate-severe clubfeet treated with the French Method showed poor results in 20.4% of the cases. Surgery was not required in 42% of the feet, 9% had a tenotomy of the Achilles tendon, 29% needed a posterior release, and 20% needed a comprehensive posteromedial release [19].

Concerning surgical techniques, the first approach was proposed by Codivilla, which consists of Z-lengthening of the Achilles tendon,

postero-medial soft tissue release, and, sometimes, anterior tibial muscle surgery. After surgery, a cast was immediately performed and kept for a month [20]. Pazzaglia et al. studied 30 patients with congenital clubfoot who were treated surgically by a slightly modified Codivilla technique; the patients showed a good final outcome in 41% of the cases, fair in 29%, and unsatisfactory in 30% after a mean ten years of follow-up [20].

Another widely-used procedure was promoted by Turco [21], who reported the first complete one-stage posteromedial release with the correction of the calcaneus deformity beneath the talus and complete subtalar release (lateral, posterior, and medial), including the release of the calcaneofibular ligaments [21]. Each foot underwent the same operation, regardless of the severity. Most of the orthopedic specialists that favored the surgical approach agreed that the surgery frequently caused foot complications [22]. The unsatisfactory results were, for the most part, a consequence of overcorrection. Dobbs et al. [23] published the long-term results after a minimum follow-up of 25 years in patients who undergone a Turco-style release: 87% had more than one operation, the second usually at the age of adolescence. In a study by Laaveg, using Ponseti scores and the Turco procedure, the results were unsatisfactory with 0% excellent, 33% good, 20% fair, and 47% poor outcomes, showing significantly reduced scores in physical functioning, general health, vitality, social functioning, and physical components [3].

Beginning in 1983, a Cincinnati incision was used to perform the comprehensive release and obtain correction of the foot deformity in all three planes [24,25]. It consists of incision at the medial aspect of the foot, performing a z-lengthening of the Achilles tendon, and is associated with capsulotomies of the posterior tibiotalar and posterior tibiocalcaneal joints; the posterior tibial tendon could be z-lengthened, incising the dorsal talonavicular ligament, plantar calcaneonavicular ligament, and Henry's knot. The Cincinnati technique allowed a wide approach of the foot and ankle, making it easier to see and liberate the soft tissue of interest [25].

More recently, the treatment of congenital clubfoot has changed. The spread of the technique described by Ponseti [26] has been remarkable, both in the developed and developing worlds, as shown in several studies [3-8,27]. The Ponseti method consists of corrective manipulation of the deformity to address the various components of the deformity, from cavus to equinus: cast applications, renewed weekly for the first 5-10 weeks; percutaneous Achilles tenotomy; and the application of a Denis Browne splint, dressed day and night for the first three months, then for 14/16 hours per day up to 3 or 4 years of age in order to maintain the foot in abduction and dorsiflexion.

Incorrect casting technique, improper tenotomy, under-corrected deformity, ill-fitting splints and the poor compliance of the patients' parents sometimes due to a poor socio-economic situation may interfere with successful outcomes and are the most common problems [28-31].

We have proved the effectiveness of the Ponseti method in the treatment of children with CTEV and confirm the validity of this kind of treatment, having obtained good/excellent results in 94% of the treated feet. With this technique, it has been possible to prevent open joint surgery and allow correction of the deformity.

In conclusion, many different treatment options are available. The techniques that use an open, invasive approach seem to lead to a rigid, weak, and painful foot due to significant issues related to scarring and contractures.

The Ponseti method currently appears to be the gold standard [32] in the treatment of clubfoot, leading to a straight, painless, plantigrade, flexible, normal-looking foot, which allows the child to live a regular daily life, participating in common sport or recreation activities.

References

1. Hosalkar HS, Spiegel DA, Davidson RS (2007) Talipes Equinovarus (Clubfoot). *Nelson Textbook of Pediatrics* 18: 2777-2778.
2. Wallach DM, Davidson RS (2005) Pediatric lower limb disorders. In Dormans JP (editor): *Core knowledge in Orthopaedics: Pediatric Orthopaedics*. Philadelphia, Mosby 197-223.
3. Laaveg SJ, Ponseti IV (1980) Long term results of treatment of congenital clubfoot. *J Bone Joint Surg Am* 62: 23-31.
4. Porecha MM, Parmar DS, Chavda HR (2011) Mid-term results of Ponseti Method for the treatment of congenital idiopathic clubfoot (a study of 67 clubfeet with mean five year follow-up). *J Orthop Surg Res* 6: 3.
5. Bor N, Coplan JA, Herzenberg JE (2009) Ponseti treatment for idiopathic clubfoot: minimum 5-year follow up. *Clin Orthop Relat Res* 467: 1263-1270.
6. Morcuende JA, Abbasi D, Dolan LA, Ponseti IV (2005) Results of an accelerated Ponseti protocol for clubfoot. *J Pediatr Orthop* 25: 623-626.
7. Radler C (2015) The Ponseti method for the treatment of congenital clubfoot: review or the current literature and treatment recommendations. *Int Orthop* 37: 1747-1753.
8. Pavone V, Testa G, Costarella L, Pavone P, Sessa G (2013) Congenital idiopathic talipes equinovarus: an evaluation in infants treated by the Ponseti method. *Eur Rev Med Pharmacol Sci* 17: 2675-2679.
9. Chu A, Labar AS, Sala DA, van Bosse HJ, Lehman WB (2010) Clubfoot classification: correlation with Ponseti cast treatment. *J Pediatr Orthop* 30: 695-699.
10. Paton RW, Fox AE, Foster A, Fehily M (2010) Incidence and aetiology of talipes equino-varus with recent population changes. *Acta Orthop Belg* 76: 86-89.
11. Pavone V, Bianca S, Grosso G, Pavone P, Mistretta A, et al. (2012) Congenital talipes equinovarus: an epidemiological study in Sicily. *Acta Orthop* 83: 294-298.
12. Kruse L, Gurnett CA, Hootnick D, Dobbs MB (2009) Magnetic resonance angiography in clubfoot and vertical talus: a feasibility study. *Clin Orthop Relat Res* 467: 1250-1255.
13. Seo J, Choi IH, Lee JS, Yoo Y, Kim NK, et al. (2015) Rare cases of congenital arthrogyriosis multiplex caused by novel recurrent CHRNNG mutations. *J Hum Genet* 60: 213-215.
14. Gripp KW, Hopkins E, Johnston JJ, Krause C, Dobyns WB, et al. (2011) Long-term survival in TARP syndrome and confirmation of RBM10 as the disease-causing gene. *Am J Med Genet A* 155A: 2516-2520.
15. Gurnett CA, Alaei F, Kruse LM, Desruisseau DM, Hecht JT, et al. (2008) Asymmetric lower-limb malformations in individuals with homeobox PITX1 gene mutation. *Am J Hum Genet* 83: 616-622.
16. Kite JH (2003) Principles involved in the treatment of congenital clubfoot. 1939. *J Bone Joint Surg Am* 85A: 1847.
17. Karski T, Wosko I (1989) Experience in the conservative treatment of congenital clubfoot in newborns and infants. *J Pediatr Orthop* 9: 134-136.
18. Bensahel H, Catterall A, Dimeglio A (1990) Practical applications in idiopathic clubfoot: a retrospective multicentre study in EPOS. *J Pediatr Orthop* 10: 186-188.
19. Richards BS, Johnston CE, Wilson H (2005) Nonoperative clubfoot treatment using the French physical therapy method. *J Pediatr Orthop* 25: 98-102.
20. Pazzaglia UE, Riccardi C, Valle L, Pedrotti L, Finardi E (1992) Clinical and radiographic evaluation of the Codivilla method of surgical correction of congenital club foot. Medium-term follow-up of 235 cases. *Ital J Orthop Traumatol* 18: 371-378.
21. Turco VJ (1979) Resistant congenital club foot--one-stage posteromedial release with internal fixation. A follow-up report of a fifteen-year experience. *J Bone Joint Surg Am* 61: 805-814.
22. Gray K, Pacey V, Gibbons P, Little D, Frost C, et al. (2014) Interventions for congenital talipes equinovarus (clubfoot). *Cochrane Database Syst Rev* 4: CD008602.
23. Dobbs MB, Nunley R, Schoenecker PL (2006) Long-term follow up of patients with clubfeet treated with extensive soft-tissue release. *J Bone Joint Surg Am* 88: 986-996.
24. Smith PA, Kuo KN, Graf AN, Krzak J, Flanagan A, et al. (2014) Long-term Results of comprehensive clubfoot release versus the Ponseti Method: Which is better? *Clin Orthop Relat Res* 472: 1281-1290.
25. Sodre H, Bruschini S, Nery C, Mizusaki J (1994) The Cincinnati Approach in Clubfeet. *The Clubfoot* 201-207.
26. Ponseti IV (1996) Congenital clubfoot: fundamentals of treatment. *The J Bone Joint Surg* 79: 477-477.
27. Zions LE, Sangiorgio SN, Cooper SD, Ebramzadeh E (2015) Does Clubfoot Treatment Need to Begin As Soon As Possible? *J Pediatr Orthop*.
28. Ippolito E, Farsetti P, Caterini R, Tudisco C (2003) Longterm comparative results in patients with congenital clubfoot treated with two different protocols. *J Bone Joint Surg Am* 85: 1286-1294.
29. Morcuende JA, Dolan LA, Dietz FR, Ponseti IV (2004) Radical reduction in the rate of extensive corrective surgery for clubfoot using the Ponseti method. *Pediatrics* 113: 376-380.
30. Goksan SB (2002) Treatment of congenital clubfoot with the Ponseti Method. *Acta Orthop Traumatol Turc* 36: 281-287.
31. Bor N, Herzenberg JE, Frick SL (2006) Ponseti management of clubfoot in older infants. *Clin Orthop Relat Res* 444: 224-228.
32. Ošťádal M, Chomiak J, Dungal P, Frydrychová M, Burian M (2013) Comparison of the short-term and long-term results of the Ponseti method in the treatment of idiopathic pes equinovarus. *Int Orthop* 37: 1821-1825.