



## Early Postoperative Intraocular Pressure Elevation after Vitreoretinal Surgery

Pei Xu<sup>1, 2, 3</sup>, Ting Xia<sup>1, 4</sup> and Jianbin Chen<sup>1\*</sup>

<sup>1</sup>Department of Ophthalmology, Tongji Hospital, Huazhong University of Science and Technology, Wuhan, Hubei, 430030, People's Republic of China

<sup>2</sup>Department of Ophthalmology and Visual Sciences, University of Texas Medical Branch, Galveston, Texas, 77555, United States

<sup>3</sup>Department of Neuroscience and Cell Biology, University of Texas Medical Branch, Galveston, Texas, 77555, United States

<sup>4</sup>Department of Ophthalmology, Puai Hospital, Huazhong University of Science and Technology, Wuhan, Hubei, 430030, People's Republic of China

\*Corresponding author: Jianbin Chen, Department of Ophthalmology, Tongji Hospital, Huazhong University of Science and Technology, Wuhan, Hubei, 430030, People's Republic of China, Tel: +8613886112782; E-mail: jbchn@yahoo.com

Received date: January 16, 2017; Accepted date: February 16, 2017; Published date: February 20, 2017

Copyright: ©2017 Xu P, et al. This is an open-access article distributed under the terms of the Creative Commons Attribution License, which permits unrestricted use, distribution, and reproduction in any medium, provided the original author and source are credited.

### Abstract

**Objective:** The evaluation of intraocular pressure (IOP) after vitreoretinal surgery is critical to ensure the normal function of the eye. The purpose of this study was to determine the incidences and risk factors of early postoperative IOP elevation after vitreoretinal surgery.

**Method:** Data were collected and retrospectively analyzed from 150 patients (150 eyes) who received vitreoretinal surgery from March 2012 to December 2012 in Tongji Hospital. IOP was measured before surgery and on day 1, 2, 3, 4-7 after surgery by Goldmann applanation tonometer. Ocular hypertension was defined as IOP  $\geq$  24 mmHg. The incidences and risk factors were analyzed.

**Results:** 87 of the 150 patients were male and 63 were female. The IOP was elevated significantly in 54 eyes (36.00%) within 1 week after vitreoretinal surgery. Among them, 31 eyes (57.40%) occurred on day 1; 14 eyes (25.93%) occurred on day 2. The incidences of elevated IOP between different primary diseases had no statistical difference ( $p > 0.05$ ). However, patients with proliferative diabetic retinopathy (PDR), and rhegmatogenous retinal detachment (RRD) with proliferative vitreoretinopathy (PVR) grade  $\geq$  C2, had higher rates of IOP elevation. Vitrectomy combined with cataract surgery or scleral buckling had no significant difference in IOP elevation compared with vitrectomy only ( $p > 0.05$ ). The rate of IOP elevation between 20G pars-plana vitrectomy (41.76%) and 23G pars-plana vitrectomy (27.40%) had statistical difference ( $p = 0.033$ ). The incidence of IOP elevation with intraocular tamponade of C3F8 was significantly higher than simple vitrectomy ( $\chi^2 = 7.723$ ,  $p = 0.005$ ), while with silicone oil, the difference was not significant ( $\chi^2 = 3.627$ ,  $p > 0.05$ ).

**Conclusion:** IOP measurement after vitreoretinal surgery is important to monitor and prevent unintentional high IOP as it is a common complication after vitreoretinal surgery. The risk factors of early IOP elevation include the 20G pars-plana vitrectomy and C3F8 injection. Early treatment of IOP may prevent IOP spike to protect the vision.

**Keywords:** Intraocular pressure; Vitreoretinal surgery; 20G pars-plana vitrectomy; 23G pars-plana vitrectomy; Postoperative complication; C3F8; Silicone oil

### Introduction

With the development of novel instruments and techniques, vitreoretinal surgery has been more and more widely used in the recent 50 years to treat a large variety of retinal pathology, such as retinal detachment, macular holes, epiretinal membranes, and proliferative vitreoretinopathy. Despite the accumulation of surgical experience, complications are still not rare in clinical practice, and some of which may have severe consequences. IOP elevation is one of the most common postoperative complications in vitreoretinal surgery. High IOP causes pain and discomfort in patients, more severely, the functionality of the eye may be permanently damaged. Therefore, a close monitor of IOP after vitreoretinal surgery is an important and routine examination in clinic. The incidence of postoperative IOP elevation has been reported as 3.6% to 22.2%; within 48 h, up to 40% of patients experienced an increased IOP [1-3]. Several risk factors have

been related with high IOP after vitreoretinal surgery, such as the procedure of the surgery, the application of tamponade and the primary diseases of the patients [1,4,5]. However, these observations were conducted in different clinical studies separately; the data were collected from few hours to 1 day, or 1 month in the postoperative period [1,4-6]. The purpose of this study was to determine the incidence and risk factors of elevated IOP in the early stage (day 1, 2, 3, 4-7) after vitreoretinal surgery.

### Methods

#### Patient cohort

Medical histories obtained from 150 patients (87 males and 63 females) undergoing vitreoretinal surgery between March, 2012 and December 2012 in Tongji Hospital were retrospectively reviewed. The average age was  $50.1 \pm 6.5$  years (age range 3 to 79 years). As to the primary diseases, 14 eyes were ocular injuries, 36 eyes were PDR, 25 eyes were vitreous hemorrhage caused by retinal vascular diseases, 18 eyes were RRD with PVR grade  $\geq$  C2, 88 eyes were RRD with PVR

grade <C2. Exclusion criteria include: patients preoperative IOP above 29 mmHg or diagnosed with glaucoma or had family history of glaucoma, iris neovascularization, uveitis, prior intraocular surgery and penetrating eye injuries. All surgeries were performed by a single, experienced vitreoretinal surgeon. All the patients received 20G or 23G pars-plana vitrectomy (PPV). According to the intraoperative situation, additional procedures, such as scleral buckling, phacoemulsification with or without intraocular lens implantation, endolaser retinal photocoagulation, and endotamponades were performed during PPV. Endotamponades included balanced salt solution (BSS), gas (C3F8) and silicone oil. Operations ended up with normal IOP. Informed consent was obtained from all patients in this study.

### IOP assessment

IOP was measured by Goldmann applanation tonometry on day 1, 2, 3, 4-7 after vitreoretinal surgery [6]. The average of 3 measurements was recorded.

### Definition of IOP elevation

IOP elevation was defined as IOP  $\geq$  24 mmHg and prospective indication for treatment postoperatively was defined as  $\geq$  30 mmHg [7,8].

### Follow-up and treatment for IOP elevation postoperatively

Patients were followed up at one week, 2 weeks, 4 weeks, 6 weeks, 2 months, 3 months, 6 months and 12 months. Examinations included best-corrected visual acuity (BCVA), IOP, anterior segment detection by slit lamp and fundus examination via indirect ophthalmoscopy. Eyes with IOP  $\geq$  30 mmHg were treated with topical or systemic antiglaucomatous medication, anterior chamber paracentesis, laser iridoplasty, and inferior iridectomy [9]. Oil removal with or without concurrent glaucoma surgery may be required in eyes with uncontrolled high IOP after silicone oil injection.

### Statistical analysis

Statistical analyses were performed with SPSS 19 software (IBM, Armonk, NY, USA). Parametric data were presented as mean  $\pm$  standard deviation (SD). Chi-square tests were used to compare the categorical data.  $P < 0.05$  was accepted as statistically significant.

## Results

### The incidences of early IOP elevation after vitreoretinal surgery

IOP elevation occurred within one week after vitreoretinal surgery (54 of 150 eyes, 36.00%). As shown in Figure 1, most patients experienced high IOP at day 1 (31 eyes, 57.40%) and day 2 (14 eyes, 25.93%) postoperatively. These data were in accordance with Han's study [10].

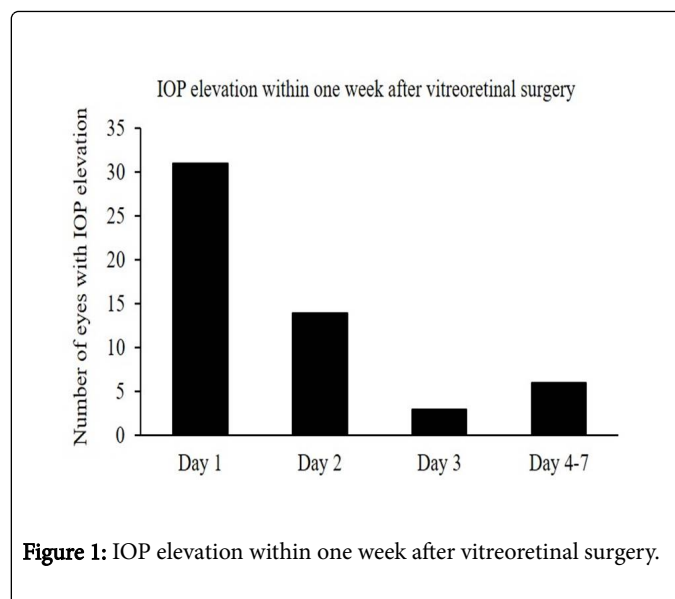


Figure 1: IOP elevation within one week after vitreoretinal surgery.

### Early IOP elevation after vitreoretinal surgery in patients with different primary diseases

In 36 eyes with PDR, high IOP occurred in 15 eyes (41.76%). In 18 RRD eyes with PVR grade  $\geq$  C2, high IOP occurred in 10 eyes (55.56%). In 38 RRD eyes with PVR grade <C2, high IOP occurred in 13 eyes (34.21%). In 25 eyes with vitreous hemorrhage caused by retinal vascular diseases, high IOP occurred in 7 eyes (28.00%). In 14 eyes with traumatic vitreoretinopathy, high IOP occurred in 4 eyes (28.57%). Among the rest of 19 eyes, 5 experienced high IOP (26.31%). Chi-square tests were used to analyze whether different primary diseases affected the incidences of early elevated IOP after vitreoretinal surgery. The Chi-square value was 5.345 ( $p = 0.375$ ), which indicated the incidences of early IOP elevation in eyes with different primary diseases had no statistical difference.

### Early IOP elevation after vitreoretinal surgery in patients with different endotamponades

Endotamponades included BSS, gas (C3F8) and silicone oil. 5 of 30 eyes with BSS experienced high IOP (16.67%); 25 of 53 eyes with C3F8 experienced high IOP (47.17%); 24 of 67 eyes with silicone oil experienced high IOP (35.82%). Chi-square tests were used to analyze whether different endotamponades affected the incidences of early elevated IOP after vitreoretinal surgery. The Chi-square value was 7.738 ( $p = 0.021$ ), which suggested the incidences of early IOP elevation in eyes with different endotamponades had significant difference. Then, we tested the differences between C3F8 and silicone oil group ( $\chi^2 = 1.578$ ,  $p = 0.209$ ), silicone oil and BSS group ( $\chi^2 = 3.627$ ,  $p = 0.057$ ), as well as C3F8 and BSS group ( $\chi^2 = 7.723$ ,  $p = 0.005$ ). The results implicated intraocular tamponade of C3F8 increased the rate of early IOP elevation after vitreoretinal surgery significantly (Tables 1 and 2).

Primary Diseases	Total Eye Number	High IOP eye number	Incidences of IOP (%)
PDR	36	15	41.65

RRD with PVR grade $\geq$ C2	18	10	55.56
RRD with PVR grade $<$ C2	38	13	34.21
Vitreous hemorrhage caused by retinal vascular diseases	25	7	28
Traumatic Vitreoretinopathy	14	4	28.57
Others	19	5	26.31

**Table 1:** The incidences of early IOP elevation in eyes with different primary diseases.

Endotamponades	Total eye number	High IOP eye number	Incidences of IOP (%)
BSS	30	5	16.67
C3F8	53	25	47.17
Silicone Oil	67	24	35.82

**Table 2.** The incidences of early IOP elevation in eyes with different endotamponades.

### Early IOP elevation after vitrectomy combined with cataract surgery

In 37 eyes performed vitrectomy combined with cataract surgery, high IOP occurred in 18 eyes (48.65%). In 113 eyes underwent only

vitreoretinal surgery, high IOP occurred in 36 eyes (31.86%). The Chi-square value was 3.411 ( $p=0.065$ ), which indicated combined cataract surgery in vitrectomy did not affect the incidence of early postoperative IOP elevation.

Procedure	Total eye number	High IOP eye number	Incidences of IOP (%)
PPV	113	36	31.86
PPV combined with cataract surgery	37	18	48.56

**Table 3:** The incidences of early IOP elevation in eyes performed vitrectomy combined with or without cataract surgery.

### Early IOP elevation after vitrectomy combined with scleral buckling

In 19 eyes performed vitreoretinal surgery combined with scleral buckling, high IOP occurred in 9 eyes (47.37%). In 131 eyes underwent

only vitreoretinal surgery, high IOP occurred in 45 eyes (34.35%). The Chi-square value was 1.220 ( $p=0.269$ ), which suggested combined scleral buckling in vitrectomy did not affect the incidence of early postoperative IOP elevation.

Procedure	Total eye number	High IOP eye number	Incidences of IOP (%)
PPV	131	45	34.35
PPV combined with cataract surgery	19	9	47.37

**Table 4.** The incidences of early IOP elevation in eyes performed vitrectomy combined with or without scleral buckling.

### Early IOP elevation after 20G or 23G PPV

77 eyes received 20G PPV, 34 of them experienced early postoperative IOP elevation (41.76%). 73 eyes underwent 23G PPV, 20 of them experienced early postoperative IOP elevation (27.40%).

The Chi-square value was 4.568 ( $p=0.033$ ), which implicated 20G PPV increased the rate of early postoperative IOP elevation.

Procedure	Total eye number	High IOP eye number	Incidences of IOP (%)
20G PPV	77	34	41.76
23G PPV	73	20	27.4

**Table 5:** The incidences of early IOP elevation after 20G or 23G PPV.

## Discussion

Vitreoretinal surgery is an effective treatment for a large variety of retinal pathology. Despite the application of novel instruments and techniques, as well as the accumulation of surgical experience, complications are still not rare in clinical practice. IOP elevation is a common postoperative complication following vitreoretinal surgery. High IOP not only causes pain and discomfort in patients, but also impair the functionality of the eye. Several risk factors of high IOP after vitreoretinal surgery have been mentioned in different clinical studies separately [1,4,5]. This study systemically analyzed the incidence and risk factors of elevated IOP in the early stage (day 1, 2, 3, 4-7) after vitreoretinal surgery (Tables 3-5).

We found that most patients experienced high IOP at day 1 (57.40%) and day 2 (25.93%) postoperatively. In Han's prospective study, around 60% of patients had an acute IOP rise within 2 days of PPV [10]. Possible mechanisms of IOP elevation included inflammation response, pupillary block, ciliary body edema and hemorrhagic complications [10,11]. Prolonged IOP elevation Long-standing increased IOP may occur if patients did not receive appropriate early intervention at this stage.

Several risk factors have been related with high IOP after vitreoretinal surgery, such as the primary diseases of the patients, the application of tamponade, and the procedure of the surgery [1,4,5]. We found that the incidences of elevated IOP between different primary diseases had no statistical difference. However, patients with PDR and RRD with proliferative vitreoretinopathy (PVR) grade  $\geq$  C2, had higher rates of IOP elevation. Actually, Muether's group reported that patients with PDR traction RD and primary RRD were at high risk for long-standing increased IOP [1].

Emulsification of the silicone oil and gas filling may also lead to early IOP rise [5,12,13]. We found that the incidence of IOP elevation with intraocular tamponade of C3F8 was significantly higher than simple vitrectomy, while with silicone oil, the difference was not significant. Therefore, silicone oil injection did not increase the rate of postoperative IOP elevation in the absence of emulsification. While the use of expanding gas tamponade may lead to increased IOP through iridocorneal apposition or pupillary block.

Hasegawa's group showed that combined cataract surgery was a risk factor for IOP elevation [4]. However, another study reported that phacoemulsification could easily adjust and control IOP to reduce complications during and after the vitreoretinal surgery [14]. We found that combined cataract surgery in vitrectomy did not affect the incidence of early postoperative IOP elevation. Considering cataract surgery may be more challenging after vitrectomy, removing the lens with or without intraocular lens implantation can be performed if it is needed during surgery.

Placement of a scleral buckle intraoperatively was mentioned as a risk factor in early postoperative IOP elevation of vitreoretinal surgery [10]. However, our data showed that scleral buckling in vitrectomy did not affect the incidence of high IOP. The different results may be explained by the variety of the primary diseases of the patients and the experiences of the vitreoretinal surgeon. We also compare the incidences of early high IOP after 20G and 23G PPV. Results suggested that 20G PPV increased the rate of early postoperative IOP elevation.

In Zhang's study, IOP was statistically significantly lower in the early stages after 23G PPV because of choroidal detachment [15]. However, we did not detect this complication in the follow-up of our patients. Again, the inconsistency of the results implicated the complex impact factors in early postoperative IOP elevation of vitreoretinal surgery.

In conclusion, early IOP elevation is a common complication after vitreoretinal surgery. IOP measurement after vitreoretinal surgery is important to monitor and prevent unintentional high IOP. The risk factors of early IOP elevation include the 20G pars-plana vitrectomy and C3F8 injection. Early treatment of IOP may prevent IOP spike to protect the vision.

## References

1. Muether PS, Hoerster R, Kirchhof B, Fauser S (2011) Course of intraocular pressure after vitreoretinal surgery: is early postoperative intraocular pressure elevation predictable? *Retina* 31: 1545-1552.
2. Desai UR, Alhalel AA, Schiffman RM, Campen TJ, Sundar G, et al. (1997) Intraocular pressure elevation after simple pars plana vitrectomy. *Ophthalmology* 104: 781-786.
3. Anderson NG, Fineman MS, Brown GC (2006) Incidence of intraocular pressure spike and other adverse events after vitreoretinal surgery. *Ophthalmology* 113: 42-47.
4. Hasegawa Y, Okamoto F, Sugiura Y, Okamoto Y, Hiraoka T, et al. (2014) Intraocular pressure elevation after vitrectomy for various vitreoretinal disorders. *Eur J Ophthalmol* 24: 235-241.
5. Matic S, Suić SP, Biuk D, Matic M, Barac J, et al. (2013) Influence of silicone oil tamponade after vitrectomy on intraocular pressure. *Coll Antropol* 37 Suppl 1: 227-235.
6. Grewal DS, Stinnett SS, Folgar FA, Schneider EW, Vajzovic L, et al. (2016) A Comparative Study of Rebound Tonometry With Tonopen and Goldmann Applanation Tonometry Following Vitreoretinal Surgery. *Am J Ophthalmol* 161: 22-28.
7. Wu L, Berrocal MH, Rodriguez FJ, Maia M, Morales-Canton V, et al. (2014) Intraocular pressure elevation after uncomplicated pars plana vitrectomy: results of the Pan American Collaborative Retina Study Group. *Retina* 34: 1985-1989.
8. National Collaborating Centre for Acute Care (2009) *Glaucoma-Diagnosis and Management of Chronic Open Angle Glaucoma and Ocular Hypertension*. London: National Collaborating Centre for Acute Care at The Royal College of Surgeons of England 55: 61.
9. Kornmann HL, Gedde SJ (2016) Glaucoma management after vitreoretinal surgeries. *Curr Opin Ophthalmol* 27: 125-131.
10. Han DP, Lewis H, Lambrou FH Jr, Mieler WF, Hartz A (1989) Mechanisms of intraocular pressure elevation after pars plana vitrectomy. *Ophthalmology* 96: 1357-1362.
11. Stinson WG, Small KW (1994) Glaucoma after surgery on the retina and vitreous. *Semin Ophthalmol* 9: 258-265.
12. Chen PP, Thompson JT (1997) Risk factors for elevated intraocular pressure after the use of intraocular gases in vitreoretinal surgery. *Ophthalmic Surg Lasers* 28: 37-42.
13. Mittra RA, Pollack JS, Dev S, Han DP, Mieler WF, et al. (2000) The use of topical aqueous suppressants in the prevention of postoperative intraocular pressure elevation after pars plana vitrectomy with long-acting gas tamponade. *Ophthalmol* 107: 588-592.
14. Zhou QH, Li Y (2008) Cataract phacoemulsification after vitreoretinal surgery. *Zhong Nan Da Xue Xue Bao Yi Xue Ban* 33: 1053-1055.
15. Zhang J, Li Y, Zhao X, Yu X, Lu L (2015) Comparison of Clinical Features After 20-Gauge Vitrectomy Versus 23-Gauge Vitrectomy. *Asia Pac J Ophthalmol* 4: 367-370.