

Diagnosis of Deeply Infiltrative Endometriosis: Accuracy of a Specific Magnetic Resonance Imaging Protocol

Ito T¹, Opoku-Anane J², Moawad G², Vargas MV², Marfori C², Taffel M³ and Robinson J⁴

¹Department of Obstetrics and Gynaecology, The George Washington University Hospital, Washington, D. C., USA

²Department of Minimally Invasive Gynaecologic Surgery, The George Washington University Hospital, Washington, D. C., USA

³Department of Radiology, The George Washington University Hospital, Washington, D. C., USA

⁴Department of Minimally Invasive Gynaecologic Surgery, George Washington University Hospital, Washington, D. C., USA

*Corresponding author: Ito T, Department of Obstetrics and Gynaecology, The George Washington University Hospital, Washington, D. C., USA, Tel: 2173771412; E-mail: traciemiito@gmail.com

Received date: September 19, 2016; Accepted date: September 25, 2016; Published date: October 12, 2016

Copyright: © 2016 Ito T, et al. This is an open-access article distributed under the terms of the Creative Commons Attribution License, which permits unrestricted use, distribution, and reproduction in any medium, provided the original author and source are credited.

Abstract

Objective: To evaluate the accuracy of a specific magnetic resonance imaging (MRI) protocol in diagnosing the extent and location of deeply infiltrative endometriosis (DIE).

Methods: A retrospective chart review of women age 20 to 51 years of age who had a preoperative evaluation suspicious for DIE based on: 1) preoperative examination showing a rectovaginal mass or nodularity, non-mobile uterus fixed to rectum, and/or an adnexal mass, 2) severe or cyclic dysuria, dyschezia, and/or dyspareunia, or 3) a history of prior surgery for advanced staged endometriosis. These women subsequently underwent an institution specific endometriosis protocol pelvic MRI. Our MRI endometriosis protocol uses a 1.5T machine which takes images in T2, T1 non-fat saturation, and a fat saturation T1 in axial orientation along all three planes pre and post-contrast. Slices are thinner in the T1 and T2 images using the endometriosis protocol compared to the standard protocol. Intra-operative data were collected for women who underwent surgery for endometriosis. MRI findings were compared with intraoperative findings. Twenty-six women who had high suspicion for DIE on our institution specific MRI and subsequently underwent a laparoscopic surgery by a single minimally invasive gynaecologic surgeon were included in our study.

Results: Of the twenty-six women, who met criteria for our study, twenty-one were found to have DIE, two were found to have superficial endometriosis, and there was one case of a tubo-ovarian abscess. Two were found to have other pelvic pathology such as fibroids, cysts, adhesions, and/or fibrosis. For patients with a high preoperative suspicion of DIE, our MRI protocol had a sensitivity of 82%, specificity of 80%, PPV of 95%, NPV of 50%.

Conclusions: Our standardized endometriosis MRI protocol predicts the extent of DIE. Benefits of MRI include potential to replace multiple imaging exams, improve preoperative planning, and aid in decision for referral to a specialized surgeon.

Keywords: Endometriosis; Diagnosis; Dyspareunia

Introduction

Endometriosis is a common benign gynaecologic disorder defined as endometrial glands and stroma in structures outside the uterus. While it is benign, endometriosis can cause significant morbidity including chronic pelvic pain, dysmenorrhea, dyspareunia, dyschezia, and infertility. As a result, debilitating symptoms may impact daily quality of life. The quoted incidence of endometriosis varies as women may be asymptomatic and/or imaging modalities may not reveal all cases. The gold standard for diagnosis is laparoscopy with or without confirmation with biopsy. Overall, the prevalence of endometriosis is reported as 10% in women of childbearing age, 20-50% of women with infertility, and as high as 40-50% in women with chronic pelvic pain [1,2]. Based on surgical diagnosis the incidence of endometriosis is approximately 1.6 out of 1,000 cases [2].

Deeply Infiltrative Endometriosis (DIE) is even more detrimental. It is defined as endometriotic tissue extending into the retroperitoneal space of the wall of pelvic organs greater than a depth of at least 5 mm, and may be present in around 15-30% of women who have endometriosis [2]. Increased severity of symptoms are likely due to infiltration of the peritoneum, Pouch of Douglas, uterosacral ligaments (USLs), vagina, colon, ureters, and vesicouterine pouch. Evaluation of DIE pathology reveals fibromuscular hyperplasia often in the form of nodular lesions with active glands [3].

Many women seek definitive treatment for their endometriosis in the form of surgery when medical management has failed. When surgery is deemed appropriate, imaging may aid in pre-operative planning which could steer a surgeon towards the most appropriate mode of surgery particularly for DIE [4,5]. The accuracy of MRI in its evaluation of extent of lesions in patients with disease is investigated in studies. In a prospective study done by Hottat et al. sensitivity, specificity, positive, and negative predictive values of MR imaging predicting intra-operative disease were 96.3%, 100%, 100%, and 93.3%

respectively [1]. If the location and extent of the disease is better characterized preoperatively, a surgeon may decide to perform a laparoscopy or robotic surgery rather than more extensive abdominal surgery or vice versa. Additionally, a surgeon less skilled to perform an advanced endometriosis surgery or one that suspects significant involvement of the bowel or bladder, may recruit other specialized surgeons to help complete the surgery safely.

In our study, we performed retrospective review to determine the accuracy of the endometriosis MRI protocol at The George Washington University Hospital (GWU) in identifying and localizing deeply infiltrating endometriosis by comparing intraoperative results to MRI findings.

Materials and Methods

Institutional review board approval for this study was obtained. Reproductive age women were assessed preoperatively by one of the minimally invasive gynaecologists of the Medical Faculty Associates at GWU, had an MRI, and subsequently underwent surgery were included in this study. Patients referred for MRI were those that had a high pre-test probability of DIE based on a 1) preoperative examination showing a rectovaginal mass or nodularity, non-mobile uterus fixed to rectum, and/or an adnexal mass, 2) severe or cyclic dysuria, dyschezia, or dyspareunia, and/or 3) a history of prior surgery for advanced staged endometriosis. If endometriosis is suspected, the specific protocol using the hospital's 1.5 T MRI is done in thinner sections to increase chances of identifying smaller lesions of

endometriosis. This differs from our standard pelvic MRI protocol which takes images in thicker sections and with larger skips between slices of imaging. A comparison in the protocols is shown below (Table 1).

	Endometriosis Protocol	Standard Protocol
MRI model	1.5 T	1.5 T
T1 fat saturation	5 mm skip 1 mm	8 mm skip 2 mm
T1 nonfat saturation	6 mm no skip	8 mm skip 2 mm
T2	5 mm skip 1 mm	8 mm skip 2 mm

Table 1: A comparison of endometriosis vs. fibroid protocols.

In the Endometriosis protocol, the T1 fat saturation is done in 5 mm sections with 1 mm skip sections, the T1 non-fat saturation is done in 6 mm sections with no skip sections, and the T2 is done with 5 mm sections with 1 mm skip. In contrast, these same images using the standard pelvic MRI protocol are done in 8 mm sections with 2 mm skip. The images taken are along all three planes of the uterus (axial, sagittal, coronal) pre and post contrast.

Data was analysed for women who subsequently underwent surgery for DIE within one year of original imaging from 2011 to 2014 at George Washington University and Sibley Memorial Hospitals. A flowchart for study selection is displayed in Figure 1.

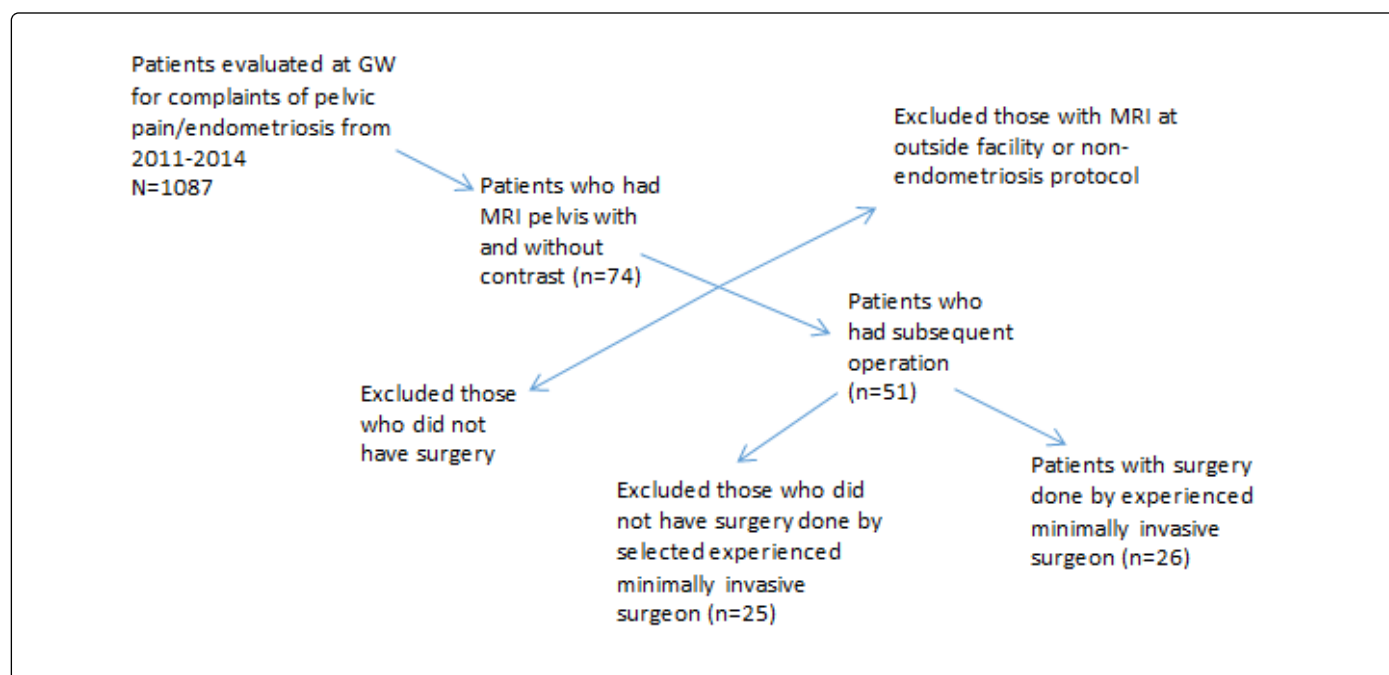


Figure 1: Flowchart for study selection.

Data abstracted included age, parity, race, body mass index, presenting symptoms, date of last menstrual period, presence or absence of menstrual irregularity or heavy menstrual bleeding, history of prior surgery or known adhesive disease, preoperative exam findings, findings on MRI, intraoperative findings, location and size of endometrial lesions based on MRI and intraoperative findings, estimated blood loss, operative time, intraoperative and postoperative complications, length of hospital stay, and pathology results.

The charts were reviewed retrospectively by minimally invasive gynaecology fellows and gynaecology residents to determine how accurately the MRI predicted intraoperative findings of DIE. We classified lesions based on location of hyper intensity on MRI including T1 and T2 images, size, and presence and extent of invasion into surrounding organs.

Results

Our study looked at women referred for pelvic MRI with high pre-test probability of deeply infiltrating endometriosis based on clinical symptoms, exam, and history of endometriosis as stated above. The average age of participants was 35 years. In terms of preoperative presenting symptoms 53.8% reported dysmenorrhea, 80.7% reported generalized pelvic pain, 23.0% reports dyspareunia, 38.5% complained of recurrence of symptoms, 26.9% complaining of primary or secondary infertility, 30.7% dyschezia, keeping in mind that some women fulfilled more than one of these categories. 26.0% complained of other findings like heavy bleeding, constipation, and mass-like sensation in vagina. We also evaluated what treatments were tried prior to surgery in these women (Table 2).

Treatment	Women (%)
NSAIDS	38.4
Lupron	3.8
IUD	3.8
Narcotics	23.0
None	7.6

Table 2: Treatments attempted prior to surgery.

Of note, the two women that did not attempt any therapy prior to surgery were women that were actively trying to conceive.

Twenty-six patients were identified who met our inclusion criteria and who had subsequent surgery by one minimally invasive surgeon. In pre-operative physical exam 50% of patients had generalized pelvic tenderness, 38% had rectovaginal nodule/mass, 12% had a nonmobile uterus/fixed mass, 12% had adnexal tenderness with or without adnexal mass, and 8% had tenderness along the levator muscle. Again, like the presenting symptoms, some women had more than one positive physical exam finding. Only one of the twenty-six patients was noted to have an anterior fibroid on physical exam which elicited no pain on exam.

Of the twenty-six patients in the study, twenty-one participants were found to have DIE and two were found to have superficial endometriosis. One patient had a tubo-ovarian abscess and two were found to have other pelvic pathology such as fibroids, cysts or dense adhesions. The two cases of superficial endometriosis found intra-operatively were correctly identified by MRI in our study. We found that for patients with a high preoperative suspicion of DIE, our MRI protocol showed an overall sensitivity of 82%, specificity of 80%, positive predictive value (PPV) of 95%, and a negative predictive value (NPV) of 50%. In a prospective study done by Hottat et al. sensitivity, specificity, positive, and negative predictive values of MR imaging predicting intra-operative disease were 96.3%, 100%, 100%, and 93.3% respectively [6]. However, in this study a higher resolution MRI (3.0 T vs. 1.5 T) was used possibly explaining the disparity in percentages. Given the difference in enhancement of these two MRIs the lower sensitivity and specificity in our study may be attributed to poorer enhancement of images even with the thinner slices. As a result, there may be a false positive identification of endometriosis in areas of inflammation, fibrosis, or brewing infection where there is truly no disease.

Another prospective study Bazot et al. in 2004 using a similar 1.5 T MRI reported a sensitivity, specificity, positive predictive, and negative predictive of 90.3%, 91%, 92.1%, and 89% respectively for the diagnosis of DIE using a 1.5 T MRI. This study also noted a dysmenorrhea rate of 86.7%.

To help assess why our results were not similar to other studies the images for false negative and false positive results were reviewed with the radiologist. The false positive was a patient who had a tubo-ovarian abscess (TOA) intra-operatively. MRI imaging in this false positive had some tethering and adhesions and hyper intense changes suggestive of DIE. The radiologist hypothesized that the TOA was likely developing causing these changes on imaging, but not developed enough to define a distinct TOA on MRI. Therefore, during surgery only the TOA was observed and no evidence of endometriosis was present.

False negatives were also evaluated. Three of the cases involved fibroids and the distortion from the mass effect from a single dominant fibroid or the multiple fibroids led to areas that mimicked endometriosis. The last false negative case was noted to be done earlier in the development of the endometriosis. As a result, the MRI technicians were getting used to the technique and the radiologists were also getting used to reading the image. The same radiologist who dictated the original report reviewed the images again and described some areas he may consider diagnosing as endometriosis.

Discussion

Our study showed comparable results in terms of sensitivity to prospective studies of MRI detecting endometriosis. However, our low specificity was not comparable. Reviewing false negative and false positive results with the radiologists gave more insight to the possible shortcomings of our MRI protocol in certain scenarios such as fibroids, inflammatory processes, adhesions, etc. The main objective of our study was to assess the accuracy of MRI in diagnosing DIE that was subsequently found intra-operatively and to assess its utility in pre-operative evaluation and planning. At our institution the MRI results proved to aid the minimally invasive surgeon not only in the mode of surgery, but also in multi-disciplinary surgeries that required involvement by general, colorectal, or urology services.

Despite our low specificity our study is a good starting point for future prospective studies involving a standardized checklist for when generalists should refer to specialists and for what situations ordering an MRI is appropriate. In past studies the authors found a close relationship between specific symptoms and various locations of deep endometriosis [6-8]. A larger prospective study could further explore identifying pre-operative data that predicts for better MRI localization of DIE.

Limitations

Small sample size and cases of DIE. The retrospective nature of the study may also introduce bias as some of the preoperative data is not standardly recorded for all participants. Additionally, another limitation of our study includes a lack of measurement of depth of invasion and size of the lesions on all MRIs. Some MRIs were read by different radiologists, although all using the same protocol and may introduce some variability. Presumably this variability would be equally distributed between those with and without DIE and not affect our results. However, the use of multiple radiologists may make these results apply to the general population where multiple radiologists are reading imaging studies for a specific gynaecology practice.

By selecting patients with a high-pre-test probability of DIE, MRI will only be ordered for patients with high suspicion. This could potentially save patients with impressive physical exam and high probability of endometriosis from undergoing multiple exams such as transvaginal US, trans-rectal US, barium enema, cystoscopy, and rectoscopy [1]. It is also important to note that sonographic techniques are limited to a specific anatomical area within the pelvic cavity and sub peritoneal space [3,9]. As a result, no single sonographic study is single-handedly capable to evaluate overall pelvic extension [10].

Standardizing referral criteria for MRI evaluation and standardizing a systematic approach to reading the MRI is needed and may foster the most accurate diagnosis of DIE for pre-operative planning. More prospective research is need to identify which patients are likely to have a high pre-test probability for DIE and would benefit more from comprehensive preoperative imaging including MRI.

References

1. Hottat N, Larrousse C, Anaf V (2009) Endometriosis: contribution of 3.0-T pelvic MR imaging in preoperative assessment--initial results. *Radiology* 253: 126-134.
2. Hoffman B, Schorge J, Schaffer J (2012) *Williams Gynecology*: McGraw-Hill Companies.
3. Bazot M, Darai E, Hourani R (2004) Deep pelvic endometriosis: MR imaging for diagnosis and prediction of extension of disease. *Radiology* 232: 379-389.
4. Kinkel K, Frei KA, Balleyguier C, Chapron C (2006) Diagnosis of endometriosis with imaging: a review. *European radiology* 16: 285-298.
5. Schrage S, Falleroni J, Edgoose J (2013) Evaluation and treatment of endometriosis. *American family physician* 87: 107-113.
6. Bis KG, Vrachliotis TG, Agrawal R, Shetty AN, Maximovich A, et al. (1997) Pelvic endometriosis: MR imaging spectrum with laparoscopic correlation and diagnostic pitfalls. *Radiographics: a review publication of the Radiological Society of North America* 17: 639-655.
7. Frate DC, Girometti R, Pittino M, Frate GD, Bazzocchi M, et al. (2006) Deep retroperitoneal pelvic endometriosis: MR imaging appearance with laparoscopic correlation. *Radiographics: a review publication of the Radiological Society of North America* 26: 1705-1718.
8. Roy C, Balzan C, Thoma V, Sauer B, Wattiez A, et al. (2009) Efficiency of MR imaging to orientate surgical treatment of posterior deep pelvic endometriosis. *Abdominal imaging* 34: 251-259.
9. Vimercati A, Achilarré MT, Scardapane A (2012) Accuracy of transvaginal sonography and contrast-enhanced magnetic resonance-colonography for the presurgical staging of deep infiltrating endometriosis. *Ultrasound in obstetrics & gynecology: the official journal of the International Society of Ultrasound in Obstetrics and Gynecology* 40: 592-603.
10. Giusti S, Forasassi F, Bastiani L (2012) Anatomical localization of deep infiltrating endometriosis: 3D MRI reconstructions. *Abdominal imaging* 37: 1110-1121.