

## CXR of Pneumomediastinum and Subcutaneous Emphysema Following Cocaine 'Snorting'

Stephen Asha\*

Director of Emergency Medicine Research, St George Hospital, Australia

\*Corresponding author: Stephen Asha, Director of Emergency Medicine Research, Emergency Department, St George Hospital, Gray St, Kogarah, NSW, 2217, Australia, Tel: 02 9113 1501; Fax: 02 9113 3946; E-mail: Stephen.Asha@sesiahs.health.nsw.gov.au

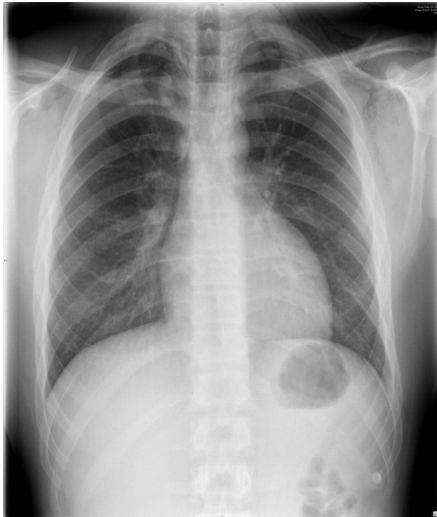
Received date: November 03, 2014, Accepted date: November 05, 2014, Published date: November 12, 2014

Copyright: © 2015 Asha S, et al. This is an open-access article distributed under the terms of the Creative Commons Attribution License, which permits unrestricted use, distribution, and reproduction in any medium, provided the original author and source are credited.

### History

19yr gentleman presents with throat and chest pain at a friend's party, the night before had snorted cocaine ~0200 noticed pain in throat and pain with swallowing over the next few hours.

He developed pain across his anterior chest wall – pleuretic – constant during the next day noticed -voice change; sounds deeper - neck feels swollen and gets a 'crackling noise' when he touches it or swallows subcutaneous emphysema present in neck bilaterally, extending to apex of neck (Figure 1).



**Figure 1:** CXR of pneumomediastinum and subcutaneous emphysema