

Compound Heterozygous *VSX2* Mutation Causing Bilateral Anophthalmia in a Consanguineous Egyptian Family

Cecilia Jakobsson^{1,2#}, Mohamed A Youssef^{3#}, Iman Marzouk³, Nihal ElShakankiri⁴, Nader Bayoumi⁴, Francis L. Munier^{1,2}, Daniel F Schorderet^{1,2,5} and Hana Abouzeid^{1,2*}

¹IRO-Institute for Research in Ophthalmology, Sion, Switzerland

²Jules-Gonin Eye Hospital, Fondation Asile des Aveugles, Department of ophthalmology, University of Lausanne, Lausanne, Switzerland

³Genetics Unit, Department of Pediatrics, University of Alexandria, Alexandria, Egypt

⁴Department of Ophthalmology, University of Alexandria, Alexandria, Egypt; ⁵Faculty of Life Sciences, EPFL-Ecole polytechnique fédérale de Lausanne, Lausanne, Switzerland

#These authors contributed equally to this paper

*Corresponding author: Hana Abouzeid, IRO - Institute for Research in Ophthalmology, Av du Grand-Champsec 64, 1950 Sion, Switzerland, Tel: +4127 205 79 00; Fax: +4127 205 79 01; E-mail: hana.abouzeid@irovision.ch

Received date: May 04, 2015, Accepted date: Jun 25, 2015, Published date: Jun 29, 2015

Copyright: © 2014 Jakobsson C et al., This is an open-access article distributed under the terms of the Creative Commons Attribution License, which permits unrestricted use, distribution, and reproduction in any medium, provided the original author and source are credited.

Abstract

Purpose: To report the clinical and genetic study of a child with bilateral anophthalmia.

Methods: A 14-year-old Egyptian boy, born from consanguineous parents, underwent a general and a full ophthalmological examination. Mutation screen of the A/M genes with recessive inheritance was done stepwise and DNA was analyzed by Sanger sequencing.

Results: Bilateral anophthalmia, arachnodactyly of the feet and high arched palate were observed on general examination. The parents were first cousins and healthy. Sequencing analysis revealed a novel compound heterozygous mutation in one of the copy of exon 2 of *VSX2* and a possible deletion of at least exon 2 on the other allele.

Conclusions: A compound heterozygous *VSX2* mutation associated with anophthalmia was identified in a patient from an Egyptian consanguineous family. This report brings the number of *VSX2* mutation in anophthalmia/microphthalmia (A/M) to 13. Functional consequences of the reported changes still need to be characterized, as well as the percentage of A/M caused by mutations in the *VSX2* gene. This family also shows that despite consanguinity, heterozygous mutations can also happen and one should not restrict the molecular analysis to homozygous mutations.

Keywords: Anophthalmia; Genetics; Microphthalmia; *VSX2*

Introduction

Anophthalmia (A) is a rare and severe ocular malformation characterized by the absence of one or both eye at birth with absent vision [1]. Unilateral anophthalmia is often associated with microphthalmia (M), which is characterized by a small eye. Together, anophthalmia/microphthalmia (A/M) have a prevalence of 1 per 10,000 cases per birth, microphthalmia being more frequent [1]. In more than 50% of affected patients, limbs, musculoskeletal, or craniofacial anomalies have been reported [2]. Non-syndromic A/M is often associated with other ocular anomalies such as colobomas, cysts, cataracts, microcornea or sclerocornea. To date, the underlying genetic cause is identifiable in approximately 25 to 30% of A/M patients as chromosomal aberrations or monogenic mutations and in up to 80% of severe anophthalmia with colobomas as monogenic mutations [2,3]. Several genes of A/M are related with autosomal-dominant inheritance and include *GDF6*, *BMP4*, *OTX2*, and *SOX2* [4]. Autosomal-recessive inheritance has also been reported and involves *VSX2* [5]. Other genes, *PAX6*, *RAX*, [6] *VAX1*, *FOXE3*, *STRA6*,

SMOC1, [7] *SIX3*, *HESX1*, *BCOR*, *SHH*, *CHD7*, *IKBKG*, *NDP*, *POMT1*, *HMX1*, and *SIX6* and have been related to A/M, both syndromic, and non-syndromic [3]. Mutations in *SOX2*, *OTX2* and *ALDH1A3* are the most common known genetic cause of A/M and account for respectively 4-20%, 3-8% and 10% of cases [2,8]. The remaining genes are thus very rare and the rate of A/M mutations is made difficult to assess.

Visual system homeobox 2 (*VSX2*), originally called *CHX10*, is a gene located on chromosome 14, which contains 5 exons. This gene encodes a homeobox protein described as retinal-specific in human, [9] mice [10] and zebrafish embryos [11-13]. In mice, early *Vsx2* expression has been described in brainstem, thalamus and spinal cord [10]. In human [11], mice [14] and zebrafish, [12] *VSX2/Vsx2* loss of function causes microphthalmia and variable associated ocular anomalies.

So far, twelve *VSX2* mutations have been identified in 21 probands from 14 consanguineous families descending from Arabic countries or neighbouring regions [11,15-20]. Different ocular phenotypes have been described in these 14 families ranging from severe anophthalmia to microphthalmia with or without additional ocular features such as

colobomas, cataracts, or optic nerve hypoplasia for example. Extraocular features have been described in one report so far as developmental delay with behavioural problems, autism, cryptorchidism, ovarian defects, limb anomaly and hearing impairment [18].

In this study, a novel compound heterozygous *VSX2* mutation has been identified in a patient of Egyptian origin affected with bilateral anophthalmia. We further expand the clinical and genetic description of A/M caused by *VSX2* that has very few alleles identified to date related to A/M.

Methods

The ethic board of the University of Alexandria, Egypt, approved this study and informed consent was obtained from the parents of the family. The study was performed in adherence to the tenets of the declaration of Helsinki (1983 Revision).

Clinical examination

A 14-year-old boy from an Egyptian consanguineous family underwent full medical examination. Pregnancy history of the mother, antenatal and postnatal development history of the child and family history were taken. A family pedigree was drawn (Figure 1). Growth, skull, face, chest, heart, abdomen, uro-genital, skeletal system, nervous system and skin were included in the general medical examination. A complete ophthalmic examination with an echography of both orbits was performed. History of parents' health was taken and eye examination performed.

Genetic analysis

The genetic analysis was performed in the 14-year-old boy and his parents. Genomic DNA was extracted from peripheral blood using the

standard procedures. Mutation screen of the A/M genes with recessive inheritance was done stepwise, starting with *ALDH1A3*, *RAX*, and *VSX2*. The five exons and exon-intron junctions of *VSX2* were screened by direct sequencing after PCR amplification.

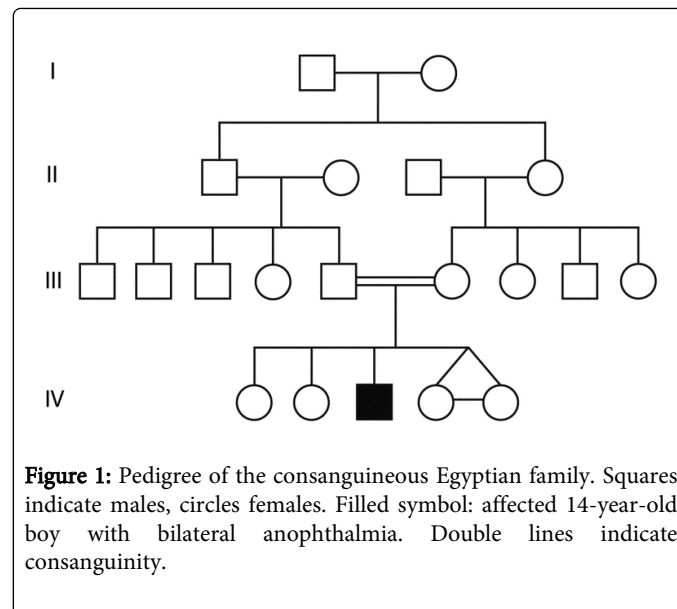


Figure 1: Pedigree of the consanguineous Egyptian family. Squares indicate males, circles females. Filled symbol: affected 14-year-old boy with bilateral anophthalmia. Double lines indicate consanguinity.

PCR products were amplified using 20 ng of genomic DNA in a 20 μ l reaction mixture (10 μ l master-mix, 5 μ l H₂O, 1.5 μ l of forward primer and 1.5 μ l reverse primer). The primers were designed by using Primer3 software (<http://primer3.wi.mit.edu/>) (Table 1). The various amplicons were directly sequenced as previously described [6].

Exon	Primer sequence (5'-3') : forward/reverse
VSX2-1	GTGATTGGCTGCTCAGCTCT/ GGCCTGGCAGGAACCTTT
VSX2-2	CTTCCTGGGGAGACAGAGC/ CGAAAATAGGGTCCGAGAGA
VSX2-3	CCAGGAGACACAGAGGAAGG/ CAAGCACATGCCACAGT
VSX2-4	ACAGAGGGCACCATGGAGTA/ CTCTCCTGCTAGGCTGCTGT
VSX2-5	AAGGCTTTCTGCTCGTCCTT/ TGTCTCAGCATGGTCCAGAG

Table 1: Primers used for PCR amplification and direct sequencing of *VSX2* coding exons and intronic junctions.

Results

Bilateral anophthalmia was diagnosed in the 14 year old boy, associated with narrow palpebral fissure and large upper eyebrows (Figures 2A and 2B). Orbital echography confirmed the diagnosis and excluded orbital cysts remnants. The complete medical examination revealed a high arched palate and arachnodactyly of the toes (Figure 2C). No other malformations were present. The patient was born at term after an uneventful pregnancy. Neuropsychological, motor development and growth parameters were normal. The parents were both healthy, had no ocular anomalies and family history was free.

The pedigree of the family suggested an autosomal recessive inheritance (Figure 1). Sequencing analysis of all *VSX2* exons revealed a potential homozygous mutation in exon 2 of the patient, [c.422delA], that resulted in a theoretical frameshift and the generation of termination codon 19 amino acids downstream (p.N141Ifs*20) (Figure 3A). In fact, based on the analysis of the parents, this mutation was hemizygous in the affected boy.

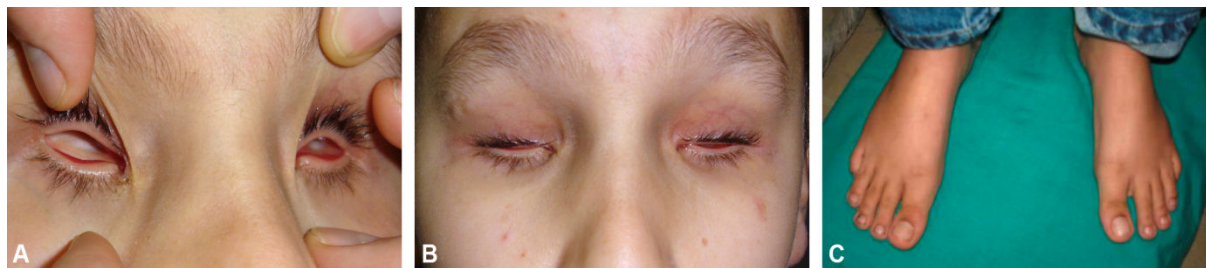

Figure 2: Pictures of the affected child. A: The 14-year-old boy affected with bilateral anophthalmia. B: Note the absence of eye when the upper palpebral lid is reversed. C: Feet with arachnodactyly.

Indeed, the unaffected father was carrying the [c.422delA] variant in exon 2 (Figure 3C) while his mother was normal (Figure 3B), suggesting the presence of a deletion that included at least exon 2. No mutations were detected in the patient's siblings. The *VSX2* c.422delA mutation was not detected in 96 controls from North Africa nor in 96 Swiss controls. Mutation screen of all other A/M genes did not reveal any other anomaly or mutation.

additional conserved region, called the CVC domain [13]. *VSX2* is one of the earliest specific markers of the neuroretinal lineage and is expressed in neuroretinal pluripotent cells and late-born bipolar cells [21]. It is strongly conserved in vertebrates and zebrafish [1,2]. Passini et al. [13] worked on zebrafish eye development to analyse the possible role of *Vsx2*. It is variously expressed at different embryonic stages with an enhanced and restrictive function that, finally, leads to a normal developed eye. Recently, Phillips et al. [21] revealed the multiple roles of *VSX2* that included proliferation, cell fate and differentiation. Therefore, it is not surprising that mutations in *VSX2* lead to malformations due to embryonic perturbation of the ocular program [22]. Systemic malformations are not explained by ocular expression analyses.

Only twelve mutations in *VSX2* have been identified in autosomal recessive A/M, so far (Table 2). When screening large series, *VSX2* mutations seem to account for a small proportion of A/M reaching a maximum of 2% [11]. Six of the reported mutations are thought to cause loss of function and three other interestingly affect the *VSX2* CVC domain with a « hotspot » at Arg200 [11,17,18]. From a clinical point of view, all the described patients with identified *VSX2* mutations had A/M associated with colobomas. Several cases had in addition cataracts or other ocular anomalies (Table 2). Of the latter, only one patient, of Afghan origin, was described with globe remnants on MRI and a homozygous nonsense p.Arg200* mutation (Table 2) [10]. This girl had several non-ocular anomalies, including microcephaly, moderate learning difficulties, and underdeveloped optic nerves and chiasm [10]. All but one report of *VSX2* mutations were associated with only ocular phenotypes, the exception was made by Iseri et al. [18] (Table 2) who described extraocular features in different A/M patients, including the Afghan girl described above. No definite causative relationship between the non-ocular features and the *VSX2* mutation has been demonstrated.

In the present study, we identified new compound heterozygous *VSX2* mutations causing severe bilateral anophthalmia. To our knowledge, this deletion in the *VSX2* gene [c.422delA; p.N141Ifs*19] localized in exon 2 has never been described before. Both mutations may generate loss of function, either by nonsense-mediated decay or by shorter *VSX2* proteins.

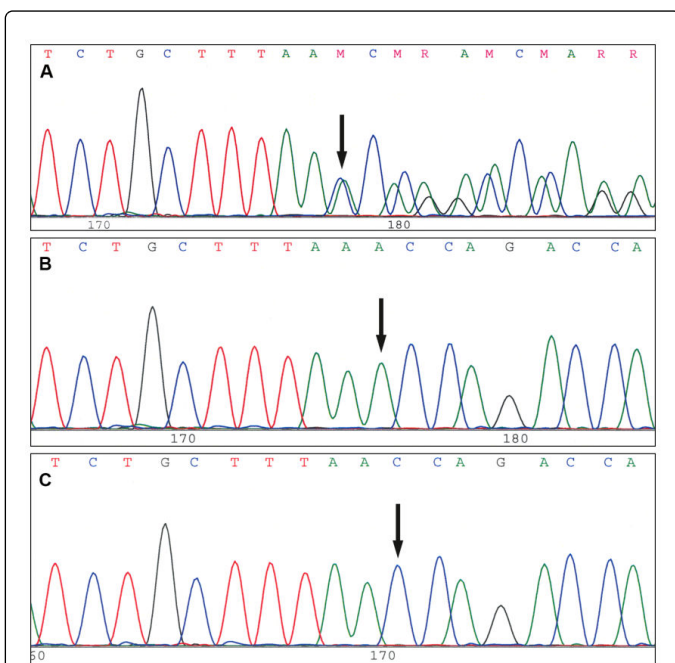


Figure 3: Partial electropherogram of *VSX2* exon 2. Partial Sanger sequencing of *VSX2* exon 2. **A:** the patient shows a hemizygous deletion of nucleotide A at position 422. **B:** The mother has a wild-type sequence. As the mother does not show a heterozygous sequence, she must have a deletion of at least exon 2 of *VSX2*. **C:** The father is heterozygous for the deletion.

Discussion

VSX2 is a homeobox gene and a member of the paired-like CVC gene family which are consisted of a pair homeodomain and an

N°	Location	DNA mutation	Protein mutation	Mutation Type	Genotype	Affected individuals	Ocular Phenotype	Non ocular phenotype	Ethnic origin	Inheritance	Reference
1	Exon 1	c.249delG	p.Leu84SerfsX57	Deletion and frameshift	Homozygous	7 (from 2 families)	Bilateral microphthalmia and coloboma (Bilateral microphthalmia and "disorganized eye" Reis et al)	Oestrogen and insulin deficiency, leg length discrepancy	Iran	Recessive	[5,18],
2	Intron 1	c.371-1G>A	Aberrant splicing	Splice site	Homozygous	2	A/M and iris coloboma	None	Jewish-Syrian	Recessive	[16]
3	Exon 2	c.422delA c.371-?_455+?del	p.N141Ifs*19, Deletion exon 2	Deletion and frameshift	Compound heterozygous	1	Bilateral anophthalmia	None	Egypt	Recessive	Present report
4	Intron 2	c.456-2A>G	Aberrant splicing	Splice site	Homozygous	1	Severe bilateral microphthalmia, iris colobomas, retinal detachments, hypoplastic optic nerves	None	Turkey	Recessive	[19]
5	Exon 3	Exon deletion	~4kb del around exon 3	Exon deletion	Homozygous	16	A/M	None	Arab (Bedouin)	Recessive	[16]
6	Exon 4	c.598C>T	p.Arg200X		Homozygous	1	Bilateral anophthalmia, hypoplastic optic nerves and chiasm	Moderate communication and learning difficulties, small head circumference	Afghanistan	Recessive	[18]
7	Exon 4	c.599G>A	p.Arg200Gln	Missense	Homozygous	2	Bilateral microphthalmia, iris coloboma, dislocated lens, and cataract	None	Turkey	Recessive	[11]
8	Exon 4	c.599G>C	p.Arg200Pro	Missense	Homozygous	1	Bilateral microphthalmia, anterior segment dysgenesis, lens dislocation, retinal detachment	None	United Arab Emirates	Recessive	[11]
9	Exon 4	c.599G>C	p.Arg200Pro	Missense	Homozygous	6 (from 2 families)	Bilateral severe microphthalmia and cloudy corneas	None	Qatar	Recessive	[11]
10	Exon 4	c.71_72insG, c.667G>A	p.Ala25Argfs*101, p.Gly223Arg (Compound heterozygous)	Frameshift	Compound heterozygous	1	Severe bilateral colobomatous microphthalmia, and cataract	None	Unspecified		[20]
11	Exon 4	c.679C>T	p.Arg227Trp	Missense	Homozygous	2	Isolated A/M	None	Arab (Bedouin)	Recessive	[16]

11	Exon 4	c.679C>T	p.Arg227Trp	Missense	Homozygous	1	Extreme bilateral microphthalmia	Hearing impairment, severe learning difficulties, autism	Pakistan	Recessive	[18]
12	Exon 4	c.668G>C	p.G223A	Missense	Homozygous	7	Bilateral microphthalmia	None	Pakistan	Recessive	[5]

Table 2: *VSX2* mutations causing recessive anophthalmia/microphthalmia.

The 14-year-old boy we studied did not harbour any globe remnants on orbital echography, no such case has been described to date so that it represents the most severe ocular phenotype described in association with a *VSX2* mutation. Narrow palpebral fissure and large upper eyebrows (Figures 2A, B) have been seen in several Egyptian A/M patients before and may likely be related to the lack of globes [6]. In addition we observed clinically an arachnodactyly of the toes (Figure 2C) that is very pronounced in this patient. Such a phenotype has not been reported before and the only other report of a limb anomaly refers to an Iranian patient with the p.Leu84SerfsX57 mutation, who also showed a left leg length discrepancy of 2 cm and tapering fingers. She later developed mild insulin and iron deficiency, and ovarian problems as well [18]. It is of interest to note that the case we describe as well as the Iranian girl could represent limb anomalies often associated with A/M, despite the fact that the causative effect of the *VSX2* mutation cannot be unequivocally assessed. The present report suggests that *VSX2* mutations may not only affect the ocular area as thought to date, considering the predominant expression of *VSX2* in the neuroretinal lineage, but also other organs [11]. Finally, because different *VSX2* mutations can generate similar phenotypes (Table 2), and different phenotypes can be caused by identical mutations, it is difficult to establish genotype-phenotype correlations. More studies and reports are needed, especially of cases with *VSX2* residual function.

All *VSX2* mutations reported so far, including the present one, are in families of Middle-East origins or neighbouring countries, namely Pakistan and Afghanistan (Table 2). Thus it has been suggested that *VSX2* mutations were more frequent or specific to Middle-East and South Asian background origins [5,16-18]. Nevertheless, when screening this gene in exclusively consanguineous A/M kindred from unspecific ethnic origin, the rate of *VSX2* mutations is higher, and varies from 15% to 33% [5,18]. *VSX2* mutations may be more frequent than expected and are to date related only to recessive A/M as confirmed by the present report. High rate of consanguinity may explain the higher frequency of *VSX2* mutations in Middle-Eastern than in European patients, rather than a shared ancestry. Of note is that despite consanguinity, compound heterozygosity may be present as reported here and by Chassaing et al. [20] and one should not restrict the molecular analysis to homozygous mutations only for *VSX2*.

In conclusion, the present study identified a compound heterozygous mutations including two deletions in *VSX2*, a single nucleotide and a whole exon that have never been described before, in a patient with severe bilateral anophthalmia. This study expands the number of described *VSX2* mutations causing A/M to 12 and describes the most severe case of A/M reported to date, in association with the first report of associated arachnodactyly. Definite causality of *VSX2* for the non-ocular phenotype cannot yet be assessed but

clinicians should be aware of this eventuality. The present study shows that despite consanguinity, compound heterozygosity may be present and one should not restrict the molecular analysis to homozygous mutations only.

References

- Morrison D, FitzPatrick D, Hanson I, Williamson K, van Heyningen V, et al. (2002) National study of microphthalmia, anophthalmia, and coloboma (MAC) in Scotland: investigation of genetic aetiology. *J Med Genet* 39: 16-22.
- Slavotinek AM (2011) Eye development genes and known syndromes. *Mol Genet Metab* 104: 448-456.
- Williamson KA, FitzPatrick DR (2014) The genetic architecture of microphthalmia, anophthalmia and coloboma. *Eur J Med Genet* 57: 369-380.
- Fantes J, Ragge NK, Lynch SA, McGill NI, Collin JR, et al. (2003) Mutations in *SOX2* cause anophthalmia. *Nat Genet* 33: 461-463.
- Reis LM, Khan A, Karimnejad A, Ebadi F, Tyler RC, et al. (2011) *VSX2* mutations in autosomal recessive microphthalmia. *Mol Vis* 17: 2527-2532.
- Abouzeid H, Youssef MA, Bayoumi N, ElShakankiri N, Marzouk I, et al. (2012) RAX and anophthalmia in humans: evidence of brain anomalies. *Mol Vis* 18: 1449-1456.
- Abouzeid H, Boisset G, Favez T, Youssef M, Marzouk I, et al. (2011) Mutations in the SPARC-related modular calcium-binding protein 1 gene, *SMOC1*, cause waardenburg anophthalmia syndrome. *Am J Hum Genet* 88: 92-98.
- Abouzeid H, Favez T, Schmid A, Agosti C, Youssef M, et al. (2014) Mutations in *ALDH1A3* represent a frequent cause of microphthalmia/anophthalmia in consanguineous families. *Hum Mutat* 35: 949-953.
- Dorval KM, Bobecko BP, Ahmad KF, Bremner R (2005) Transcriptional activity of the paired-like homeodomain proteins *CHX10* and *VSX1*. *J Biol Chem* 280: 10100-10108.
- Liu IS, Chen JD, Ploder L, Vidgen D, van der Kooy D, et al. (1994) Developmental expression of a novel murine homeobox gene (*Chx10*): evidence for roles in determination of the neuroretina and inner nuclear layer. *Neuron* 13: 377-393.
- Faiyaz-UI-Haque EF, Ploder LA, Yu JJ, Arici K, Horsford DJ, et al. (2000) Human microphthalmia associated with mutations in the retinal homeobox gene *CHX10*. *Nat Genet* 25: 397-401.
- Barabino SM, Spada F, Cotelli F, Boncinelli E (1997) Inactivation of the zebrafish homologue of *Chx10* by antisense oligonucleotides causes eye malformations similar to the ocular retardation phenotype. *Mech Dev* 63: 133-143.
- Passini MA, Levine EM, Canger AK, Raymond PA, Schechter N (1997) *Vsx-1* and *Vsx-2*: differential expression of two paired-like homeobox genes during zebrafish and goldfish retinogenesis. *J Comp Neurol* 388: 495-505.
- Burmeister M, Novak J, Liang MY, Basu S, Ploder L, et al. (1996) Ocular retardation mouse caused by *Chx10* homeobox null allele: impaired

-
- retinal progenitor proliferation and bipolar cell differentiation. *Nat Genet* 12: 376-384.
15. Reis LM, Tyler RC, Schneider A, Bardakjian T, Stoler JM, et al. (2010) FOXE3 plays a significant role in autosomal recessive microphthalmia. *Am J Med Genet A* 152A: 582-590.
16. Bar-Yosef U, Abuelaish I, Harel T, Hendler N, Ofir R, et al. (2004) CHX10 mutations cause non-syndromic microphthalmia/ anophthalmia in Arab and Jewish kindreds. *Hum Genet* 115: 302-309.
17. Faiyaz-Ul-Haque M, Zaidi SH, Al-Mureikhi MS, Peltekova I, Tsui LC, et al. (2007) Mutations in the CHX10 gene in non-syndromic microphthalmia/anophthalmia patients from Qatar. *Clin Genet* 72: 164-166.
18. Iseri SU, Wyatt AW, Nürnberg G, Kluck C, Nürnberg P, et al. (2010) Use of genome-wide SNP homozygosity mapping in small pedigrees to identify new mutations in VSX2 causing recessive microphthalmia and a semidominant inner retinal dystrophy. *Hum Genet* 128: 51-60.
19. Burkitt Wright EM, Perveen R, Bowers N, Ramsden S, McCann E, et al. (2010) VSX2 in microphthalmia: a novel splice site mutation producing a severe microphthalmia phenotype. *Br J Ophthalmol* 94: 386-388.
20. Chassaing N, Causse A, Vigouroux A, Delahaye A, Alessandri JL, et al. (2014) Molecular findings and clinical data in a cohort of 150 patients with anophthalmia/microphthalmia. *Clin Genet* 86: 326-334.
21. Phillips MJ, Perez ET, Martin JM, Reshel ST, Wallace KA, et al. (2014) Modeling human retinal development with patient-specific induced pluripotent stem cells reveals multiple roles for visual system homeobox 2. *Stem Cells* 32: 1480-1492.
22. Gerth-Kahlert C, Williamson K, Ansari M, Rainger JK, Hingst V, et al. (2013) Clinical and mutation analysis of 51 probands with anophthalmia and/or severe microphthalmia from a single center. *Mol Genet Genomic Med* 1: 15-31.