

Comparing Anterior Segment Ocular Coherence Tomography (AS-OCT), Ultrasound Biomicroscopy (UBM) and Pentacam in Evaluating the Changes of the Anterior Segment Parameters after Phacoemulsification

Ahmed Ghoneim^{1*}, Tamer Wasfy¹, Yasser Serag¹, Hazem Elbedewy¹, Elsayed Nassar¹, Ahmed Elmaria¹ Saed AM² and Tamer Salem²

¹Department of Ophthalmology, Faculty of Medicine, Tanta University, Egypt

²Department of Ophthalmology, Faculty of Medicine, Benha University, Egypt

*Corresponding author: Ahmed Mohamed Ghoneim, Department of Ophthalmology, Faculty of Medicine, Tanta University, Egypt, Tel: +201005454062; E-mail: ghoneimfjmm@yahoo.com

Received date: April 18, 2017; Accepted date: May 03, 2017; Published date: May 08, 2017

Copyright: ©2017 Ghoneim A, et al. This is an open-access article distributed under the terms of the Creative Commons Attribution License, which permits unrestricted use, distribution, and reproduction in any medium, provided the original author and source are credited.

Abstract

Background: Cataract extraction affects some of the anterior chamber (AC) parameters like AC depth (ACD) and the width of the AC angle. Different techniques are used to evaluate these effects before and after cataract extraction.

Purpose: To evaluate the results of Anterior Segment Optical Coherence Tomography (AS-OCT), Ultrasound Biomicroscopy (UBM) & Pentacam in evaluating the changes of the anterior segment parameters after cataract extraction.

Methods: Prospective non-randomized study including 40 cataractous eyes. AS-OCT, UBM and Pentacam were done 1 week before, 1 week and 1 month after phacoemulsification with intraocular lens (IOL) implantation, to measure ACD, AC angle width, and central corneal thickness (CCT).

Results: ACD depth, AC angle width and CCT increased significantly 1 week and 1 month after surgery than the preoperative level ($p < 0.001$), with no significant difference between 1 week and 1 month after surgery ($p > 0.05$). No significant difference between the 3 techniques in most measures either pre- or postoperatively.

Conclusion: ACD, AC angle width and CCT are significantly increased after uneventful phacoemulsification surgery and Foldable IOL implantation, which have become stabilized after 1 month of surgery with no significant difference in the measures given by AS-OCT, UBM or Pentacam.

Keywords: Anterior segment OCT; UBM; Pentacam; Phacoemulsification; AC Angle; Corneal thickness

Introduction

Cataract and various lens disorders are well known to cause changes in the anterior chamber of the eye, especially the angle and affecting the intraocular pressure. One of these effects is the narrowing of the angle which may sometimes proceed to angle closure either in acute, subacute or chronic forms [1,2]. This happens because of the equatorial age-related growth of the lens which makes the suspensory ligament slackens and the lens moves anteriorly [3]. Phacoemulsification for cataract or even lens extraction with IOL implantation in eyes with narrow angle can reduce the intraocular pressure (IOP), open the iridocorneal angles and deepen the anterior chamber [3-10].

In the traditional clinical settings, direct visualization of the iridocorneal angle can be done by some diagnostic contact lenses; such as the Goldmann 3-mirror lens. The evolution of some new investigations for the anterior segment of the eye like anterior segment optical coherence tomography (AS-OCT), ultrasound biomicroscopy and pentacam, makes it possible to objectively evaluate the structures

of anterior segment of the eye, the iridocorneal angle now can be objectively fully investigated and well-assessed [12,13].

AS-OCT acts through using light of long wavelength (1,310 nm) which gives images of high resolution for the anterior segment of the eye in a non-invasive and non-contact way. It is a rapid technique and provides quantitative analysis of different ocular structures. It also has repeatability and reproducibility because of its low intraobserver and interobserver variability [14-17].

The limitation of AS-OCT technique is its limited penetration of the iris due to the presence of pigmented epithelium. This limitation makes the obtaining of accurate images for structures behind this pigmented epithelium (ciliary body, lens and zonules) are difficult [15].

Ultrasound biomicroscopy (UBM) can give images of high-resolution and good quality for anterior segment including iridocorneal angle and ciliary body which are not visible with ordinary gonioscopy [14,16,18]. The major disadvantage of the UBM technique is that the transducer requires immersion of the eye in a water bath of saline with the patient in the supine position. This makes the procedure uncomfortable for the patients and needs a skilled examiner, the Scheimpflug camera (Pentacam), which uses a slit beam and a camera, is a non-invasive technique and can be repeated easily but it

does not allow visualization of the actual angle and its images need to be well processed because of its optical and acoustic nature [18-20].

Purpose

This study aimed to evaluate the results of AS-OCT, UBM & Pentacam in evaluating the changes of the anterior segment parameters after Phacoemulsification with IOL implantation.

Patients and Methods

A prospective non-randomized study included 40 eyes of 40 patients who underwent uneventful phacoemulsification surgery and IOL implantation. This study has been obtained an ethical agreement from the medical ethics committee at faculty of medicine, Tanta University.

All the eyes had preoperative full ophthalmological evaluation. The intraocular pressure (IOP) was assessed by Goldmann applanation tonometer. All measurements were obtained under standard dim light conditions and without dilation.

Preoperative exclusion criteria were any eye with corneal pathology, high myopia >6 diopter (D) or axial length >26 mm, IOP abnormalities, lens abnormalities like pseudo exfoliation, uveitis, previous eye surgery or eye trauma, posterior segment pathology, systemic illness that affect the angle like diabetes, those using topical or systemic medications that might influence anterior segment parameters and IOP measurements. Eyes with intraoperative or postoperative complications that can affect the angle or the IOP were also excluded from the study.

Anterior segment OCT (AS-OCT), Pentacam and UBM imaging were obtained for all the included eyes 1 week before, 1 week and one month after phaco-surgery to evaluate Anterior chamber depth (ACD), nasal and temporal angle changes, and to measure corneal thickness.

OCT Images of the anterior segment were obtained using a (Topcon 3D OCT 2000 Fa plus, Japan) device. All the images were taken in the same dark conditions (0-1 lux by digital light meter with patients in a sitting position. After several scans were acquired, the operator selected the best image with no motion artifacts or image artifacts from the eyelids.

UBM examination was performed with VuMAX™ (Sonomed Escalon, USA) using the company water path probe and 35 MHz transducer. All patients were examined in supine position. After application of topical anesthesia, a plastic eye cup was placed gently on the globe and then filled with balanced saline solution. Sulcus to sulcus axial scan passing through the center of the pupil was obtained for every patient to measure the central corneal thickness and central ACD. After selecting angle scan preset mode of the device software, radial scans through the nasal and temporal AC angles with the probe marker directed away from the limbus were obtained to measure angle opening distance at 500 μm, which is calculated automatically by the device software after manually selected scleral spur position.

The Pentacam system (Oculizer II, wavelight) is based on an 180° rotating Scheimpflug camera which can take 12-50 single images to

reconstruct the anterior chamber. After completing a scan, Pentacam software constructs the 3-dimensional image of the anterior segment and calculates the anterior chamber parameters.

All surgeries were performed by the same experienced surgeon (AG) in the same hospital and with the same settings of the phacomachine (WhiteStar Signature Phacoemulsification System, Abbott Medical Optics) and the same type of foldable IOL (Sensor; Advanced Medical Optics, Inc., Santa Ana, CA, USA).

Statistical analysis of the collected data

Results were collected, tabulated and statistically analyzed by an IBM compatible personal computer with SPSS statistical package version 20 (SPSS Inc. Released 2011. IBM SPSS statistics for windows, version 20.0, Armonk, NY: IBM Corp.) Data was expressed in: Number (No), percentage (%) mean (\bar{x}) and standard deviation (SD). ANOVA test was used for comparison of quantitative variables between more than two groups of normally distributed data with LSD test as post Hoc test while; Kruskal Wallis test was used for comparison of quantitative variables between more than two groups of not normal distributed data with Tamhane's test as post hoc test. Repeated measures ANOVA test was used for comparison of quantitative variables between more than two consecutive measures in the same group of normally distributed data and Friedman test was used for comparison of quantitative variables between more than two consecutive measures in the same group of not- normally distributed data with LSD test as post Hoc test. P-value of <0.05 was considered statistically significant.

Results

40 eyes of 40 patients with uneventful phacoemulsification surgery were the subjects of this study. The mean age of the studied patients were 51.22 ± 5.46 years. 22 (55%) eyes belonged to male patients, while the rest of the eyes belonged to female ones.

The postoperative measures of A.C. depth showed significant increase from the preoperative measure by all the used techniques. However, this increase was stabilized after 1st week from the surgery as there was no significant difference between the A.C depth at 1st week and 1st month after surgery. By using AS-OCT, the mean preoperative AC depth was 2.25 ± 0.9 mm, which was significantly increased to at 3.65 ± 0.89 mm at 1st week and 4.06 ± 1.01 mm at 1st month postoperative (P<0.001). By using UBM, the mean preoperative AC depth was 3.02 ± 0.82 mm, which was significantly increased to at 4.05 ± 0.99 mm at 1st week and 4.41 ± 0.75 mm at 1st month postoperative (P<0.001), and by using the Pentacam, the mean preoperative AC depth was 3.19 ± 0.93 mm, which was significantly increased to at 4.09 ± 0.84 mm at 1st week and 4.45 ± 0.88 mm at 1st month postoperative (P<0.001).

When comparing the 3 techniques, there was no significant difference between them regarding AC depth at different time measures except that AS-OCT gives lower preoperative AC depth (2.25 ± 0.9) than both the UBM (3.02 ± 0.82) and pentacam (3.19 ± 0.93) with p<0.001 (Table 1).

Technique	Preop. Mean ± SD	1 st w postop Mean ± SD	1 st postop. Mean ± SD	Repeated measures ANOVA	P value	Post Hoc
AS-OCT	2.25 ± 0.9	3.65 ± 0.89	4.06 ± 1.01	41.21*	<0.001	P1<0.001 P2<0.001 P3<0.06
UBM	3.02 ± 0.82	4.05 ± 0.99	4.41 ± 0.75	28.19	<0.001	P1<0.001 P2<0.001 P3<0.07
Pentacam	3.19 ± 0.93	4.09 ± 0.84	4.45 ± 0.88	21.55	<0.001	P1<0.001 P2<0.001 P3<0.06
F test	10.30**	2.86	2.34	----	-----	-----
P value	<0.001	0.06	0.10	-----	-----	-----
Post Hoc	P4<0.001 P5<0.001 P6>0.05	-----	----			

*Freidman test ** Kruskal wallis test

Table 1: Comparison between the mean A.C. depth (mm) values preoperatively, 1st week and 1st month postoperatively.

P1 for comparison between preop. and 1st week postop., P2 for comparison between preop., and 1st month postop., P3 for comparison between 1st week and 1st month postop., P4 for comparison between AS-OCT and UBM, P5 for comparison between AS-OCT and pentacam and P6 for comparison between UBM and pentacam.

All the 3 techniques showed significant widening of the angle at the 1st week after surgery which become stable and did not differ significantly when measured at the 1st month after surgery. AS-OCT showed significant widening of the angle from 28.29 ± 4.21° to 34.20 ±

3.65° at the 1st week and 33.91 ± 4.21° at the 1st postoperative month. By UBM, the angled changed from 27.99 ± 3.89° preoperatively to 34.47 ± 4.02° and 34.13 ± 4.30° at 1st week and 1st month postoperative respectively. Pentacam showed the same results as the angle changed from 28.01 ± 3.76° preoperative to 33.91 ± 3.90° and 33.90 ± 3.87° at 1st week and 1st month postoperative respectively. There was no significant difference between the 3 techniques in angle measurements at each time measure (Table 2).

Investigation	Preop Mean ± SD	1 st w postop Mean ± SD	1 st m postop. Mean ± SD	Repeated measures ANOVA	P value	Post Hoc
AS-OCT	28.29 ± 4.21	34.20 ± 3.65	33.91 ± 4.21	27.30	<0.001	P1<0.001 P2<0.001 P3<0.74
UBM	27.99 ± 3.89	34.47 ± 4.02	34.13 ± 4.30	32.06	<0.001	P1<0.001 P2<0.001 P3<0.71
Pentacam	28.01 ± 3.76	33.91 ± 3.90	33.90 ± 3.87	31.36	<0.001	P1 <0.001 P2<0.001 P3<0.99

F test	0.07	0.21	0.04	----	-----	-----
P value	0.93	0.81	0.96	-----	-----	-----
P1 for comparison between preop. and 1st week postop. , P2 for comparison between preop., and 1st month postop., P3 for comparison between 1st week and 1st month postop.						

Table 2: Comparison between the mean angle width preoperatively, 1st week and 1st month postoperative.

Regarding the central corneal thickness (CCT), it showed the same trend of the A.C depth. The postoperative measures of CCT showed significant increase from the preoperative measure by the 3 used techniques and showed stabilization after the 1st week from the surgery as there was no significant difference between the CCT at 1st week and 1st month after surgery. By using AS-OCT, the mean preoperative CCT was $512.0 \pm 20.18 \mu\text{m}$, which was significantly increased to at $545.03 \pm 27.90 \mu\text{m}$ at 1st week and $540.71 \pm 30.4 \mu\text{m}$ at 1st month postoperative (P value of <0.001). By using UBM, the mean preoperative CCT was $519.7 \pm 18.91 \mu\text{m}$, which was significantly

increased to at $545.12 \pm 28.7 \mu\text{m}$ at 1st week and $539.42 \pm 28.13 \mu\text{m}$ at 1st month postoperative (P value of <0.001), and by using the Pentacam, the mean preoperative CCT was $517.8 \pm 21.71 \mu\text{m}$, which was significantly increased to at $547.84 \pm 26.3 \mu\text{m}$ at 1st week and $538.1 \pm 29.4 \mu\text{m}$ at 1st month postoperative (P<0.001).

Again, when comparing the 3 techniques, there was no significant difference between them regarding CCT at different time measures (p value>0.05) (Table 3 and Figures 1-6).

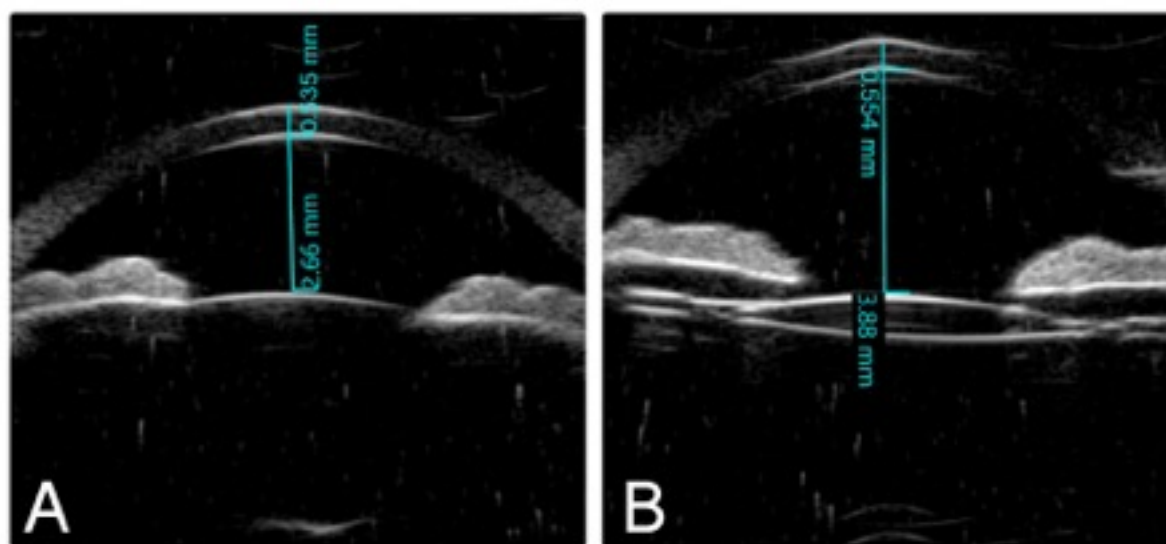


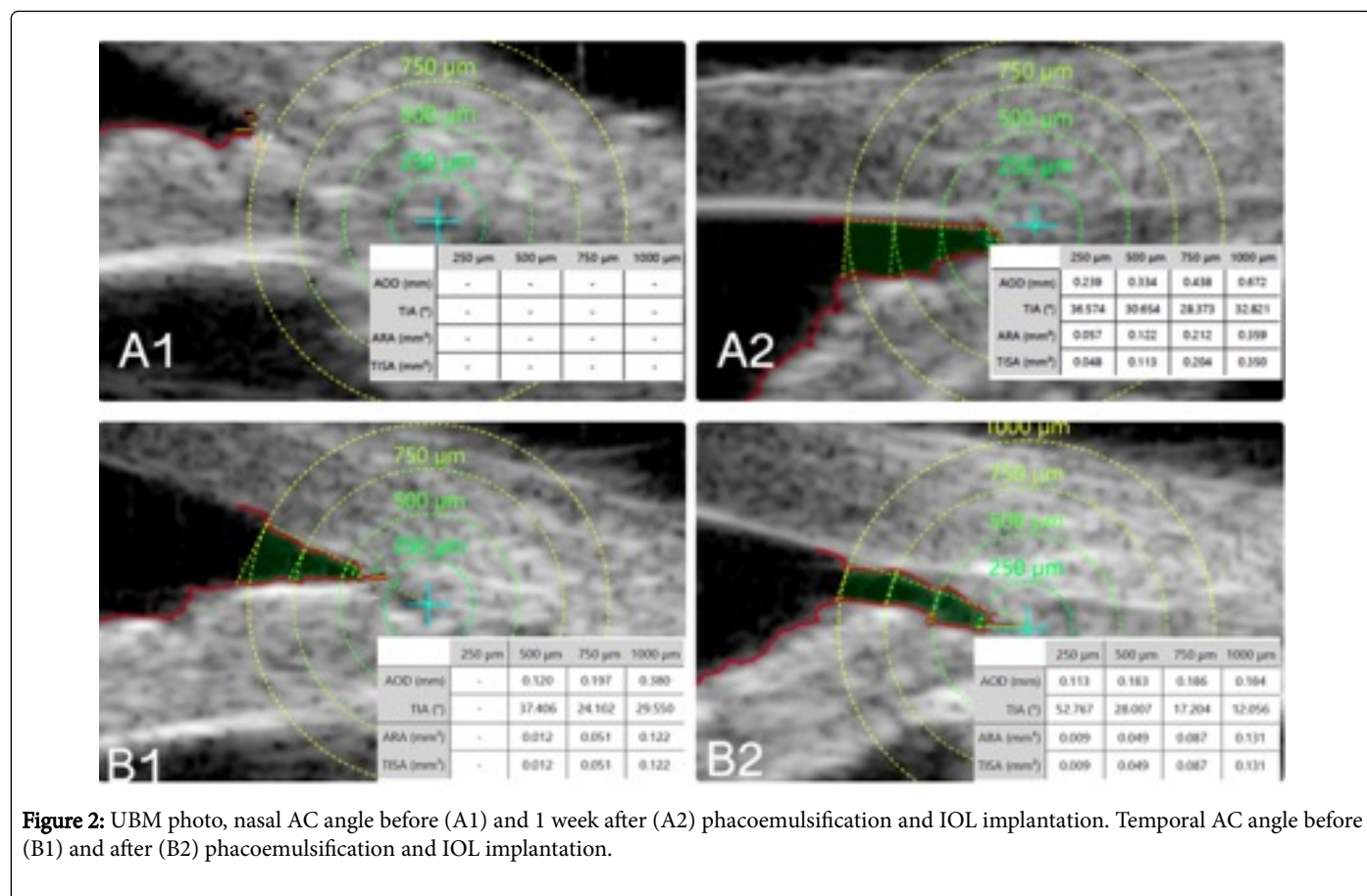
Figure 1: UBM photo CCT and ACD before (A), and 1 week after (B) phacoemulsification and IOL implantation.

Investigation	Preop Mean ± SD	1st w postop Mean ± SD	1st m postop. Mean ± SD	Repeated ANOVA	measures	P value	Post Hoc
AS-OCT	512.0 ± 20.18	545.03 ± 27.90	540.71 ± 30.4	18.33		<0.001	P1 <0.001
							P2 <0.001
							P3 0.50
UBM	519.7 ± 18.91	545.12 ± 28.7	539.42 ± 28.13	10.82		<0.001	P1 <0.001
							P2 <0.001
							P3 0.17
Pentacam	517.8 ± 21.71	547.84 ± 26.3	538.1 ± 29.4	13.9		<0.001	P1 <0.001

						P2 <0.001
						P3 0.12
F test	1.56	0.13	0.07	-----	-----	-----
P value	0.21	0.87	0.92	-----	-----	-----

P1 for comparison between preop. and 1st week postop. , P2 for comparison between preop., and 1st month postop., P3 for comparison between 1st week and 1st month postop.

Table 3: Comparison between the mean central corneal thicknesses (CCT) values\ preoperatively, 1st week and 1st month postoperative.



Discussion

After cataract extraction some changes occur in the anterior segment of the eye, mainly change in the AC depth and the iridocorneal angle.

In the current study, with all the 3 different techniques used, the AC depth showed significant increase in the first postoperative week than the preoperative level (p<0.001). There was no significant difference between the AC depth at 1st week and 1st month after surgery (p>0.05).

This goes very well with many researchers. Junejo et al. [21] studied a total of 74 subjects with overall preoperative ACD was 3.02 ± 0.43 which increased to 3.46 ± 0.44 after 1 day of cataract surgery, then

3.64 ± 0.46 after 1 week and after 1 month of surgery it reached 3.81 ± 0.46 with significant increase from the preoperative level (p<0.001). They concluded that "after uneventful phacoemulsification along with IOL implantation, the anterior chamber angle depth increased markedly".

The same was reported by Kim et al. [22]. They found that angle opening distance (AOD), trabecular iris surface area (TISA), and trabecular-iris angle (TIA) increased significantly after cataract surgery and showed positive correlation with ACA. They studied Forty-five eyes underwent AS-OCT imaging in order to evaluate anterior chamber configuration before and 2 days after phacoemulsification and IOL implantation and found that the postoperative central ACD increased to 4.14 ± 0.31 mm (p<0.001).

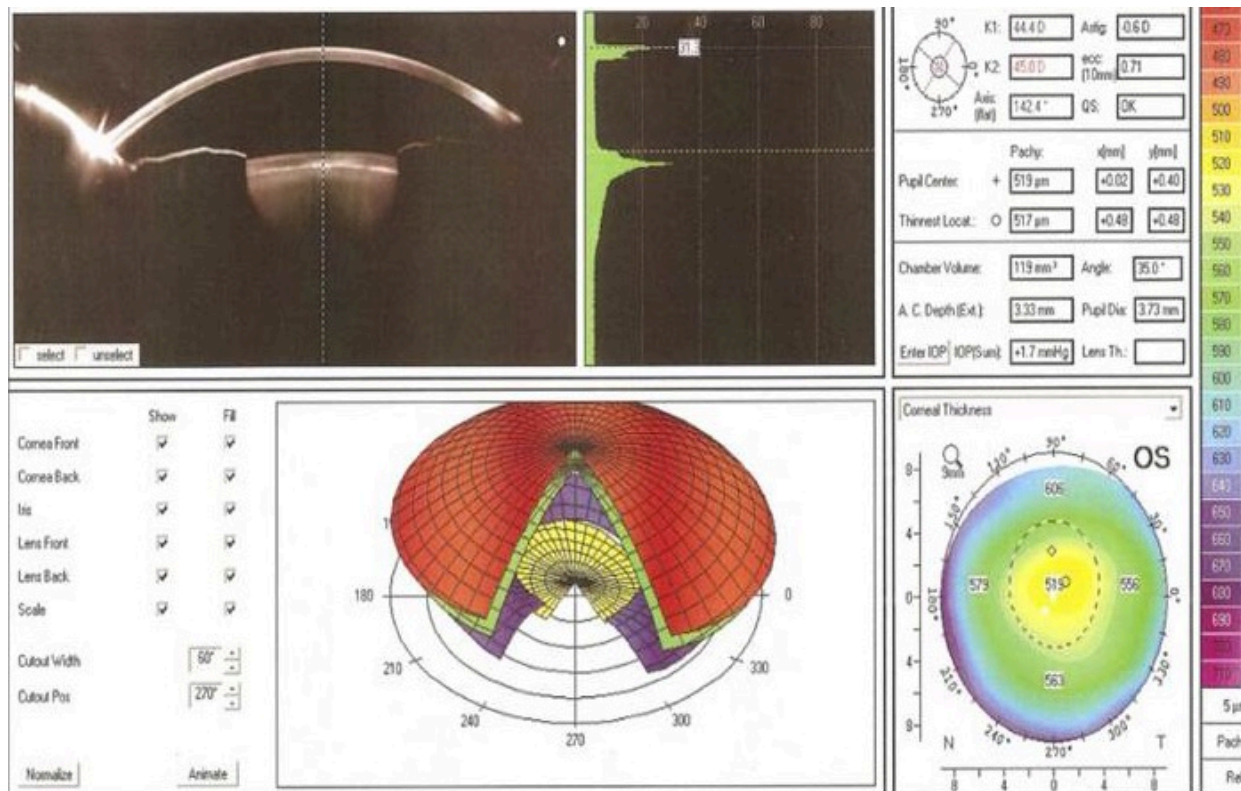


Figure 3: Pentacam photo, AC angle, AC depth and CCT preoperative 1 week of phacoemulsification and IOL implantation.

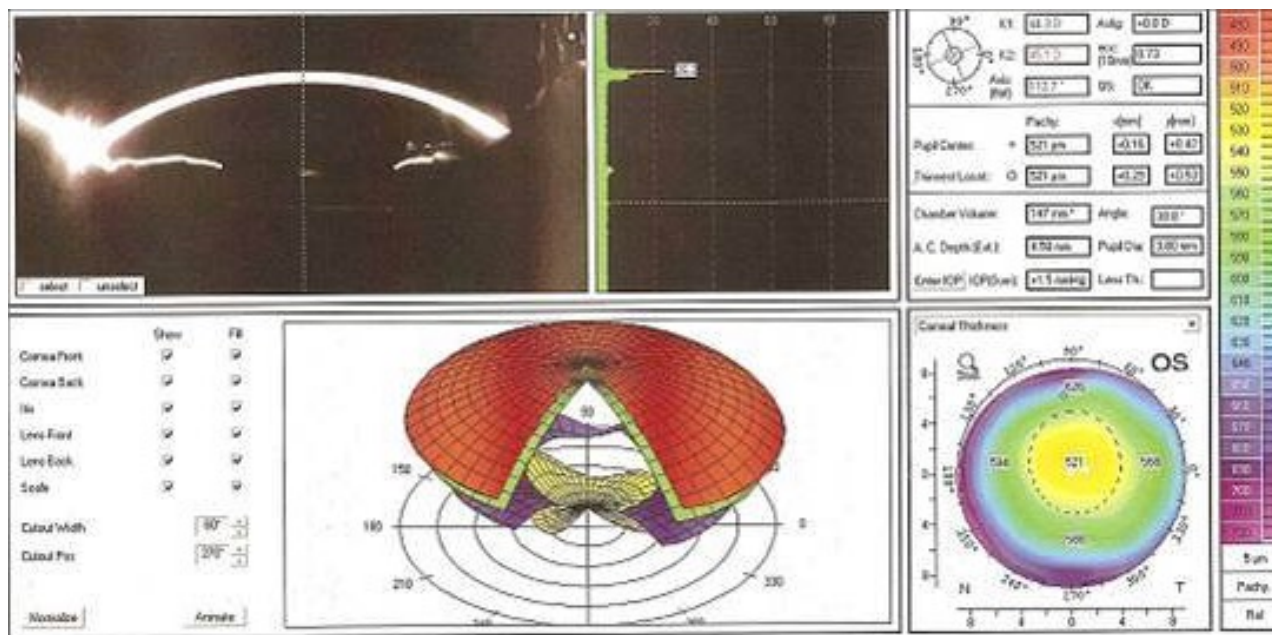


Figure 4: Pentacam photo, AC angle, AC depth and CCT after 1 week of phacoemulsification and IOL implantation.

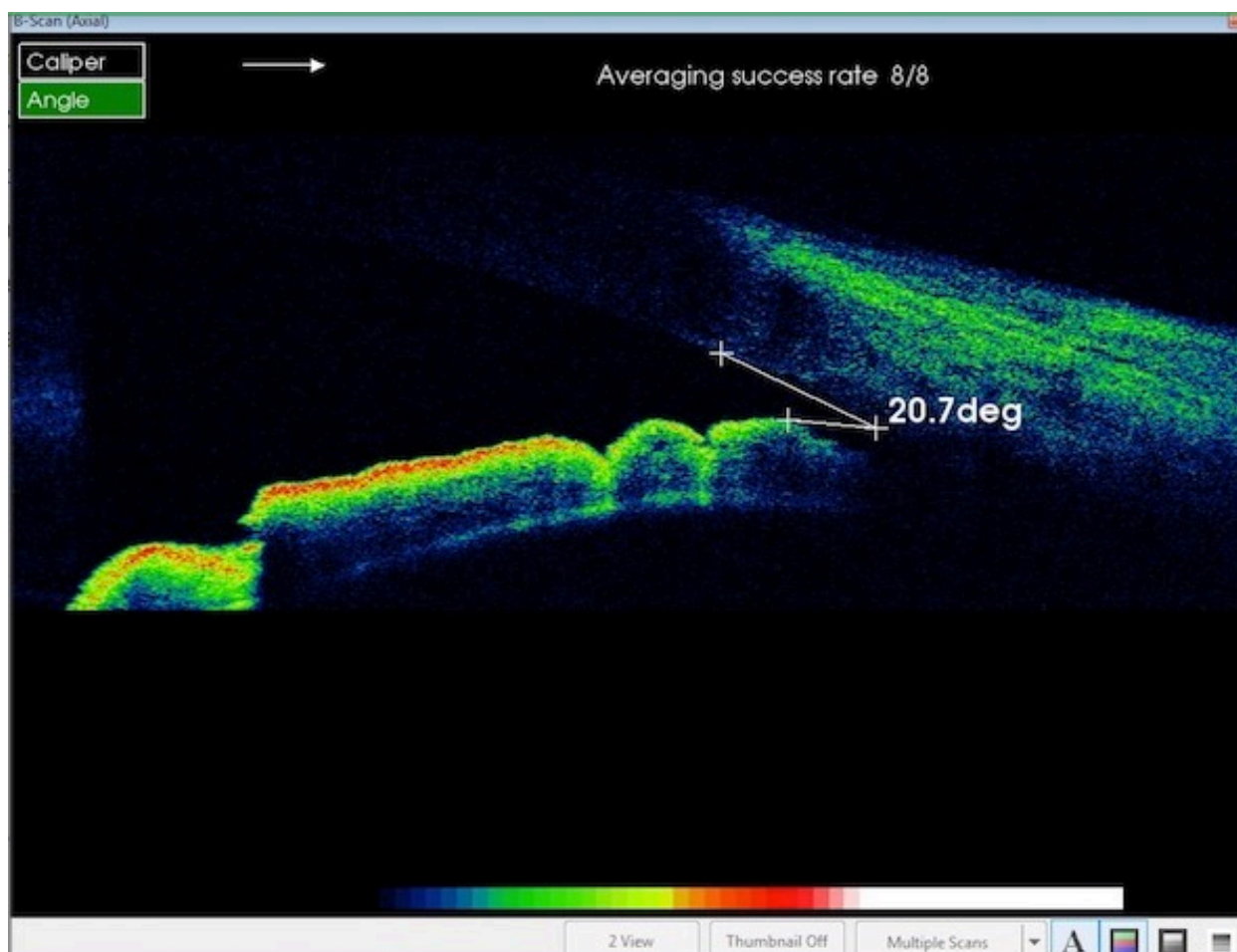


Figure 5: AS-OCT photo, AC angle before 1 week of phacoemulsification and IOL implantation.

Doganay et al. [23] studied the AC depth in 42 eyes which were evaluated preoperatively, and at 1, 3 and 6 months after cataract surgery using the Pentacam. The mean preoperative ACD measurements were 2.79 ± 0.42 mm which increased significantly to 4.41 ± 0.45 mm, 4.63 ± 0.57 mm and 4.65 ± 0.32 mm at 1, 3 and 6 months postoperatively, respectively ($p < 0.05$).

The widening of the iridocorneal angle is the main change occurs in the anterior segment of the eye after cataract extraction. This was evident in this study as the angle widened significantly at the 1st week of surgery than the preoperative measure ($p < 0.001$). The angle then kept widened till the 1st month after surgery with no significant difference from the 1st week after surgery.

Kim et al. reported the same conclusion in the year 2011 [22]. In their study, before surgery, the mean anterior chamber angle widths were $23.21 \pm 6.70^\circ$ in the nasal quadrant and $24.89 \pm 7.66^\circ$ in the temporal quadrant which increased significantly to $35.16 \pm 4.65^\circ$ in the nasal quadrant ($p = 0.001$) and $36.03 \pm 4.86^\circ$ in the temporal quadrant ($p = 0.001$). Also, Doganay et al. [23], found the mean anterior chamber angle (ACA) measurements were $33 \pm 6^\circ$ preoperatively changed to $42 \pm 7^\circ$, $44 \pm 7^\circ$ and $43 \pm 6^\circ$ at 1, 3 and 6 months postoperatively,

respectively. The differences between pre and postoperative ACA measurements were statistically significant ($p < 0.05$).

Huang et al. [13] studied 26 eyes classified as having narrow angle (NA). They measured the angle width, ACD and IOP before and 6 months after surgery. They found the mean (SD) angle opening distance 500 μ m (AOD500) anterior to scleral spur and ACD in were (in Shaffer grading) 0.179 (0.014) mm and 2.23 (0.07) mm, respectively which changed to 0.389 (0.025) mm and 3.75 (0.05) mm 6 months after surgery, respectively with significant reduction in IOP.

Shin et al. [24] found a significant increase in ACD and a significant reduction in IOP ($p < 0.01$) after cataract surgery when they compared non-glaucomatous eyes with open angles or with occludable angles. This deepening in the AC was inversely related to preoperative ACD in the occludable-angle group ($P < 0.01$).

This study showed significant increase in the CCT in the 1st week after lens extraction ($p < 0.001$), then start to decrease afterwards but with no significant difference when measured at the 1st postoperative months ($p > 0.05$). This happened with the 3 different used methods of measurement with no significant difference between them.

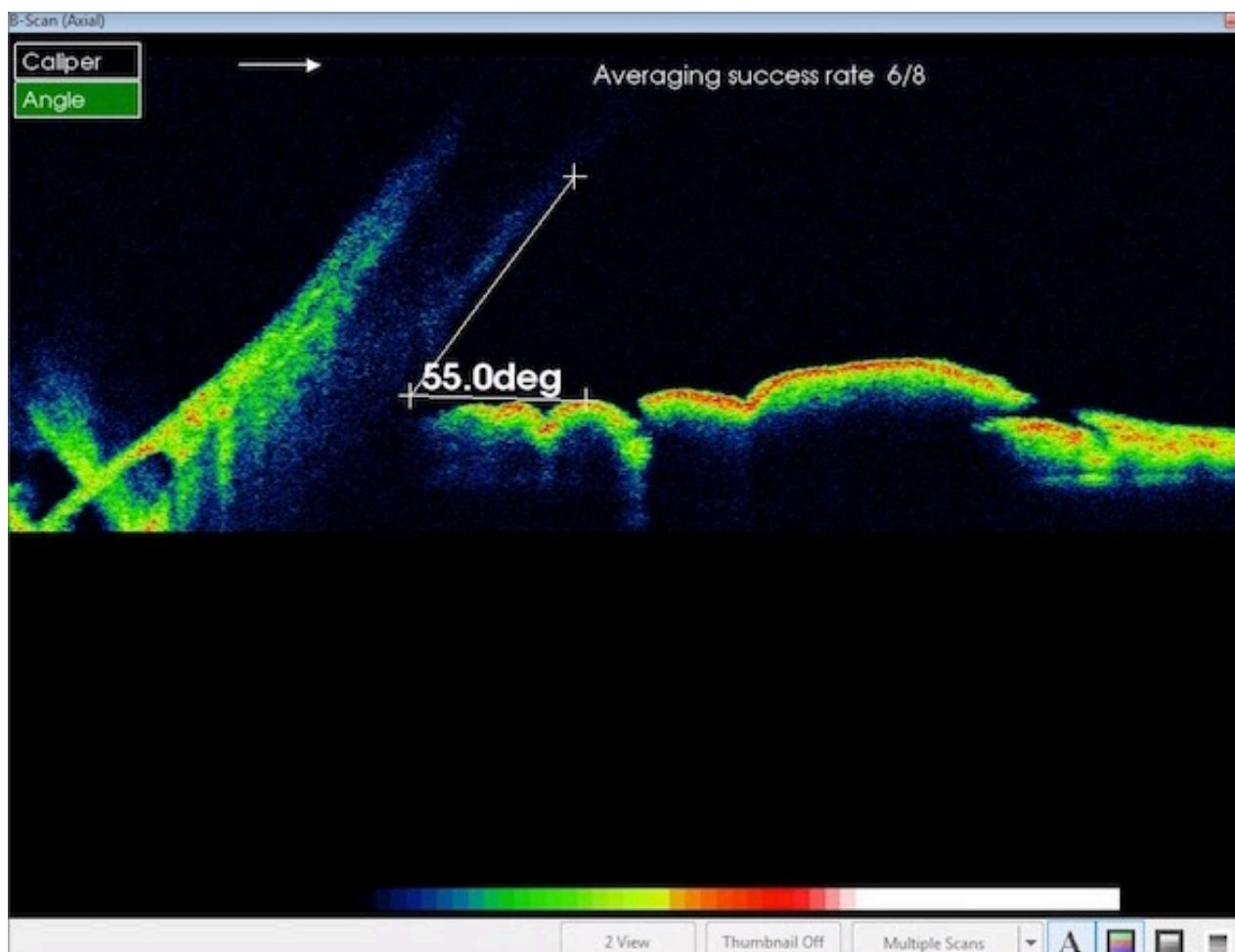


Figure 6: AS-OCT photo, AC angle after 1 week of phacoemulsification and IOL implantation showing increased AC angle than preoperative measure.

This was in agreement to Cetinkaya et al. [25] in their retrospective study, who found the Preoperative mean CCT value was $550.89 \pm 20.07 \mu\text{m}$. The increase that happened in CCT values of 1st week and 1st month after surgery was statistically significant, but those of 3rd month, 6th month, 1st year and 2nd year were not significant.

However, this was different to what was stated by Doganay et al. [23], who found no difference between preoperative and postoperative CCT. They found the mean CCT measurements were $534 \pm 34 \mu\text{m}$ preoperatively and $528 \pm 35 \mu\text{m}$, $528 \pm 36 \mu\text{m}$ and $538 \pm 37 \mu\text{m}$ at 1, 3 and 6 months postoperatively, respectively. The differences between pre- and postoperative CCT measurements were not statistically significant ($p > 0.05$).

Cetinkaya et al. [25], when retrospectively studied 112 eyes with cataract and ocular hypertension found that the increase in ACD of the 1st week, 1st, 3rd, 6th month, and 1st year after surgery was statistically significant, however, at the 2nd year it was not. Preoperative mean iridocorneal angle value was Grade 2.85 ± 0.75 (2-4) according to Shaffer classification. The increase in iridocorneal angle values of the 1st week, 1st month, 3rd month, 6th month, and 1st

year was statistically significant, but that of the 2nd year was not significant.

Baxant et al. [26], studied 170 eyes of 119 patients undergoing phacoemulsification, followed by PC-IOL implantation. They observed a significant increase of ACD, ACV and ACA of patients and mostly in the PACG group ($p < 0.05$) at the 3rd week and 3rd month after surgery.

Conclusion

AS-OCT & UBM & Pentacam demonstrated increase of AC depth, angle width and CCT at 1st week after uneventful phacoemulsification surgery and Foldable IOL implantation, which have become stabilized at 1st month after surgery with no significant differences between the 3 used techniques.

References

1. Kessler J (1957) Mechanisms in angle-closure glaucoma. *Am J Ophthalmol* 43: 271-275.
2. J Heys JJ, Barocas VH, Taravella MJ (2001) Modeling passive mechanical interaction between aqueous humor and iris. *J Biomech Eng* 123: 540-547.

3. Bowling B, Kanski JJ (2016) *Kanski's clinical ophthalmology: A systematic approach* (8th edn) Elsevier, Sydney.
4. Hayashi K, Hayashi H, Nakao F, Hayashi F (2000) Changes in anterior chamber angle width and depth after intraocular lens implantation in eyes with glaucoma. *Ophthalmology* 107: 698-703.
5. Ge J, Guo Y, Liu Y (2001) Preliminary clinical study on the management of angle closure glaucoma by phacoemulsification with foldable posterior chamber intraocular lens implantation. *Zhonghua Yan Ke Za Zhi* 37: 355-358.
6. Hayashi K, Hayashi H, Nakao F, Hayashi F (2001) Effect of cataract surgery on intraocular pressure control in glaucoma patients. *J Cataract Refract Surg* 27: 1779-1786.
7. Casson RJ, Riddell CE, Rahman R, Byles D, Salmon JF (2002) Long-term effect of cataract surgery on intraocular pressure after trabeculectomy: extracapsular extraction versus phacoemulsification. *J Cataract Refract Surg* 28: 2159-2164.
8. Altan C, Bayraktar S, Altan T, Eren H, Yilmaz OF (2004) Anterior chamber depth, iridocorneal angle width, and intraocular pressure changes after uneventful phacoemulsification in eyes without glaucoma and with open iridocorneal angles. *J Cataract Refract Surg* 30: 832-838.
9. Lam DS, Leung DY, Tham CC, Li FC, Kwong YY, et al. (2008) Randomized trial of early phacoemulsification versus peripheral iridotomy to prevent intraocular pressure rise after acute primary angle closure. *Ophthalmology* 115: 1134-1140.
10. Poley BJ, Lindstrom RL, Samuelson TW, Schulze R (2009) Intraocular pressure reduction after phacoemulsification with intraocular lens implantation in glaucomatous and nonglaucomatous eyes: evaluation of a causal relationship between the natural lens and open-angle glaucoma. *J Cataract Refract Surg* 35: 1946-1955.
11. Lee SJ, Lee CK, Kim WS (2010) Long-term therapeutic efficacy of phacoemulsification with intraocular lens implantation in patients with phacomorphic glaucoma. *J Cataract Refract Surg* 36: 783-789.
12. Rabsilber TM, Khoramnia R, Auffarth GU (2006) Anterior chamber measurements using Pentacam rotating Scheimpflug camera. *J Cataract Refract Surg* 32: 456-459.
13. Huang G, Gonzalez E, Peng PH, Lee R, Leeungurasatien T, et al. (2011) Anterior Chamber Depth, Iridocorneal Angle Width, and Intraocular Pressure Changes After Phacoemulsification Narrow vs Open Iridocorneal Angles. *Arch Ophthalmol* 129: 1283-1290.
14. Radhakrishnan S, Rollins AM, Roth JE, Yazdanfar S, Westphal V, et al. (2001) Real-time optical coherence tomography of the anterior segment at 1310 nm. *Arch Ophthalmol* 119: 1179-1185.
15. Lee R, Ahmed II (2006) Anterior segment optical coherence tomography: non-contact high resolution imaging of the anterior chamber. *Tech Ophthalmol* 4: 120-127.
16. Nolan W (2008) Anterior segment imaging: ultrasound biomicroscopy and anterior segment optical coherence tomography. *Curr Opin Ophthalmol* 19: 115-1121.
17. Nolan W (2008) Anterior segment imaging: identifying the landmarks. *Br J Ophthalmol* 92: 1575-1576.
18. Radhakrishnan S, Huang D, Smith SD (2005) Optical coherence tomography imaging of the anterior chamber angle. *Ophthalmol Clin North Am* 18: 375-381.
19. Richards DW, Russell SR, Anderson DR (1993) A method for improved biometry of the anterior chamber with a Scheimpflug technique. *Invest Ophthalmol Vis Sci* 29: 1826-1835.
20. Shibata T, Sasaki K, Sakamoto Y, Takahashi N (1990) Quantitative chamber angle measurement utilizing image-processing techniques. *Ophthalmic Res* 22: 81-84.
21. Junejo MK, Chaudhry TA (2016) Anterior Chamber Depth Changes after Uneventful Phacoemulsification. *Pak J of Ophthalmol* 32.
22. Kim M, Park KH, Kim T, Kim DM (2011) Changes in Anterior Chamber Configuration after Cataract Surgery as Measured by Anterior Segment Optical Coherence Tomography. *Korean J Ophthalmol* 25: 77-83.
23. Doganay S, Firat PB, Emre S, Yologlu S (2010) Parameter changes using the Pentacam after uneventful phacoemulsification. *Acta Ophthalmol* 88: 601-606.
24. Shin HC, Subrayan V, Tajunisah I (2010) Changes in anterior chamber depth and intraocular pressure after phacoemulsification in eyes with occludable angles. *J Cataract Refract Surg* 36: 1289-1295.
25. Cetinkaya S, Dadaci Z, Yener HI, Acir NO, Cetinkaya YF, et al. (2015) The effect of phacoemulsification surgery on intraocular pressure and anterior segment anatomy of the patients with cataract and ocular hypertension. *Ind J Ophthalmol* 63: 743-745.
26. Baxant AD, Hornová J, Studený P, Vránová J, Rosina J (2016) Anterior Chamber Morphometry before and after Cataract Surgery. *J Clin Exp Ophthalmol* 7: 7-2.