

Clubfoot and Congenital Muscular Torticollis Prevalence in Children Diagnosed with Developmental Dysplasia of Hip: Review of 594 DDH Patients

Ayman H. Jawadi*

Department of Surgery, King Saud bin Abdulaziz University for Health Sciences, Saudi Arabia

*Corresponding author: Ayman H. Jawadi, Associate Professor, Pediatric Orthopedic Consultant, Department of Surgery, King Saud bin Abdulaziz University for Health Sciences, Riyadh, Saudi Arabia, Tel: 966-50-546-9606; E-mail: dr.jawadi@gmail.com

Rec date: May 06, 2016, Acc date: May 18, 2016, Pub date: May 24, 2016

Copyright: © 2016 Jawadi AH. This is an open-access article distributed under the terms of the Creative Commons Attribution License, which permits unrestricted use, distribution and reproduction in any medium, provided the original author and source are credited.

Abstract

Background: Developmental dysplasia of the hip (DDH) refers to a spectrum of disease, including hips that are unstable, subluxated, dislocated, and/or has dysplastic acetabula. Feet deformities such as clubfoot were mentioned in the literature as associated congenital anomalies in DDH patient with variable results. Multiple studies reported the correlation between DDH and congenital muscular torticollis (CMT) at a rate between 20% and 29%. In this study we determined the overall prevalence of clubfoot and/ or CMT in children who were diagnosed as idiopathic DDH in our tertiary care hospital.

Materials and methods: The charts of 594 patients diagnosed as idiopathic DDH between January 2007 and December 2014 were retrospectively evaluated in this study. Demographic data and patient's history were obtained from medical files and pelvic X-rays of DDH patients associated with clubfoot and CMT were reviewed. The outcome was evaluated according to the DDH risk factors. Statistical analysis of the data was performed using Excel program (Microsoft Office version 2011).

Results: Out of 594 DDH patients; male were 105 (17.7%), and female 489 (82.3%). Bilateral DDH was found in 252 patients (42.4%), left DDH in 180 patients (30.3%), and right DDH in 162 patients (27.3%). None of the cases had CMT, while 11 patients (1.9%) had clubfeet. All DDH patients with clubfeet but one, showed severe form of DDH; Tonnis classification type IV.

Conclusion: Although the association between DDH and clubfoot and/or CMT has been reported in literature with variant results, careful clinical examination is recommended to detect such disorders that can be treated earlier.

Keywords: DDH; CMT; Clubfoot; Risk factors; Prevalence

Introduction

Developmental dysplasia of the hip (DDH) (Figure 1) is a spectrum of disease, including hips that are unstable, dysplastic acetabula, subluxated, and/or dislocated [1-3]. Although clubfoot diagnosis is made clinically (Figure 2), DDH has to be diagnosed clinically and confirmed by imaging modalities. There are some factors that are known to be associated with DDH, such as positive family history, breech presentation, female sex, oligohydramnios and associated congenital anomalies [4]. Feet deformities like metatarsus adductus, calcaneovalgus, clubfoot and congenital muscular torticollis (CMT) have been mentioned in the literature as associated congenital anomalies in DDH patients [5]. Metatarsus adductus has been reported as an associated anomaly with a wide range of 1.5% to 39% [6-8]. Abu Hassan and Shannak [5] reported a 2.16% calcaneovalgus and 0.54% CMT in 370 children who were evaluated in the pediatric orthopaedic clinic and diagnosed as DDH. No congenital clubfoot or matatarsus adductus were reported in their study. The association of DDH with CMT is quite strong [4,9]. Multiple studies reported a correlation between CMT and DDH at a rate between 2% and 29% [10]. Perry et al. [11] studied 119 babies with clubfeet and found DDH in 7 cases only (5.9%). Idiopathic clubfoot affects approximately 1-2

per 1000 births [12], while the incidence of CMT is reported as 0.017% to 1.9% in infants [10].

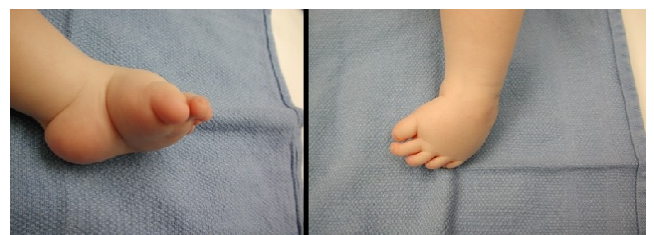

Figure 1: Congenital club foot.

The aim of this study is to determine the overall incidence of clubfoot and CMT in children who were diagnosed as idiopathic DDH in tertiary care hospitals in Riyadh, Saudi Arabia.

Methods

Between January 2007 and December 2014 a total of 594 patients diagnosed as idiopathic DDH were retrospectively evaluated in the pediatric orthopedic clinic in two main hospitals in Riyadh, Saudi

Arabia. Demographic data and patients' history were obtained from medical files, including presentation at delivery, sex, 1st baby, history of oligohydramnios during pregnancy, family history of DDH, and method of delivery. Pelvic X-rays of DDH patients associated with clubfoot or/ and CMT were reviewed to categorize the hips to subluxated, dislocated, and dysplastic hips. Tonnis classification [13] was used to identify the severity of DDH using the relative position of the ossific nucleus to Perkin's (P-line) and Hilgenreiner's lines (H-line) (Table 1).

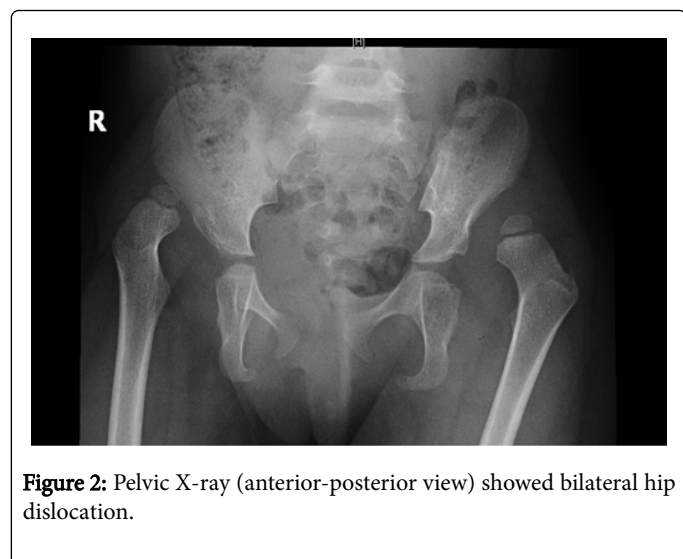


Figure 2: Pelvic X-ray (anterior-posterior view) showed bilateral hip dislocation.

The diagnosis of CMT was based on clinical criteria including limited range of motion of the head and head tilt. Clubfoot was

diagnosed clinically and severity was classified according to Pirani score [12,14]. Statistical analysis of the data was performed using Excel program (Microsoft Office version 2011).

Results

The study included 594 patients diagnosed, as idiopathic DDH with 105 males (17.7%), and 489 female (82.3%). Bilateral DDH was found in 252 patients (42.4%), left DDH in 180 patients (30.3%), and right DDH in 162 patients (27.3%). None of the cases had CMT, while 11 patients (1.9%) had clubfoot (Table 2). All clubfeet were severe (Pirani score 6/6). One patient had right clubfoot, 3 had left clubfeet, and 7 had bilateral clubfeet. Associated risk factors in children with DDH who had clubfoot deformity are shown in Table 3. All clubfeet patients but one, showed severe form of DDH; Tonnis classification type IV. Among the clubfoot patients, female sex was found only in 4 patients (36.4%) and breech delivery was reported in 2 patients (18.2%). All clubfoot patients had full term and normal delivery. None of them were the first-born baby or had history of oligohydramnios during pregnancy.

Grade I	The ossification center is medial to the P-line
Grade II	The ossification center is lateral to P-line, but below H-line
Grade III	The ossification center is at the level of H-line
Grade IV	The ossification center is above H-line
P-line: Perkin's line; H-line: Hilgenreiner's line	

Table 1: Tonnis classification of DDH.

Patient No.	Gender	Full term	Presentation Cephalic Breech (B) (C)/	Delivery	First born baby	Oligohydramnios	Positive family history	Tonnis classification	Site of DDH	Site of clubfoot
1	Male	Yes	C	Normal	No	No	No	III	R	R
2	Male	Yes	C	Normal	No	No	No	IV	B	B
3	Male	Yes	C	Normal	No	No	No	IV	L	L
4	Female	Yes	B	Normal	No	No	Yes	IV	L	B
5	Male	Yes	C	Normal	No	No	No	IV	L	B
6	Female	Yes	B	Normal	No	No	Yes	IV	L	B
7	Male	Yes	C	Normal	No	No	Yes	IV	B	L
8	Male	Yes	C	Normal	No	No	No	IV	R	L
9	Female	Yes	C	Normal	No	No	Yes	IV	B	B
10	Male	Yes	C	Normal	No	No	Yes	IV	R	B
11	Female	Yes	C	Normal	No	No	Yes	IV	B	B

R: Right; L: Left; B: Bilateral

Table 2: DDH associated with clubfoot.

Associated risk factors	Number of children (%)	Site of clubfoot			Types of DDH (Tonnis classification)	
		R	L	B	III	IV
Full term delivery	11 (100%)	1	3	7	1	10
Female sex	4 (36.4%)	0	0	4	0	4
1st child	0 (0%)	0	0	0	0	0
FH of DDH	6 (54.5%)	0	1	5	0	6
Normal delivery	11 (100%)	1	3	7	1	10
Breech delivery	2 (18.2%)	0	0	2	0	2
Oligohydramnios	0 (0%)	0	0	0	0	0

R: Right; L: Left; B: Bilateral

Table 3: Associated risk factors in children with DDH and clubfoot.

Discussion

DDH and idiopathic clubfoot are common pediatric orthopedic conditions that represent a spectrum of diseases [15]. The underlying etiology of both is unknown but an association between the two has been suggested [11]. The diagnosis of clubfoot is clear by clinical examination, while DDH diagnosis is more difficult to be confirmed clinically because affected individuals can appear normal when examined in infancy and routine clinical screening tests lack high sensitivity [16-18]. This study showed an association between DDH and clubfoot with one in 54 neonates (1.9%) with DDH having severe clubfoot requiring treatment. Plain X-rays diagnosed all DDH patients, while clubfoot was diagnosed clinically using Pirani score for severity [12,14]. Abu Hassan and Shannak [5] reviewed 370 children with DDH and did not report a single case of clubfoot; instead, they found that 2.16% had calcaneovalgus deformity. Perry, et al. [11] screened 119 clubfoot patients for hip dysplasia and reported that 7 cases (5.9%) had DDH requiring treatment. A similar study was done by Westberry, et al. [19] who evaluated the hips of 349 patients with clubfoot and found one patient only had DDH, but radiographs were taken on only 127 patients and the remainder were assessed by clinical examination alone. Ibrahim et al. [15] searched databases from 1946 to 2014 that reported the prevalence of DDH in idiopathic clubfoot and performed a meta-analysis. Out of 12 studies that were eligible for the meta-analysis, they reported that the pooled prevalence estimated of DDH in children with idiopathic clubfoot was 4.1%; which is similar to the normal population. Thus, they did not recommend a routine screening for DDH in children with idiopathic clubfoot. Although in this study we assessed the clubfoot in DDH patients, we have reported small numbers of clubfoot (1.9%), which makes us support with the conclusion that the association between DDH and clubfoot is not significant.

The association between DDH and CMT has been established in the literature with wide range of coexistence from 0 to 20% [4,5,9,10,20]. However, only few studies reported the incidence of cases of DDH that required treatment in patients with CMT, which makes the incidence rates range from 0 to 8.5 % [20]. The diagnosis of CMT is done clinically, which includes decrease neck rotation or lateral bending. Palpable sternocleidomastoid mass may be present as well [21]. Infants with CMT usually develop symptoms after birth, and most patients are

diagnosed at 0 to 3 months of age [10]. Abu Hassan and Shannak in their review of 370 DDH cases reported CMT in 0.56% [5]. In this study, out of 594 children with DDH, no CMT was found. Heidken, et al. found that 5.9% of DDH cases, were subsequently diagnosed with CMT, and they recommended that infants with DDH (especially boys) should be carefully followed up for the development of CMT [10].

This study has limitations as it is a retrospective study and only the diagnosed DDH patients were evaluated for clubfoot and CMT but not vice versa.

In conclusion, although the association between DDH and clubfoot and DDH with CMT has been reported in literature with variant rates, our findings suggest a lower rate of association. Never the less careful clinical examination is recommended to detect such disorders that can be treated earlier.

References

1. Klisic PJ (1989) Congenital dislocation of the hip--a misleading term: brief report. *J Bone Joint Surg Br* 71: 136.
2. Bennett JT, MacEwen GD (1989) Congenital dislocation of the hip. Recent advances and current problems. *Clin Orthop Relat Res* : 15-21.
3. Committee on Quality Improvement, American Academy of Pediatrics (2000) Clinical practice guidelines: early detection of developmental dysplasia of the hip. *Pediatrics* 105: 896-905.
4. Herring JA (2002) Tachdjian's pediatric orthopedics. 3rd edn. W. B. Saunders Company, Philadelphia p: 514-526.
5. Abu Hassan FO, Shannak A (2007) Associated risk factors in children who had late presentation of developmental dysplasia of the hip. *J Child Orthop* 1: 205-210.
6. Grill F, Bensahel H, Canadell J, Dungal P, Matasovic T, et al. (1988) The Pavlik harness in the treatment of congenital dislocating hip: report on a multicenter study of the European Paediatric Orthopaedic Society. *J Pediatr Orthop* 8: 1-8.
7. OmeroÄŸlu H, Koparal S (2001) The role of clinical examination and risk factors in the diagnosis of developmental dysplasia of the hip: a prospective study in 188 referred young infants. *Arch Orthop Trauma Surg* 121: 7-11.
8. Jones DA (1989) Importance of the clicking hip in screening for congenital dislocation of the hip. *Lancet* 1: 599-601.
9. Walsh JJ, Morrissy RT (1998) Torticollis and hip dislocation. *J Pediatr Orthop* 18: 219-221.
10. von Heideken J, Green DW, Burke SW, Sindle K, Denneen J, et al. (2006) The relationship between developmental dysplasia of the hip and congenital muscular torticollis. *J Pediatr Orthop* 26: 805-808.
11. Perry DC, Tawfiq SM, Roche A, Shariff R, Garg NK, et al. (2010) The association between clubfoot and developmental dysplasia of the hip. *J Bone Joint Surg Br* 92: 1586-1588.
12. Jawadi AH (2010) Clubfoot management by the Ponseti technique in Saudi patients. *Saudi Med J* 31: 49-52.
13. Tonnis D (1987) Congenital dysplasia and dislocation of the hip in children and adults. Berlin, Germany: Springer-Verlag.
14. Pirani S, Outerbridge H, Sawatzky B, Stothers K (1999) A reliable method of clinically evaluating a virgin clubfoot evaluation. 21st SICOT congress.
15. Ibrahim T, Riaz M, Hegazy A (2015) The prevalence of developmental dysplasia of the hip in idiopathic clubfoot: a systematic review and meta-analysis. *Int Orthop* 39: 1371-1378.
16. David TJ, Parris MR, Poynor MU, Hawnaur JM, Simm SA, et al. (1983) Reasons for late detection of hip dislocation in childhood. *Lancet* 2: 147-149.
17. Jones D (1998) Neonatal detection of developmental dysplasia of the hip (DDH) *J Bone Joint Surg Br* 80: 943-945.
18. Godward S, Dezateux C (1998) Surgery for congenital dislocation of the hip in the UK as a measure of outcome of screening. MRC Working Party

-
- on Congenital Dislocation of the Hip. Medical Research Council. *Lancet* 351: 1149-1152.
19. Westberry DE, Davids JR, Pugh LI (2003) Clubfoot and developmental dysplasia of the hip: value of screening hip radiographs in children with clubfoot. *J Pediatr Orthop* 23: 503-507.
20. Joiner ER, Andras LM, Skaggs DL (2014) Screening for hip dysplasia in congenital muscular torticollis: is physical exam enough? *J Child Orthop* 8: 115-119.
21. Kim SN, Shin YB, Kim W, Suh H, Son HK, et al. (2011) Screening for the coexistence of congenital muscular torticollis and developmental dysplasia of hip. *Ann Rehabil Med* 35: 485-490.