

Cleidocranial Dysplasia: Maxillary Alterations on the Transverse Plane. Presence of Crown-radicular Anomalies and Multidisciplinary Approach of a Clinical Case

Romeo U, Galluccio G, Palaia G, Tenore G, Carpenteri F, Barbato E, Polimeni A

Department of Oral and Maxillofacial Sciences, Sapienza University of Rome, Rome, Italy

Abstract

Introduction: Cleidocranial Dysplasia (CCD) is a rare inherited autosomal dominant congenital syndrome that occurs in approximately one out of every one million individuals worldwide; it primarily affects bones that undergo intra-membranous ossification, generally the skull and clavicles. Other bones may be affected such as the long bones, spine, pelvis, bones of hands and feet showing hypoplasia of distal phalanges. Indispensable is the role of the gene *Runx2*, necessary for the differentiation of odontoblasts and osteoblasts; it regulates the expression of many genes related to the development of dental hard tissues. The aim of this study was to appraise the connection between the Cleidocranial Dysplasia and the appearance of skeletal and dental anomalies not much deepen to this day. With particular emphasis, it wants to describe the multidisciplinary therapeutic approach.

Case Report: The patient showed multiple skeletal features of CCD. A distinctive feature was the failed or delayed exfoliation of deciduous dentition and a delayed eruption of permanent teeth.

The goal of the treatment is the improvement of both aesthetic and functional aspects. This objective can be achieved through an appropriate multidisciplinary treatment plan that arranges the orthodontic and surgical measures.

Results and Discussions: Because of the involvement of facial bones, the altered mode of tooth eruption and the presence of numerous included supernumerary teeth, CCD is a pathology that all dentists should be familiar with. The patients have small faces compared to the skull and the hypoplasia of maxillary, tear, nasal and zygomatic bones. The orthodontic approach in literature seems to be reduced to the guided eruption of bad-positioned and impacted teeth. Knowledge of the clinical features of CCD allows for the early planning of the procedures necessary to resolve the dental pathologies observed in CCD patients.

Keywords: Cleidocranial dysplasia, Runx2, Orthodontic surgery, Supernumerary teeth, Delayed eruption

Introduction

Cleidocranial Dysplasia (CCD, OMIM # 119600) is a rare inherited congenital autosomal dominant syndrome that is also known as cleidocranial dysostosis [1-3]. CCD was described for the first time by Pierre Marie and Paul Sainton in 1898 [4]; since its discovery, several cases have been documented in the medical literature [5,6]. One of the most interesting cases was described by Jackson in 1951 [7]. Clinically, CCD predominately affects bones that undergo intra-membranous ossification, generally the skull and clavicles. However, several clinical studies have shown that the CCD is a generalised skeletal disorder that affects not only the clavicles and skull, but also the entire skeleton. Therefore, it is considered to be a *dysplasia* rather than a dysostosis [8]. CCD is characterised by skeletal defects in various bones including the partial or complete absence of clavicles, delayed closure of the fontanelles, the presence of open sutures of the skull and multiple wormian bones. The skull base is dysplastic and reduced in growth; which results in a greater skull width that leads to brachycephaly, hypertelorism and exophthalmos [9]. Patients with CCD typically exhibit altered dentition and dental development. A distinctive feature is the delayed or failed exfoliation of deciduous dentition and a delayed eruption of the permanent teeth; consequently, adults with CCD frequently have a mixed dentition. In addition, patients with this condition often exhibit a high number of included

supernumerary teeth that frequently induce follicular cyst formation.

CCD is an inherited syndrome with an autosomal dominant modality. However, in 1975 Goodman et al. described an autosomal recessive form in 2 families in which the children of unaffected consanguineous parents showed a particularly severe variation with abnormalities of the spinal cord and dwarfism [10]. The role of the gene *Runx2* located on chromosome *6p21*, necessary for the differentiation of odontoblasts and osteoblasts, which regulates the expression of many genes related to the development of dental hard tissues, is primary [11,12]. *Runx2*, which is also known as *core binding factor alpha 1* (CBFa1), is one of the main transcription factors specific for bone and cartilage. It plays a key role in all stages of bone formation and is essential for the differentiation of mesenchymal cells into osteoblasts; further, it controls the proliferation, differentiation and maintenance of these cells. *Runx2* is also necessary for odontoblast differentiation and regulates the expression of many genes related to the development of teeth and bones [13]. In a murine model with reduced *Runx2* expression, animals exhibited decreased expression of the genes that encode the main bone matrix proteins osteocalcin, osteopontin and collagen type I. The murine study demonstrated how *Runx2* is essential for normal bone formation, and how, when its levels are insufficient, altered or abnormal bone growth results. Additionally, *Runx2* overexpression can affect bone formation,

Corresponding author: Palaia G, Department of Oral and Maxillofacial Sciences, Sapienza University of Rome, Rome, Italy, Tel: +390649976611; E-mail: gaspare.palaia@uniroma1.it

leading to osteopaenia with decreased bone mineral density. Runx2 overexpression is thought to trigger reduced osteoblast maturation and increased osteoclastogenesis due to the increased production of receptor activator for nuclear factor- κ B ligand (RANKL) and matrix metalloproteinase-13 (MMP-13). Runx2 is also important for the secondary stages of tooth formation, as it is intimately involved in the development of calcified tooth tissue and regulates dental lamina proliferation. In addition, Runx2 regulates the remodelling of the alveolar process, which is essential for tooth eruption, and it may play a role in maintaining the periodontal ligament [14].

The diagnosis of CCD is based on clinical and radiographic findings, including evaluations of the skull, chest, pelvis and hands. Genetic tests detect Runx2 mutations in 60%-70% of individuals with a clinical diagnosis of CCD [15].

CCD mainly predominately affects bones derived from intramembranous ossification, such as the skull and clavicles. However, the following bones of endochondral origin can also be affected.

- Abnormally large fontanelles at birth, which may remain open throughout life. The wide metopic suture determines the separation of the frontal bones and the persistence of a groove. The forehead is wide and flat, and the skull is brachycephalic.
- Hypoplasia of the middle third of the face.
- Dentition abnormalities, including delayed eruption of permanent teeth, no exfoliation of deciduous teeth, and a variable number of supernumerary teeth with dental crowding and malocclusions.
- Clavicular hypoplasia, resulting in narrow and sloping shoulders that can be approximated at the midline.
- Anomalies of the hand, such as brachydactyly, tapered fingers and short and broad thumbs.

The identification of mutations in Runx2 causing an isolated dental phenotype in CCD and supernumerary tooth formation in the mouse model clearly demonstrated that it was possible to induce de novo tooth formation by the in situ repression or activation of a single candidate gene. These results support the idea that the de novo repression or activation of candidate genes such as RUNX2 or USAG-1 might be used to stimulate the third dentition in order to induce new tooth formation in the mouse [16].

Typical CCD features are often also associated with otorhinolaryngological manifestations. As the outer ear, middle ear and the base of the skull originate from either endochondral or intramembranous ossification centres, they are frequently malformed in CCD patients. In patients with CCD, the face appears smaller and is sometimes asymmetrical because of hypoplastic jaw and cheekbone growth; also mastoid cells are small or may be absent, there is a high incidence of Eustachian tube dysfunction and there is a higher prevalence of submucous cleft palate [17]. Further, several studies in CCD patients have reported narrow external auditory canals, an increased frequency of recurrent childhood ear infections and various degrees of hearing loss. However, hearing loss has been described in only a few CCD patients. Cooper et al. found a high rate of otologic disorders, including hearing loss (38%) and recurrent otitis media (62%), in patients with CCD (n=116) compared to normal [18,19]. Because of this

high incidence, the same authors recommend a hearing check at birth and during early childhood for all children diagnosed with CCD. Mohan et al. described an interesting and unique case of cleidocranial dysplasia associated with the unusual presence of uterine malformations and vaginal abnormalities [20]. In this case, the patient suffering from CCD was diagnosed with bilateral polycystic ovarian disease (PCOD) and bicornuate unicollis uterus (Mullerian abnormality [20].

4 patients (3 F, 1 M) suffering from CCD, 12-25 years of age, arrived at our observation. Data obtained with the aid of models and radiographic examinations (Rx Orthopantomography, Rx lateral cephalometric skull and Rx posteroanterior cephalometric skull, CT Computed Tomography Dentscan) were compared to literature (*Table 1*). From the literature as well as incongruence between the dental age and chronologic age, a constant presence of morphological coronal-radicular alterations is clear [21].

Some authors emphasize that there is a high risk of apical root resorption during orthodontic treatment in patients with multiple aplasia, in particular in teeth with an abnormal root form and lengthy treatment with elastics and rectangular archwires [22].

We collected data about morphological coronal-radicular abnormalities in our population to evaluate the possibilities and the good outcome of orthodontic treatment in CCD patients (*Table 2*).

Usually in young CCD patients, swelling (due to included teeth or to formation of follicular cysts), pain or functional difficulties are not present and facial features are not evident [23]; thus, the perception of the need of treatment may differ between the patient and a medical specialist.

The case presented is one of the four mentioned above. It was characterized by maxillary alterations on trasversal plan and teeth anomalies and was treated with a multidisciplinary approach.

Case Report

A 14-year-old female with CCD came to our observation since dental causes. At the extraoral examination, the patient exhibited a brachy-facial type, with a concave profile, reduction of verticle dimension, retrusion of maxilla, saddle nose, hypertrichosis and stature at the lower limit of normal.

Oral examination

At the intraoral examination, the patient showed a mixed dentition with the persistence of numerous deciduous teeth and with a marked delay exfoliation in the both the upper and lower arch, mandibular prognathism and the maxilla is underdeveloped with an anterior crossbite; also it was present the reduction of the transverse dimension of the maxilla and ogival palate; normal Overbite and negative Overjet; She also showed a good oral hygiene, moderately inflamed gums and normally inserted fraenula. The patient also presented with hyperdontia and multiple included permanent teeth.

Cephalometric analysis

Subject with maxillary and mandibular protrusion in III skeletal Class (\wedge SNA: 91,09°; \wedge SNB: 91,33°; \wedge ANB: -0,24°), hypodivergent growth pattern (FMA: 14,72°), brachyfacial typology with growth counterclockwise and upwards (\wedge ArSN: 113,98°; \wedge ArGoMe: 120,94°; \wedge NGoMe: 66,04°), increase in

Table 1. Comparisons between transverse amplitude measurements.

Comparisons between transverse amplitude measurements - upper arch			
	Distance between the canines *	Distance between the first premolars *	Distance between the first molars
Patient 1 (F.I.) Age: 12 years Gender: F	25.7 mm*	28.3 mm*	39.5 mm
Standard Value	31.5 mm	35.1 mm	44.6 mm
Patient 2 (R.M.) Age: 8 years Gender: F	24.3 mm*	27.2 mm*	37.6 mm
Standard Value	29.1 mm	33.0 mm	42.4 mm
Patient 3 (V.P.) Age: 12 years Gender: F	23.4 mm*	28.8 mm*	39.2 mm
Standard Value	31.5 mm	35.1 mm	44.6 mm
Patient 4 (L.P.) Age: 6 years Gender: M	21.0 mm*	28.0 mm*	38.9 mm
Standard Value	27.5 mm	32.3 mm	41.9 mm
Comparisons between transverse amplitude measurements - lower arch			
	Distance between the canines *	Distance between the first premolars *	Distance between the first molars
Patient 1 (F.I.) Age: 12 years Gender: F	20.9 mm *	24.2 mm	35.0 mm
Standard Value	24.8 mm	31.6 mm	41.8 mm
Patient 2 (R.M.) Age: 8 years Gender: F	20.1 mm *	25.5 mm *	37.3 mm
Standard Value	24.0 mm	29.5 mm	40.3 mm
Patient 3 (V.P.) Age: 12 years Gender: F	24.0 mm *	28.6 mm*	38.4 mm
Standard Value	24.8 mm	31.6 mm	41.8 mm
Patient 4 (L.P.) Age: 6 years Gender: M	18.5 mm *	23.1 mm *	
Standard Value	23.3 mm	28.7 mm	

The standard values are taken from [29].

Table 2. Root length and dental abnormalities in patients with CCD.

Root length and dental abnormalities in patients with CCD			
Patient (gender)	Root length of the first molars (mm)	Number of supernumerary/supplementary teeth	Number of dental morphological abnormalities
1. F.I. (F)	19,3	6	3
2. R.M. (F)	16,5	3	4
3. V.P. (F)	17,4	6	2
4. L.P. (M)	18,7	4	3
	Standard value: 13,6 ± 1,2 mm		

The standard values are taken from [21].

posterior facial height than the anterior facial height (SGo/NMe: 78,02 %) (Figures 1-3).

A Rapid Palate Expander (RPE) was applied for the expansion of the upper arch (early therapy of Class III in deciduous dentition is able to operate a significant reduction of skeletal anomaly that supports the malocclusion [24] (Figure 4). After few months, the removal of some dental elements and the repositioning of others were required. Written informed consent was obtained from the parents prior to the initiation of the treatment plan. The two arches were treated separately with different operating phases (Table 3).

In the lower arch, a buccal and lingual germectomy of

supernumerary teeth at positions 4.5 and 4.6 was initially performed under general anesthesia in an operating room; next, surgical exposure and attachment of teeth 3.3, 4.3 and 4.5 for orthodontic repositioning was performed. For the surgical exposure, an envelope flap incision was made and then sutured using interrupted sutures with a 3.0 silk thread. This procedure exposed a portion of the crown of the teeth through the use of a micromotor with a straight hand piece at a 1:1 ratio; avulsion was performed using curved and straight levers (Figure 5).

In the upper arch, the first step was the extraction of deciduous dental elements 5.3, 5.4 and 5.5, followed by a

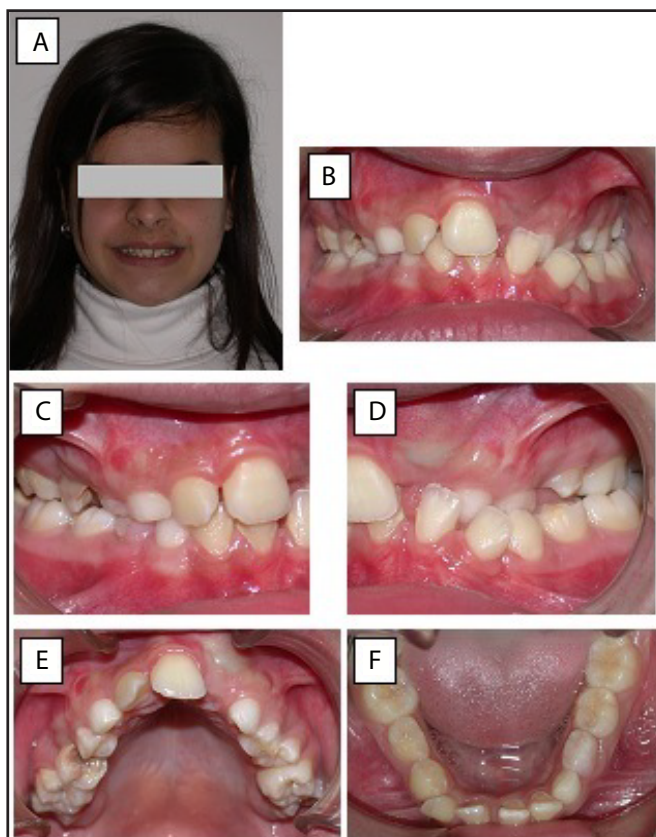


Figure 1. Clinical features of case report.

A: Front picture. B: Intraoral front view. C: Intraoral vestibular view of the first and fourth quadrant. D: Intraoral vestibular view of the second and third quadrant. E: Intraoral occlusal view of the upper arch. F: Intraoral occlusal view of the lower arch.

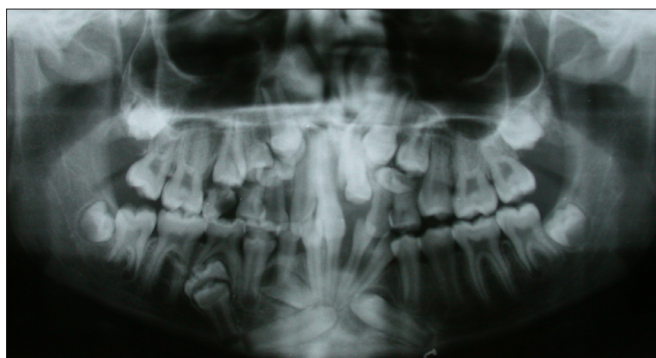


Figure 2. Radiographic features of case report.

Orthopantomography shows the persistence of the deciduous and included permanent teeth in the arch.

germectomy of supernumerary teeth at positions 1.5 and 1.6. Next, the surgical exposure and attachment of permanent teeth 1.3, 1.4 and 1.5 was performed. A buccal transalveolar surgical approach was utilised. In a third step, deciduous dental elements 6.3 and 6.4 were extracted, and a germectomy of supernumerary teeth at positions 2.5 and 2.6 was performed; the surgical exposure and attachment of permanent teeth 2.1, 2.2, 2.3 and 2.4 was performed.

For the surgical exposure in the upper arch, an intrasulcular trapezoid flap in the vestibular side and an envelope flap in the palatal side were created and then sutured using continuous suture with 3.0 silk thread. After the exposure and anchorage of several teeth, the patient required activation to be performed at the Complex Operative Unit of Orthodontics. We performed multibracket orthodontic treatment according

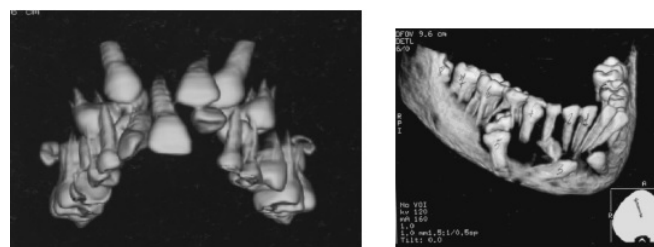


Figure 3. Clinical case.

A: 3D TC reconstruction of the upper arch. B: 3D TC reconstruction of the lower arch.

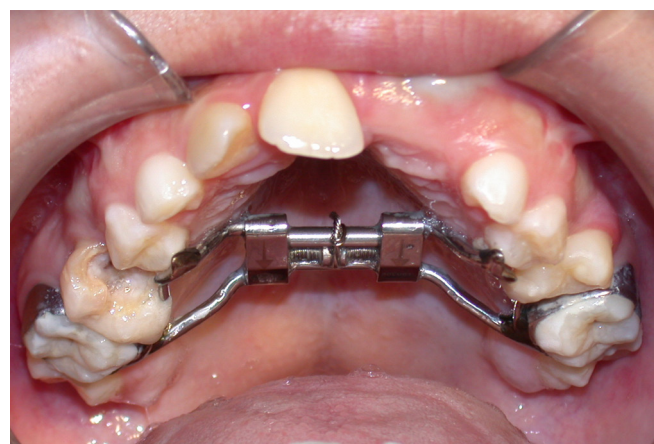


Figure 4. Rapid palate expander (RPE) applied for the expansion of the upper arch.

Table 3. Teeth removed and teeth repositioned in our case report.

Teeth removed	Teeth repositioned
Supernumerary teeth: localized at positions 1.5 - 1.6 - 2.5 - 2.6 - 4.5 and 4.6.	In the upper arch: 1.3 - 1.4 - 1.5 - 2.1 - 2.2 - 2.3 - 2.4.
Deciduous teeth: 5.3 - 5.4 - 5.5 - 6.3 - 6.4.	In the lower arch: 3.3 - 4.3 - 4.5.

to the technic of Mc Laughlin, Bennett and Trevisi (MBT). The MBT bracket system is based on light forces that eliminated the necessity of overcorrection, first and second order compensations. Furthermore this system is characterized by lace back ligatures in combination with reduced anti-tip and anti-rotation features placed less demand on anchorage control needs by minimizing the unwanted tooth movements in the anterior and posterior segments of the arch, right from the initial leveling and aligning phases of mechanotherapy [25]. The leveling and aligning phase with round archwires lasted 6 months and was followed by another 6 months of rectangular archwires. The archwire sequence with the MBT appliance was 0.014-inch, 0.016-inch and 0.019×0.025-inch Ni-Ti followed by 0.019×0.025-inch Stainless Steel. The patient completed the orthodontic treatment with elastic for intercuspitation and exhibited permanent teeth correctly positioned in the arch (Figures 6 and 7).

Discussion and Conclusions

The knowledge of the clinical features of CCD allows for the early planning of the procedures necessary for their resolution. The dental changes that need to be addressed include the failure of the deciduous dentition to exfoliate, the presence of supernumerary teeth and the failure of the permanent dentition to erupt. The goals of treatment are to improve the appearance

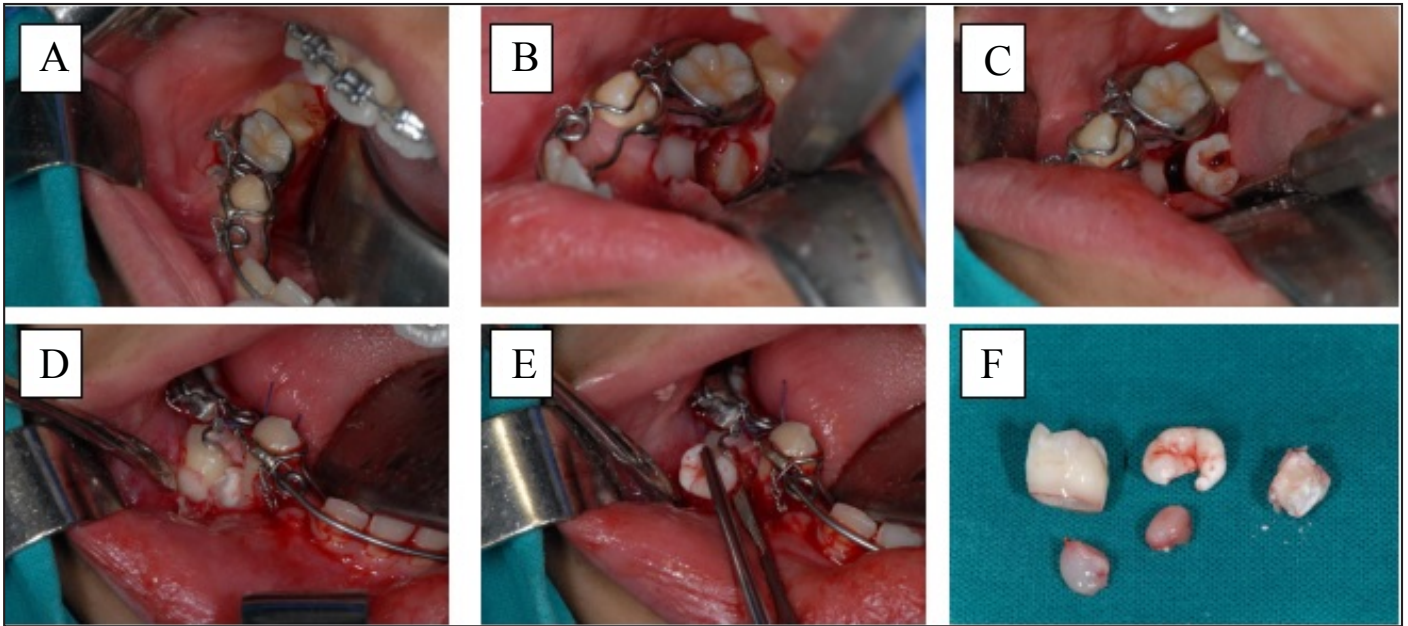


Figure 5: Steps of the clinical case; Germectomy in the region 4.5 - 4.6 of supernumerary elements.

A: Intraoral vision of the fourth quadrant. **B:** Surgical exposure on the lingual side, after executing an envelope flap. **C:** Execution of the germectomy on the lingual side. **D:** Surgical exposure on the vestibular side, with the execution of an envelope flap. **E:** Execution of the vestibular germectomy. **F:** Operatory finds.

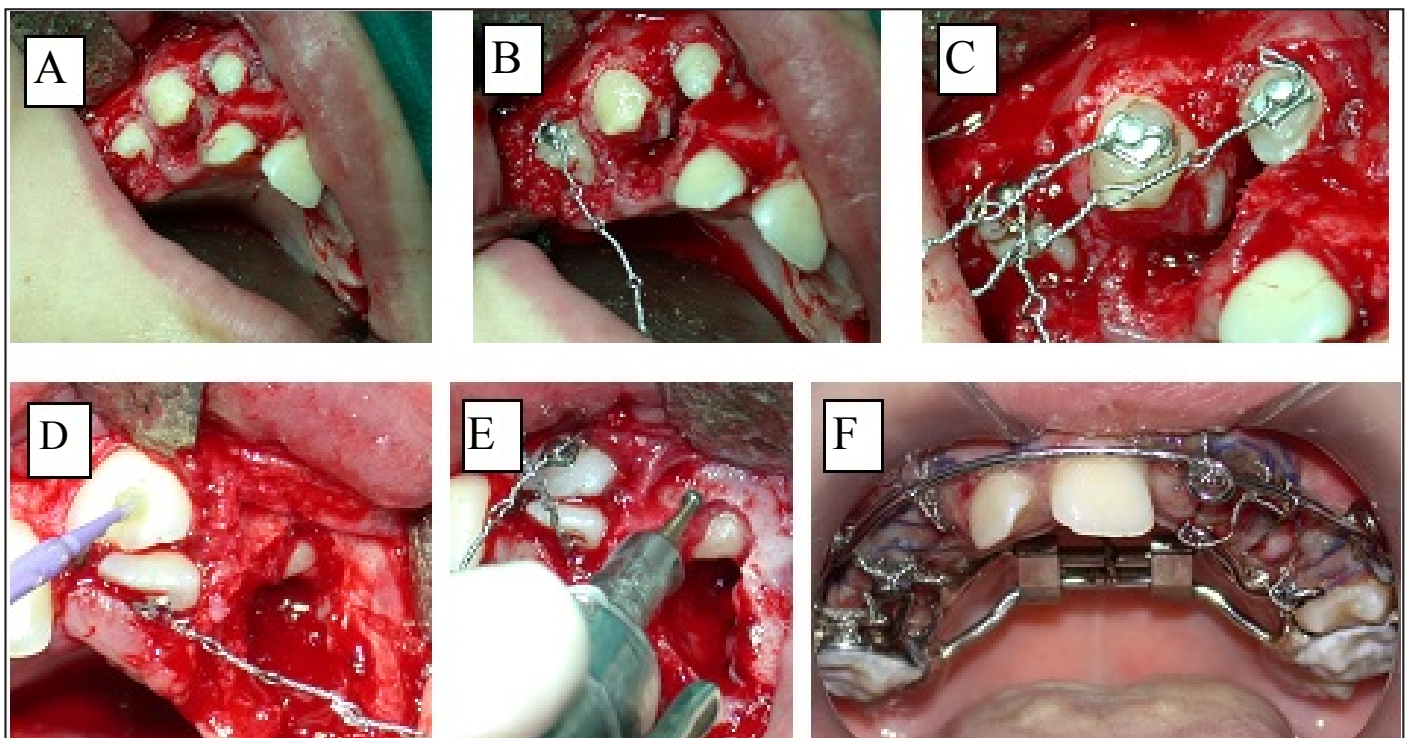


Figure 6: Steps of the clinical case; Surgical exposure and anchorage of permanent teeth in upper arch.

A: Surgical exposure on the vestibular side of the first quadrant, after executing an intrasulcular trapezoid flap. **B, C:** Anchorage of permanent teeth 1.3, 1.4 and 1.5. **D, E:** Surgical exposure and anchorage of permanent teeth 2.1, 2.2, 2.3 and 2.4. **F:** Continuous suture with 3.0 silk thread.

and to increase chewing effectiveness. These objectives can be achieved through prosthetic techniques employed with or without extraction; the removal of supernumerary teeth, followed by the surgical repositioning of permanent teeth; or a combination of orthodontic and surgical measures to actively drive the eruption and alignment of the included permanent teeth. Speech therapy may occasionally be required during periods of dental treatment. Children with CCD also should be monitored for upper airway obstruction, frequent apnoea

and sleep disorders because of the craniofacial involvement. Additionally, infections of the paranasal sinuses and middle ear require a prompt and aggressive treatment [26]. In CCD patients, repeated middle ear infections can cause hearing loss. In many CCD patients, the open fontanelles and cranial sutures will close and cranial remodelling is not usually required; however, if the defect in the cranial vault is significant, the head must be protected from injury with the use of special helmets, which are recommended for high-risk activities. In

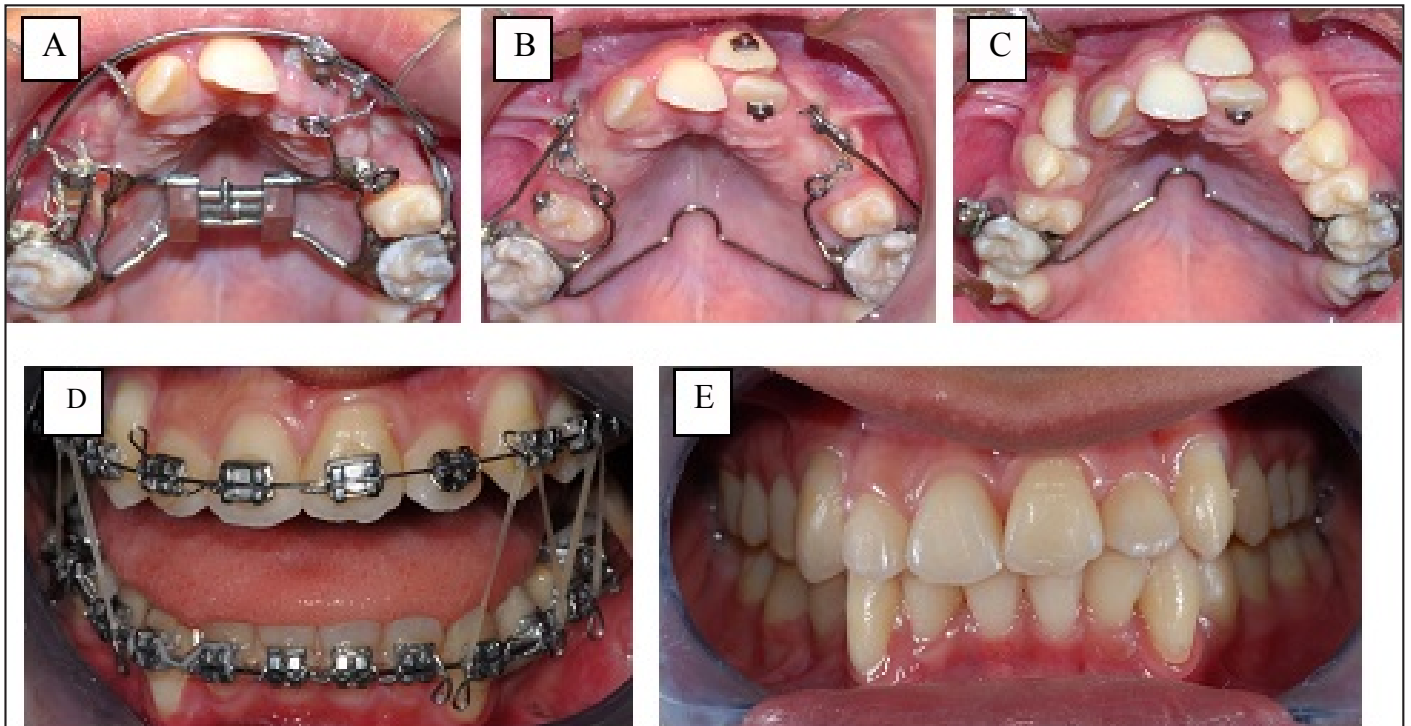


Figure 7: Orthodontic treatment required to actively drive tooth eruption and align the arches.

A, B, C: Control and Orthodontic activation after surgical exposure at 1, 9 and 18 months. **D:** Fixed orthodontic treatment. **E:** The patient completed the orthodontic treatment and exhibited permanent teeth correctly positioned in the arch. **Figure 7:** Orthodontic treatment required to actively drive tooth eruption and align the arches.

these cases, evaluations by a maxillofacial surgeon and a rehabilitation therapist are indicated. Preventive treatment for osteoporosis should be initiated at a young age and continued until bone mineral density peaks, which generally occurs in the second or third decade of life. If there are clinical signs of osteopaenia, such as an increase in the number of fractures, evaluation and treatment should be initiated early [15].

Dental alterations exhibited by CCD patients include the failure of the deciduous dentition to exfoliate, the presence of multiple supernumerary teeth and the failed or delayed eruption of the permanent dentition. Among the bones of the maxillofacial complex, the maxilla is underdeveloped with malformed paranasal sinuses; mandibular prognathism is also common. Knowledge of the clinical features of CCD enables the early planning of the procedures necessary for their resolution. Our experience suggests that early diagnosis is important not only for the choice of an appropriate treatment plan, but also to achieve satisfactory results. The goals of treatment are to improve both the aesthetic and functional aspects. These objectives can be achieved through the implementation of an appropriate multidisciplinary treatment plan that is characterised by a combination of the orthodontic and surgical measures needed to actively drive the eruption

and alignment of the included permanent teeth. The treated case reported the proper eruption of the permanent elements. Removal of the deciduous and supernumerary teeth eliminated the mechanical obstacles and enabled normal tooth eruption. The intervention plan is largely dependent on the chronological and dental age of the patients, which often do not coincide because of the altered sequence of tooth eruption associated with CCD. The orthodontic intervention in the literature seems to be reduced to the guided eruption of malpositioned and impacted teeth [12]. It is hoped a more complex multi-disciplinary approach, as reported [27,28]. By contrast to the literature, the data related to the presence of transverse and morphology radicular alterations emerged equally altered in the described case. Larger and more significant data in the future could be drawing definitive indications on these aspects of malocclusion. Early treatment is associated with better prognosis, but patients and parents should be informed about the long duration of treatment and the possibility of not being able to achieve the correct eruption of the teeth, especially in serious cases. In determining an appropriate treatment plan for a patient with CCD, the expected duration of treatment, the patient's age and the patient's attitude towards treatment are key considerations.

References

1. Brueton LA, Reeve A, Ellis R, Husband P, Thompson EM, Kingston HM. Apparent cleidocranial dysplasia associated with abnormalities of 8q22 in three individuals. *American Journal of Medical Genetics*. 1992; **43**: 612-618.
2. Dard M. Histology of alveolar bone and primary tooth roots in a case of cleidocranial dysplasia. *Bulletin du Groupèment*

International Pour La Recherche Scientifique En Stomatologie & Odontologie. 1993; **36**: 101-107.

3. Kalliala E, Taskinen PJ. Cleidocranial dysostosis: report of six typical cases and one atypical case. *Oral Surgery, Oral Medicine, Oral Pathology*. 1962; **14**: 808.

4. Marie P, Sainton P. Sur la dysostose cleido-cranienne hereditaire. *Revue Neurologique*. 1898; **6**: 835-838.

5. Golan I, Baumert U, Hrala BP, Müssig D. Dentomaxillofacial

- variability of cleidocranial dysplasia: Clinicoradiological presentation and systemic review. *Dentomaxillofacial Radiology*. 2003; **32**: 347-354.
6. Ramesar RS, Greenberg J, Martin R, Goliath R, Bardien S, Mundlos S, Beighton P. Mapping of the gene for cleidocranial dysplasia in the historical Cape Town (Arnold) kindred and evidence for locus homogeneity. *Journal of Medical Genetics*. 1996; **33**: 511-514.
 7. Jackson WP. Osteo-dental dysplasia (cleido-cranial dysostosis); the "Arnold head". *Acta Medica Scandinavica*. 1951; **139**: 292-307.
 8. Lo Muzio L, Tetè S, Mastrangelo F, Cazzolla AP, Lacaíta MG, Margaglione M, Campisi G. A novel mutation of gene CBFA1/RUNX2 in cleidocranial dysplasia. *Annals of Clinical and Laboratory Science*. 2007; **37**: 115-120.
 9. De Nguyen T, Turcotte JY. Cleidocranial dysplasia: review of literature and presentation of a case. *Journal of Canadian Dental Association*. 1994; **60**: 1073-1078.
 10. Goodman RM, Tadmor R, Zaritsky A, Becker SA. Evidence for an autosomal recessive form of cleidocranial dysostosis. *Clinical Genetics*. 1975; **8**: 20-29.
 11. Linde A, Goldberg M. Dentinogenesis. *Critical Reviews in Oral Biology and Medicine*. 1993; **4**: 679-728.
 12. Callea M, Fattori F, Yavuz I, Bertini E. A new phenotypic variant in cleidocranial dysplasia (CCD) associated with mutation c.391C>T of the RUNX2 gene. *BMJ Case Reports*. 2012; **2012**: bcr1220115422.
 13. Lian JB, Stein GS, Javed A, van Wijnen AJ, Stein JL, Montecino M, Hassan MQ, Gaur T, Lengner CJ, Young DW. Networks and hubs for the transcriptional control of osteoblastogenesis. *Reviews in Endocrine & Metabolic Disorders*. 2006; **7**: 1-16.
 14. Camilleri S, McDonald F. Runx2 and dental development. *European Journal of Oral Sciences*. 2006; **114**: 361-373.
 15. Mendoza-Londono R, Lee B. Cleidocranial Dysplasia. Bookshelf ID: NBK1513. 2006; [updated 2009 Jun 25].
 16. Takahashi K, Kiso H, Saito K, Togo Y, Tsukamoto H, Huang B, Bessho K. Feasibility of gene therapy for tooth regeneration by stimulation of a third dentition. In: *Gene Therapy-Tools and Potential Applications*. Rijeka, Croatia: InTech, 2013; pp. 727-744.
 17. Gosain AK, Conley SF, Marks S, Larson DL. Submucous cleft palate: diagnostic methods and outcomes of surgical treatment. *Plastic and Reconstructive Surgery*. 1996; **97**: 1497-1509.
 18. Cooper SC, Flaitz CM, Johnston DA, et al. A natural history of cleidocranial dysplasia. *American Journal of Medical Genetics*. 2001; **104**: 1-6.
 19. Segal N, Puterman M. Cleidocranial dysplasia - review with an emphasis on otological and audiological manifestations. *International Journal of Pediatric Otorhinolaryngology*. 2007; **71**: 523-526.
 20. Mohan VS, Desai RS, Patil MB. Cleidocranial dysplasia with bilateral polycystic ovarian disease and Mullerian abnormality of the uterus: a case report. *Journal of Oral Pathology and Medicine*. 2006; **35**: 311-313.
 21. Seow WK, Hertzberg J. Dental development and molar root length in children with cleidocranial dysplasia. *Pediatric Dentistry*. 1995; **17**: 101-105.
 22. Levander E, Malmgren O, Stenback K. Apical root resorption during orthodontic treatment of patients with multiple aplasia: a study of maxillary incisors. *European Journal of Orthodontics*. 1998; **20**: 427-434.
 23. Becker A, Lustmann J, Shteyer A. Cleidocranial dysplasia: Part 1—General principles of the orthodontic and surgical treatment modality. *American Journal of Orthodontics and Dentofacial Orthopedics*. 1997; **111**: 28-33.
 24. Ngan P, Hu AM, Fields HW Jr. Treatment of Class III problems begins with differential diagnosis of anterior crossbites. *Pediatric Dentistry*. 1997; **19**: 386-395.
 25. McLaughlin RP, Bennett JC, Trevisi HJ. *Systemised Orthodontic Treatment Mechanics*. Edinburgh: Mosby; 2001. pp. 101-102.
 26. Visosky AM, Johnson J, Bingea B, Gurney T, Lalwani AK. Otolaryngological manifestations of cleidocranial dysplasia, concentrating on audiological findings. *Laryngoscope*. 2003; **113**: 1508-1514.
 27. Martins RB1, de Souza RS, Giovani EM. Cleidocranial dysplasia: report of six clinical cases. *Special Care in Dentistry*. 2014; **34**: 144-150.
 28. Moyers E. *Standards of human occlusal development*. Volume 5: Craniofacial Growth Series, Ann Arbor: University of Michigan, Center for Human Growth and Development; 1976.