

Characteristic Cataract Associated with Idiopathic Hypoparathyroidism

Xuan Liao^{1,2#}, Xiuqi Huang^{1,2#}, Changjun Lan^{1,2*}, Jianhua Li^{1,2} and Qingqing Tan^{1,2}

¹Department of Ophthalmology, Affiliated Hospital of North Sichuan Medical College, Nanchong 637007, Sichuan Province, China

²Department of Ophthalmology and Optometry, North Sichuan Medical College, Nanchong 637007, Sichuan Province, China

#Contributed equally to this work.

*Corresponding author: Changjun Lan, Department of Ophthalmology, Affiliated Hospital of North Sichuan Medical College, Nanchong 637007, Sichuan Province, China, Tel: +86-817-2242112; Fax: +86-817-2222856; E-mail: eyelanchangjun@163.com

Received date: July 24, 2016; Accepted date: August 16, 2016; Published date: August 20, 2016

Copyright: © 2016 Liao X, et al. This is an open-access article distributed under the terms of the Creative Commons Attribution License, which permits unrestricted use, distribution, and reproduction in any medium, provided the original author and source are credited.

Abstract

Purpose: To report a case of profoundly characteristic cataract associated with idiopathic hypoparathyroidism.

Methods: We described a 37-year-old male presented to our hospital with bilateral vision loss for 3 years. Past medical history included recurring tetany and convulsion, regarded as grand mal epilepsy about 9 years prior to diagnosis of hypoparathyroidism and corresponding administration. Ophthalmic signs of typically lenticular changes in both eyes, combined with laboratory evidence of hypocalcemia and significantly decreased parathyroid hormone (PTH) level, led to a diagnosis of hypoparathyroid cataract. The patient subsequently underwent unilateral phacoemulsification and multifocal intraocular lens implantation surgery.

Results: At the first postoperative day, the best-corrected distance visual acuity (BCDVA) improved from 0.5 logMAR preoperatively to 0.0 logMAR; the uncorrected distance visual acuity (UCDVA) was 0.1 logMAR and the uncorrected near visual acuity (UCNVA) at 40 cm was 0.1 logMAR. The visual acuity remained stable during 1 year of follow-up.

Conclusions: These observations suggest that cataracts associated with idiopathic hypoparathyroidism possess characteristic manifestations, and long standing severe hypoparathyroidism and hypocalcemia increase the risk of cataract. In addition, the relevant medical history and laboratory examinations are important for the diagnosis of such cases. Surgically removed the cataract with serious visual impairment is advised.

Keywords: Cataract; Idiopathic hypoparathyroidism; Hypocalcemia

Introduction

Idiopathic hypoparathyroidism is an uncommon condition characterized by spontaneously lowered synthesis and/or secretion of parathyroid hormone (PTH), which results in profound hypocalcemia and hyperphosphatemia [1,2]. This is conventionally interpreted as a result of prevention of calcium reabsorption in renal tubulus and bone matrix, as well as insufficiency of the synthesis of 1,25-dihydroxyvitamin D₃ [1,25(OH)₂D₃] from its inactive precursor 25-hydroxyvitamin D. It may lead to various general and local manifestations, such as the neuromuscular irritability and mental changes, and among them cataract was relatively rare reported. It is the purpose of this paper to delineate and discuss characteristic lenticular changes from bilateral cataracts secondary to idiopathic hypoparathyroidism, and surgical outcome for cataract phacoemulsification with intraocular lens implantation.

Case Report

A 37-year old male was admitted to the department of ophthalmology of medical college hospital because of progressive, painless vision loss in both eyes for a period of three years. Patients' previous medical history was notable for recurring tetany and convulsion resembling grand mal epilepsy. He was well until 11 years

old when he began to have an epileptiform seizure lasting for mere minutes and self-terminating. Since then, he had intermittently been suffered from the conditions and been treated with sedatives during at least nine years period. In his 20 years old, he was diagnosed as hypoparathyroidism and treated with calcium supplement, and since then the frequency and intensity of the attacks were gradually decreased. So far, he has been free from attacks for two years by maintaining oral administration of alfacalcidol and calcium plus vitamin D₃ supplementation. The patient has not undergone neck or thyroid surgery and irradiation, as well as was free from hypertension or diabetes or any other systemic disease. Other past history and family history was unremarkable.

On clinical examination patient was found to be well-built and well-developed, with no physical abnormalities. Ophthalmic examination revealed the uncorrected and best-corrected distance visual acuity (UCDVA and BCDVA, respectively) 0.5 and 0.5 logMAR (cylinder -1.25 × 165) in right eye, 0.2 and 0.1 logMAR (cylinder -0.50 × 180) in left eye. At the time of the examination, bilateral symmetric cataract was noted with the irregularly herringbone opacities in the central region and radial spoke-like opacities in the peripheral region, respectively (Figure 1). The mean cell density of the corneal endothelial cell layer was 2513.7 cells/mm² in right eye and 2623.4 cells/mm² in left eye. The intraocular pressure with non-contact tonometry in the both eyes was 16 mmHg. Dilated fundus examination did not reveal any abnormality in the both eyes. Also, there was no obvious pathology

in posterior segment by B-Scan ultrasonography, as well as in the macular and optic disk region by optical coherence tomography.

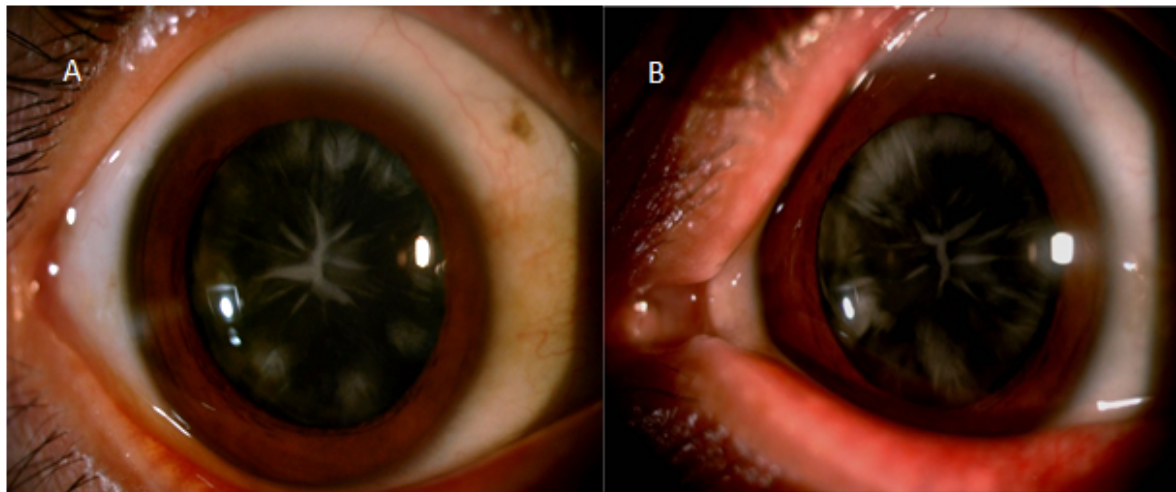


Figure 1: Symmetrically lenticular opacities located in peripheral and central regions. (A) Right eye. (B) Left eye.

Biochemical analyses demonstrated significantly low parathyroid hormone (PTH 3.04 pg/ml, reference 15.0-65.0 pg/ml), but slightly low serum calcium (Ca 2.00 mmol/L, reference 2.08-2.60 mmol/L) and a normal inorganic phosphorus (IP 1.43 mmol/L, reference 0.90-1.70 mmol/L) levels. The patient appeared clinically euthyroid with normal thyroid stimulating hormone (TSH 1.80 mUI/ml, reference 0.30-4.94), free T3 (FT3 4.60 pmol/L, reference 2.23-6.47), free T4 (FT4 13.29 pmol/L, reference 9.01-24.01) levels. Routine liver and kidney function tests all gave almost normal results.

Electrocardiogram reported sinus rhythm with arrhythmia. Bone mineral density (BMD) examination showed a general abnormal decrease in ulnar radial bone density (BMD 0.379 g/cm², T-Score -3.4 SD, Z-Score -4.4 SD). In presence of characteristic lenticular opacities, significantly decreased PTH level and relatively mild hypocalcemia, combined with medical history information, patient was labeled as a case of cataract associated with idiopathic hypoparathyroidism.

After obtaining informed consent from the patient, the cataract was removed with phacoemulsification through a clear corneal incision, and an Alcon AcrySof IQ ReSTOR SN6AD1 +23.0 D multifocal intraocular lens was implanted in right eye with no complication during the surgery (Figure 2). A limbal relaxing incision was performed to treat astigmatism. At postoperative first day, the UCDVA and BCDVA was 0.1 and 0.0 logMAR (cylinder -0.50 × 15), and uncorrected near visual acuity (UCNVA) at 40 cm was 0.1 logMAR, respectively. During postoperative 1 year follow-up, the patient maintained stable visual acuity.

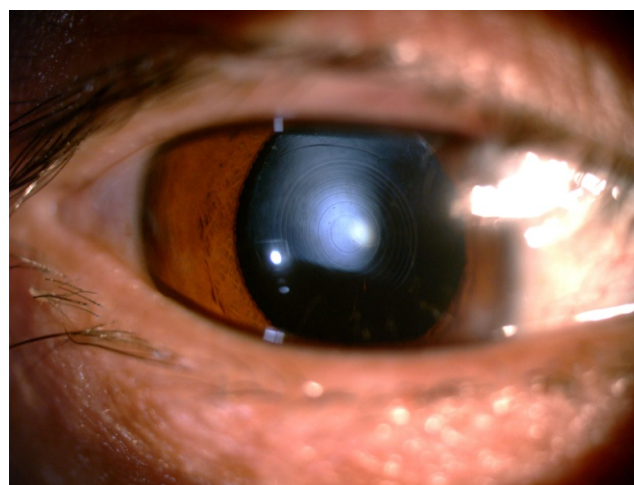


Figure 2: Multifocal intraocular lens implanted in right eye after cataract phacoemulsification.

Discussion

Hypoparathyroid cataract is delineated as characteristic lenticular opacities caused by hypoparathyroidism as deficient PTH action or secretion, due to secondary and primary etiologies [3]. In clinical practice, secondary hypoparathyroidism was observed in approximately 75 percent of patients, while the remainder was attributed to autoimmune, genetic or idiopathic etiologies [4,5]. Thus, idiopathic hypoparathyroidism and resulting hypoparathyroid cataract are relatively rare, where the underlying etiologies and pathogenesis remain to be clarified. Metabolic disturbance, chronic hypocalcemia and hyperphosphatemia, calcitonin reduction, vitamin D insufficient can be responsible for cataract formation [6,7].

Typically, the opacities are located in the subcapsular cortical region at a uniform level and separated from the anterior and posterior capsule by a thin layer of transparent cortex. Lenticular changes originate initially as multiple fine punctuations or vacuoles, and then are replaced by irregular linear or laminated white opacities. Further, cortical opacities have a radial or spoke-like appearance along the lens fibers, pointing to the center of the lens [8]. Central opacities are uncommon type observed, situated in the embryonal nucleus and sutures as the distinctively irregular herringbone. It has been suggested to be congenital [9]. Comparatively, cataracts occurring secondary to surgical hypoparathyroidism or chronic renal failure evolve rapidly, and the progression may be halted by correction of hypocalcemia. Whereas, cataracts associated with primary hypoparathyroidism develop slowly and vision do not begin to deteriorate until past middle age. In general, we should also take into account the manifestation of lenticular opacity reflecting not only the onset age but also the individual metabolic conditions.

In the idiopathic form, the cataract is mostly cortical. But remarkably, as demonstrated in our patient, the lenticular opacities presented at not only peripheral cortex as radial spoke-like appearance, but also central embryonal nucleus or sutures as herringbone shape. It reminds us that cataract formation occurs recently and previously-suggests that lenticular changes can occur over long periods of time. Certain factors like calcium level may have been extremely aberrant during that period. In our patient, onset of neuromuscular symptoms was at 11 years of age, but lenticular changes might be date from embryonal or fetal period. Furthermore, convulsion and tetany had occurred 9 years before hypocalcaemia were identified; the patient had an excellent response to treatment with calcium and vitamin D. Retrospectively, these seemed to become evident again that contributed to classical establishment the diagnosis of hypoparathyroid cataract, and long standing severe hypoparathyroidism led to increase the risk of cataract.

To conclude, we would like to emphasize that early recognition and intervention is essential to prevent complications from

hypoparathyroidism, and ophthalmologists should keep aware of metabolic abnormalities while evaluating a patient with characteristic cataracts.

Acknowledgments

We thank the patient for his cooperation and his consent to the use of both information about his treatment and the photographs in this article. This work is supported by Projects of Sichuan Education Department, China (No.14ZA0183); Scientific Research Starting Foundation of North Sichuan Medical College, China (No. CBY14-QD-05).

References

1. Shoback DM, Bilezikian JP, Costa AG, Dempster D, Dralle H, et al. (2016) Presentation of hypoparathyroidism: etiologies and clinical features. *J Clin Endocrinol Metab* 101: 2300-2312.
2. Bilezikian JP, Khan A, Potts JT, Brandi ML, Clarke BL, et al. (2011) Hypoparathyroidism in the adult: Epidemiology, diagnosis, pathophysiology, target-organ involvement, treatment, and challenges for future research. *J Bone Miner Res* 26: 2317-2337.
3. Hobbs HE (2013) *Principles of ophthalmology*: Elsevier.
4. Shoback D (2008) Hypoparathyroidism. *N Engl J Med* 359: 391-403.
5. De Sanctis V, Soliman A, Fiscina B (2012) Hypoparathyroidism: from diagnosis to treatment. *Curr Opin Endocrinol Diabetes Obes* 19: 435-442.
6. Stein R, Godel V (1980) Hypocalcemic cataract. *J Pediatr Ophthalmol Strabismus* 17: 159-161.
7. Brown CJ, Akaichi F (2015) Vitamin D deficiency and posterior subcapsular cataract. *Clin ophthalmol* 9: 1093-1098.
8. Philipson B, Angelin B, Christensson T, Einarsson K, Leijb B (1978) Hypocalcaemia with zonular cataract due to idiopathic hypoparathyroidism. *Acta Medica Scandinavica* 203: 223-226.
9. Pohjola S (1962) Ocular manifestations of idiopathic hypoparathyroidism. *Acta Ophthalmol* 40: 255-265.