

## Cervical Muscular Metastasis from Squamous Lung Cancer

Min Liu<sup>1</sup>, Bin Liu<sup>2</sup>, Bailong Liu<sup>1\*</sup> and Lihua Dong<sup>1\*</sup>

<sup>1</sup>Department of Radiation Oncology, the First Hospital, Jilin University, 71 Xinmin Street, Changchun, 130021, China

<sup>2</sup>Department of Hand Surgery, the First Hospital, Jilin University, 71 Xinmin Street, Changchun, 130021, China

\*Corresponding authors: Bailong Liu, Department of Radiation Oncology, the First Hospital, Jilin University, 71 Xinmin Street, Changchun, 130021, Peoples Republic of China, Tel: 8643188782468; E-mail: [bailong3385@163.com](mailto:bailong3385@163.com)

Lihua Dong, Department of Radiation Oncology, the First Hospital, Jilin University, 71 Xinmin Street, Changchun, 130021, Peoples Republic of China, Tel: 86-431-88782468; E-mail: [lijie200461@126.com](mailto:lijie200461@126.com)

Received date: August 31, 2014, Accepted date: September 19, 2014, Published date: September 26, 2014

Copyright: © 2014 Liu M, et al. This is an open-access article distributed under the terms of the Creative Commons Attribution License, which permits unrestricted use, distribution, and reproduction in any medium, provided the original author and source are credited.

**Keywords:** Muscular metastasis; Cervical; Squamous lung cancer

### Description

A 57-year-old man presented in January, 2014 with progressive pain of right neck for 2 weeks. He had a 5-month history of squamous lung cancer. After treatment, the thoracic lesion had a nearly complete remission response. Cervical MRI revealed a huge mass located in the right region near the 3<sup>rd</sup>-7<sup>th</sup> cervical vertebrae consistent with erector spinae metastasis (Figure 1a and 1b). The pathologic re-evaluation of the pulmonary primary tumor showed no EGFR gene mutation. Palliative radiotherapy of 60Gy/30f was performed to the muscular metastasis, concurrently with chemotherapy. We attained a stable disease response when he finished the cervical irradiation (Figure 1c) and 3 months after irradiation (Figure 1d). Pain was greatly relieved.

Muscular metastasis from non small cell lung cancer is rare [1,2]. To our knowledge, this is the first report of cervical erector spinae metastasis from squamous lung cancer. Such rare metastasis should be kept in mind.

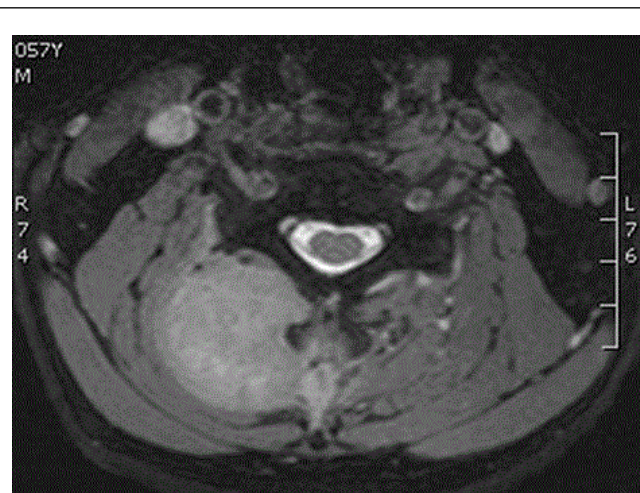


Figure 1b: Axial image of cervical MRI before radiotherapy

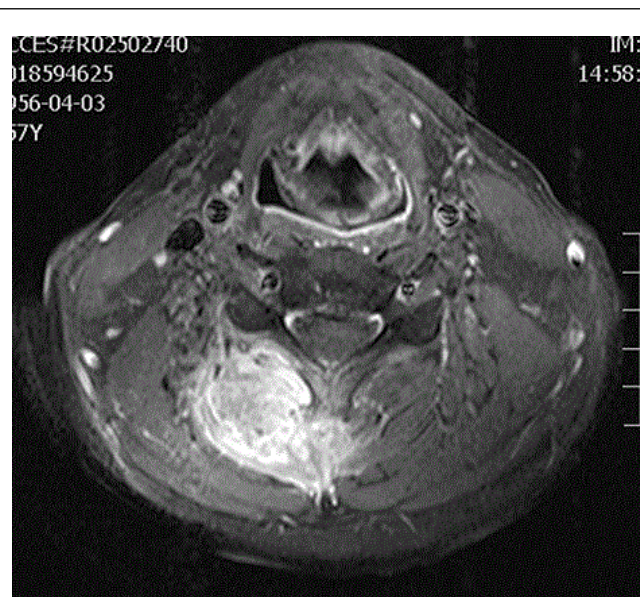


Figure 1c: Axial image of cervical MRI when the patient finished radiotherapy

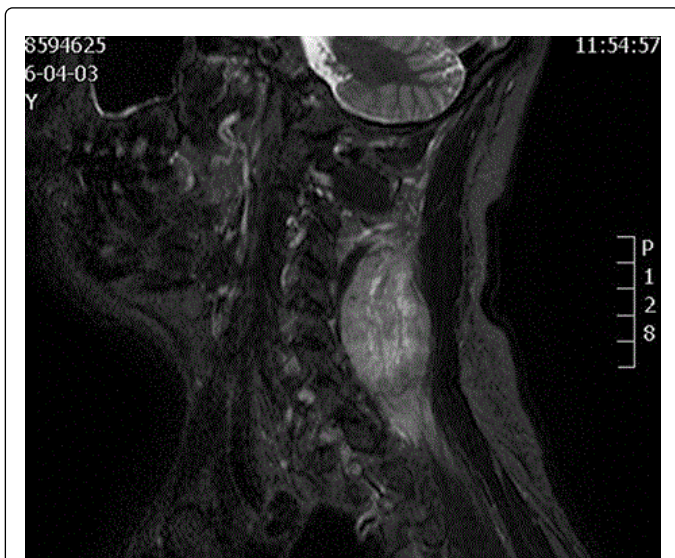
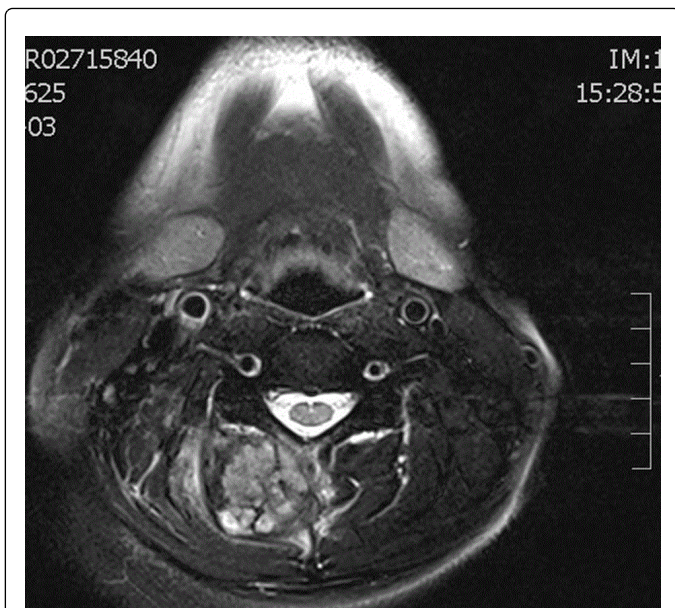


Figure 1a: Sagittal image of cervical MRI before radiotherapy



**Figure 1d:** Axial image of cervical MRI of 3 months after irradiation

## References

1. Tezcan Y, Koc M (2014) Muscle metastasis from non-small cell lung cancer: two cases and literature review. *Acta Clin Belg* 69: 302-304.
2. Pop D, Nadeemy AS, Venissac N, Guiraudet P, Otto J, et al. (2009) Skeletal muscle metastasis from non-small cell lung cancer. *J Thorac Oncol* 4: 1236-1241.