

## Categorization and Surgical Techniques of Weak Zonule Based on Findings at Capsulorhexis during Cataract Surgery

Saori Yaguchi<sup>1\*</sup>, Shigeo Yaguchi<sup>2,3</sup>, Yasuhiko Asano<sup>2</sup>, Sayuri Aoki<sup>2</sup>, Misuzu Hamakawa<sup>2</sup>, Tadahiko Kozawa<sup>3</sup>, Kazuno Negishi<sup>1</sup> and Kazuo Tsubota<sup>1</sup>

<sup>1</sup>Department of Ophthalmology, Keio University School of Medicine, Tokyo, Japan

<sup>2</sup>Department of Ophthalmology, School of Medicine, Showa University, Fujigaoka Hospital, Yokohama, Japan

<sup>3</sup>Kozawa Eye Hospital and Diabetes Center, Mito, Japan

\*Corresponding author: Shigeo Yaguchi, MD, PhD, Kozawa Eye Hospital and Diabetes Center, 246, Yoshizawa-Cho, Mito-City, Ibaraki-Pref. 310-0845, Japan, Tel: +81-29-246-2111; Fax: +81-29-304-5111; E-mail: [yaguchis@hotmail.co.jp](mailto:yaguchis@hotmail.co.jp), [yaguchi@kozawa-ganka.or.jp](mailto:yaguchi@kozawa-ganka.or.jp)

Received date: Dec 22, 2014, Accepted date: Mar 14, 2015, Published date: Mar 16, 2015

Copyright: © 2015 Yaguchi S, et al. This is an open-access article distributed under the terms of the Creative Commons Attribution License, which permits unrestricted use, distribution, and reproduction in any medium, provided the original author and source are credited.

### Abstract

**Purpose:** We categorize weak zonule during capsulorhexis.

**Design:** Retrospective interventional case series.

**Methods:** The study examined 5447 consecutive eyes of 3527 cases that underwent phacoemulsification (PEA) and intraocular lens (IOL) implantation between March 2006 and March 2014 at Showa University Fujigaoka Hospital, Kanagawa, Japan. Weak zonule was categorized based on findings at capsulorhexis and difficulty in performing continuous curvilinear capsulorhexis (CCC). The categorization definitions were as follows: (1) Group N (normal) with no or slight lens movement at the start of the CCC and no difficulty in performing CCC, (2) Group W (weak) with moderate lens movement frequently accompanied by fold formation during CCC and some difficulty in performing CCC, (3) Group VW (very weak) because of severe lens movement and difficulties with the initial puncture, CCC can be performed with the aid of a highly retentive and cohesive ophthalmic viscoelastic device (OVD; Healon 5<sup>®</sup>), and (4) Group EW (extremely weak) with zonular deficiency in addition to the Group VW criteria and accounted for the cases of severe phacodonesis, lens subluxation, lens luxation into the anterior chamber, and dropped nucleus into the vitreous cavity that could be categorized preoperatively. We examined capsule stabilization device use during PEA, surgical lens removal, and IOL fixation in each group.

**Results:** We defined 5098 eyes as Group N, 251 eyes as Group W, 55 eyes as Group VW, and 43 eyes as Group EW. As the zonule became weak, the use of the capsule stabilization device increased in PEA and intracapsular cataract extraction, and scleral suture fixation of IOL increased. Pars plana vitrectomy for lens removal was performed in 5 eyes (11.63%) categorized as Group EW.

**Conclusions:** The categorization of weak zonule at CCC may be useful for selecting an appropriate capsule stabilization device and procedure during cataract surgery.

**Keywords:** Cataract surgery; Weak zonule; Capsule stabilization device

### Introduction

Continuous curvilinear capsulorhexis (CCC), phacoemulsification and aspiration (PEA), and endocapsular posterior chamber intraocular lens (IOL) fixation are the standard procedures for cataract surgery. In cases with weak or missing zonules, the risks of intraoperative and postoperative complications are increased. When the cataract surgeon encounters zonular weakness, additional management is required, which may include an adjunctive capsule stabilization device and changes in the surgical procedure.

Appropriate use of an adjunct capsule stabilization device can improve the safety and outcome of procedures performed in patients with zonular instability. In 1991, Hara et al. introduced the concept of the equator ring, which was the prototype for the capsular tension ring (CTR) [1]. Since its introduction, several types of endocapsular

support devices have been developed, and iris retractors have been used for capsular stabilization in cases of zonular compromise [2-4]. We recently developed the T-shaped capsular hook (capsule expander<sup>TM</sup>; CE, Handaya, Japan), and have reported its usefulness during PEA in cases with weak zonules [5].

Cases of severe zonular compromise require intracapsular cataract extraction (ICCE), pars plana vitrectomy (PPV), or scleral suture fixation of IOL. Intraoperative changes in the surgical procedure require emergency preparation of additional surgical devices.

It would be useful for a cataract surgeon to be able to rely on predictive factors that could indicate zonular weakness because this would help with selecting an appropriate surgical device and approach. However, zonular weakness is difficult to detect, except in cases with preoperative subluxation and phacodonesis.

The findings during capsulorhexis, such as lens movement at the beginning of the rhexis and extension of the tear, can occasionally indicate zonular weakness [6].

Therefore, the aim of this study was to categorize zonular weakness into four groups according to the findings at capsulorhexis and difficulty in performing CCC, and to describe the surgical procedure for each of these groups.

## Materials and Methods

This retrospective interventional study included 5447 eyes in 3527 consecutive cases that underwent planned PEA and IOL (acrylic) implantation between March 2006 and March 2014 at Fujigaoka Hospital. The mean age of the patients was  $73.0 \pm 10.7$  years (13-103 years). The predisposing factors for weak zonules were pseudoexfoliation syndrome (233 eyes, 4.28%), history of laser iridotomy (186 eyes, 3.41%), history of endophthalmic surgery (PPV, trabeculectomy, and scleral buckling; 61 eyes, 1.12%), atopic dermatitis (59 eyes, 1.08%), pigmentary degeneration of the retina (16 eyes, 0.29%), history of blunt trauma (13 eyes, 0.24%), and Marfan's syndrome (2 eyes, 0.04%).

This study followed the tenets of the Declaration of Helsinki. All subjects provided written informed consent after receiving an explanation of the nature and possible consequences of the study. The Institutional Review Board of Showa University retrospectively approved this study (No. 2012121).

## Surgical procedure

The cataract surgeries were performed by the same surgeon (S.Y.) under topical anesthesia. After creating clear corneal and stab incisions, CCC of the anterior lens capsule was created using a 23-gauge needle and balanced salt solution (BSS) [7]. The 23-gauge needle was first bent at a right angle and then connected to the irrigation hand piece. The remaining procedure began by first using the needle to puncture the capsule in the periphery. Next to extend the tear, the peripheral margin was gently pushed with the needle tip until it was parallel to the edge of the pupil. The needle was then tilted to 45 degrees to properly catch and scratch the capsule.

Emulsification of the lens nucleus and aspiration of the lens cortex were performed with downslope sculpting [8] using a PEA machine (CV30000, NIDEK CO., LTD., Aichi, Japan). An acrylic foldable IOL was implanted after the capsular bag was filled with an ophthalmic viscoelastic device (OVD).

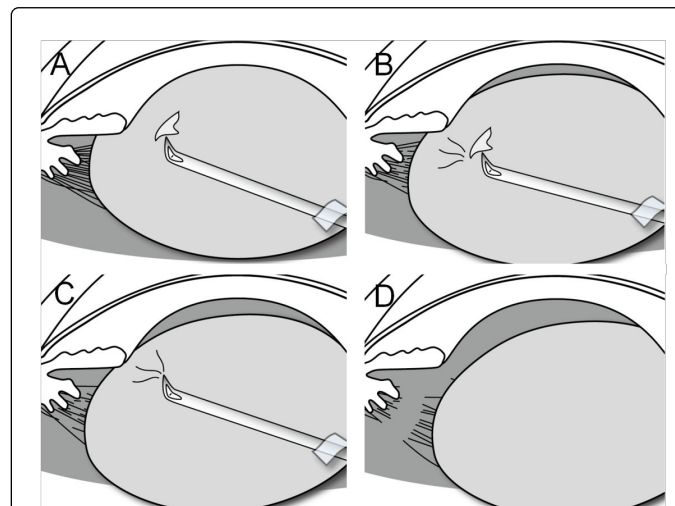
In addition, we used highly retentive and cohesive OVD (Healon 5<sup>®</sup> Abbot Medical Optics Inc., Illinois, USA) and a capsule stabilization device in cases with zonular weakness. When CCC could not be performed because of severe lens movement, Healon5<sup>®</sup> was injected into the anterior chamber.

An alternative and additional surgical procedure was performed when the conventional PEA and IOL implantation could not be performed or completed. The surgical procedure was converted to an ICCE in cases with an anterior capsule tear, a rent in the posterior capsular, an incomplete CCC, and a severely subluxated capsular bag that was impossible to recenter. A scleral suture fixation of IOL was performed when we determined that IOL could not be fixed in an unstable capsular bag. After completing PEA with the aid of a capsule stabilization device, we removed the capsule with forceps. This procedure was followed by transscleral fixation of IOL. If vitreous prolapsed into the anterior chamber at the beginning of the procedure, we attempted to sequester the vitreous or push it back with Healon 5<sup>®</sup>. A planned ICCE and PPV were performed if an eye showed extensive

zonule weakness preoperatively, such as with an obvious lens subluxation or dropped nucleus into the vitreous cavity.

## Categorization of weak zonule

The weak zonule was categorized based on findings at capsulorhexis and difficulty in performing CCC (Figure 1). The categorization was based on the findings that the needle movement during CCC was accompanied with lens movement in cases with weak zonules. Furthermore, the movement increased as the zonular weakness became more severe, which made the CCC manipulation more difficult. Group N was defined as normal zonule, with no or slight lens movement coincident with the needle movement at the start of CCC; CCC could be performed without any difficulty. Group W was defined as weak zonule, with moderate lens movement frequently accompanied by fold formation around the needle tip during CCC; CCC could be performed under BSS, although there was some difficulty in puncturing the anterior capsule and extending the tear. Group VW was defined as very weak zonule, puncture was impossible because of severe lens movement under BSS, including slight phacodonesis; the needle movement was completely accompanied with lens movement. Group EW was defined as extremely weak zonule, including Group VW criteria along with severe zonular deficiency and accounted for the cases of severe phacodonesis, lens subluxation, lens luxation into the anterior chamber, and dropped nucleus into the vitreous cavity that could be categorized preoperatively. Otherwise, Group VW would have to be categorized intraoperatively. In both Group VW and EW, CCC could still be performed with a Healon<sup>®</sup>5 injection.



**Figure 1:** Categorization of weak zonule. Zonular weakness was categorized based on findings at capsulorhexis and difficulty in performing continuous curvilinear capsulorhexis (CCC). **A:** Group N (normal). No or slight lens movement was observed at the beginning of CCC. CCC could be performed without any difficulty. **B:** Group W (weak). Moderate lens movement was frequently accompanied by fold formation around the needle tip during CCC. CCC could be performed, although there was some difficulty. **C:** Group VW (very weak). Puncture was impossible due to severe lens movement under BSS. CCC could be performed with the aid of Healon 5<sup>®</sup>. **D:** Group EW (extremely weak). Severe zonular deficiency in addition to the Group VW criteria.

The categorization definition was acknowledged at the Fujigaoka Hospital. The categorization of each surgery was determined shortly after the procedure by the single surgeon (S.Y.) and one of the six experienced ophthalmologists, who worked at Fujigaoka Hospital and assisted during the operations.

## Results

### Categorization of weak zonule

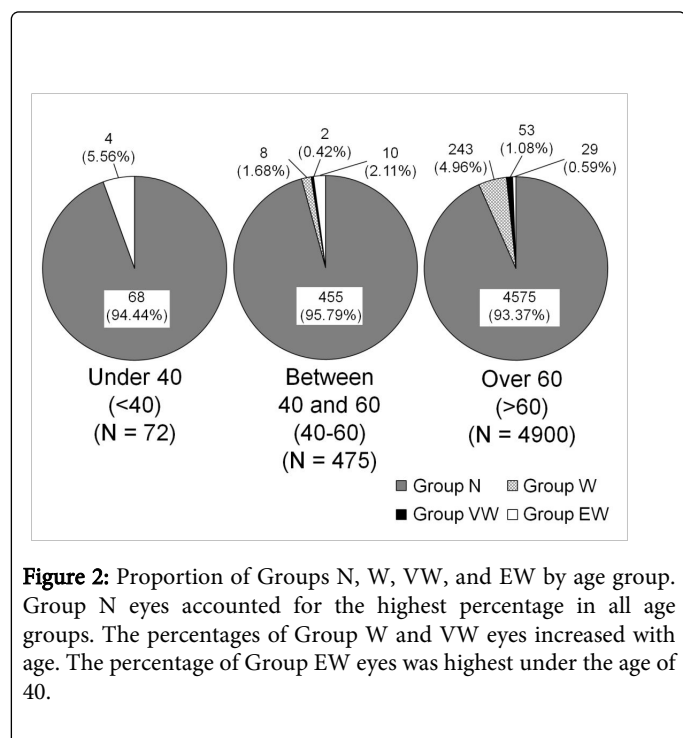
The categorization of weak zonule among the 5447 eyes is shown in Table 1.

Group	N (%)
Group N (normal)	5098 (93.59%)
Group W (weak)	251 (4.61%)
Group VW (very weak)	55 (1.01%)
Group EW (extremely weak)	43 (0.79%)

**Table 1:** Categorization of weak zonule.

### Proportion of Groups N, W, VW, and EW by age group

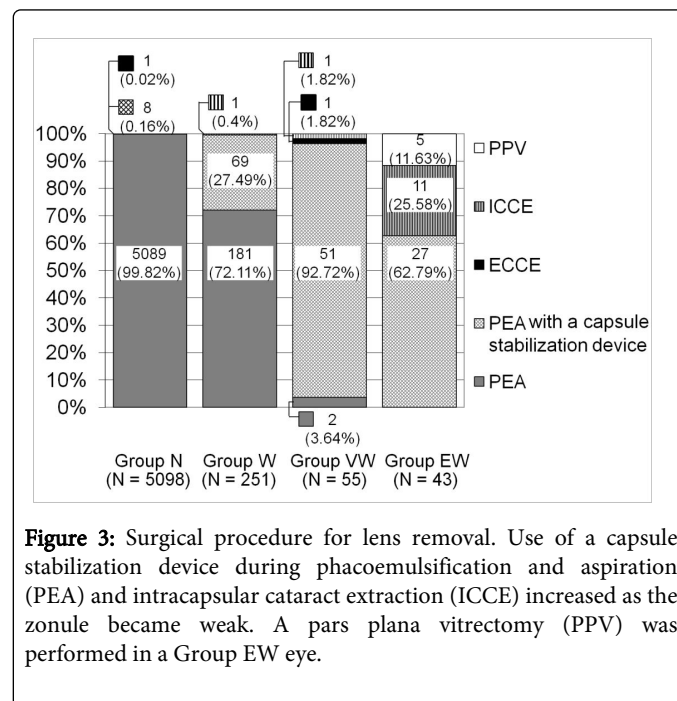
We examined the distribution of the four weak zonule groups among age groups, which were under 40 (<40), between 40 and 60 (40-60), and over 60 (>60) (Figure 2). Overall, Group N accounted for the highest percentage in all age groups. The percentage with Group W and Group VW criteria increased with age. In contrast, the percentage of Group EW was highest in the <40 group. Cases that were assigned Group EW in the <40 group included patients with Marfan's syndrome, a history of blunt trauma, or a history of atopic dermatitis.



**Figure 2:** Proportion of Groups N, W, VW, and EW by age group. Group N eyes accounted for the highest percentage in all age groups. The percentages of Group W and VW eyes increased with age. The percentage of Group EW eyes was highest under the age of 40.

### Surgical procedure for lens removal

The specific procedures for lens removal included standard PEA, PEA with a capsule stabilization device, extracapsular cataract extraction (ECCE), ICCE, and PPV. The procedure chosen for lens removal was determined by the degree of lens sclerosis and zonule fragility. The number and percentage of eyes in each group are shown for each of these procedures in Figure 3. The use of a capsule stabilization device during PEA and ICCE increased as the zonule became weak. PPV was performed in 5 eyes (11.63%) with a Group EW.



**Figure 3:** Surgical procedure for lens removal. Use of a capsule stabilization device during phacoemulsification and aspiration (PEA) and intracapsular cataract extraction (ICCE) increased as the zonule became weak. A pars plana vitrectomy (PPV) was performed in a Group EW eye.

### Capsule stabilization device use

Standard PEA required a capsule stabilization device when zonular dehiscence was present. We used a CE, an iris retractor, and a CTR. Of the 5447 eyes examined, 158 (2.90%) required a capsule stabilization device. The type of capsule stabilization device used is indicated in Table 2.

Capsule stabilization device	N (%)
CE	147 (93.04%)
Iris retractor	6 (3.80%)
CTR	2 (1.26%)
CTR in combination with CE	3 (1.90%)

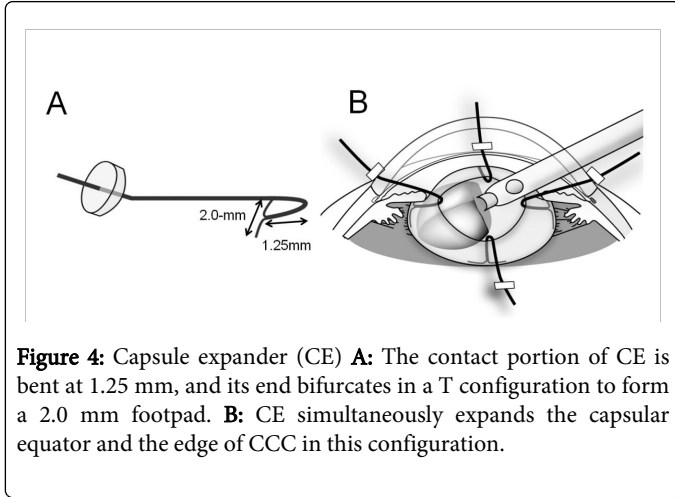
CE: Capsule Expander; CTR: Capsular Tension Ring

**Table 2:** Capsule stabilization device use.

### PEA with the aid of a CE

We had developed a CE to preserve the lens capsule integrity during PEA procedures performed on eyes with weak zonules [5]. The CE is flexible, 10 mm long, and fashioned from 5-0 polypropylene. The

contact portion is bent at 1.25 mm, with an end bifurcating to form a 2.0 mm T-shaped footpad. This footpad helps to simultaneously expand the capsular equator and the edge of CCC (Figure 4).



**Figure 4:** Capsule expander (CE) **A:** The contact portion of CE is bent at 1.25 mm, and its end bifurcates in a T configuration to form a 2.0 mm footpad. **B:** CE simultaneously expands the capsular equator and the edge of CCC in this configuration.

Thus, the CE expands and stabilizes the capsular bag to facilitate a safe PEA in an eye with weak zonules. Completed PEA and conversions to ICCE in cases of PEA with CE is shown in Table 3. A safe PEA was achieved with the aid of a CE, which indicated there was no need to convert to the ICCE procedure in 144 eyes (97.96%). We next examined the posterior capsule rupture (PCR) rate for each group during PEA when this procedure was performed with and without a CE (Table 4).

Group Use of CE during PEA (N)	Completed PEA with CE N (%)	Converted to ICCE N (%)
Group N (N=6)	6 (100%)	0 (0%)
Group W (N=62)	62 (100%)	0 (0%)
Group VW (N=49)	49 (100%)	0 (0%)
Group EW (N=30)	27 (90%)	3 (10%)

CE: Capsule Expander; ICCE: Intracapsular Cataract Extraction; PEA: Phacoemulsification

**Table 3:** Completed PEA and conversions to ICCE in cases of PEA with CE.

Group	PEA			PEA with CE		
	Total (N)	No of PCR (N)	Incident rate (%)	Total (N)	No of PCR (N)	Incident rate (%)
Group N	5089	55	1.08	6	0	0
Group W	181	2	1.1	62	0	0
Group VW	2	0	0	49	2	4.08
Group EW	0	0	0	30	2	6.67

CE: Capsule Expander; PCR: Posterior Capsule Rupture; PEA: Phacoemulsification

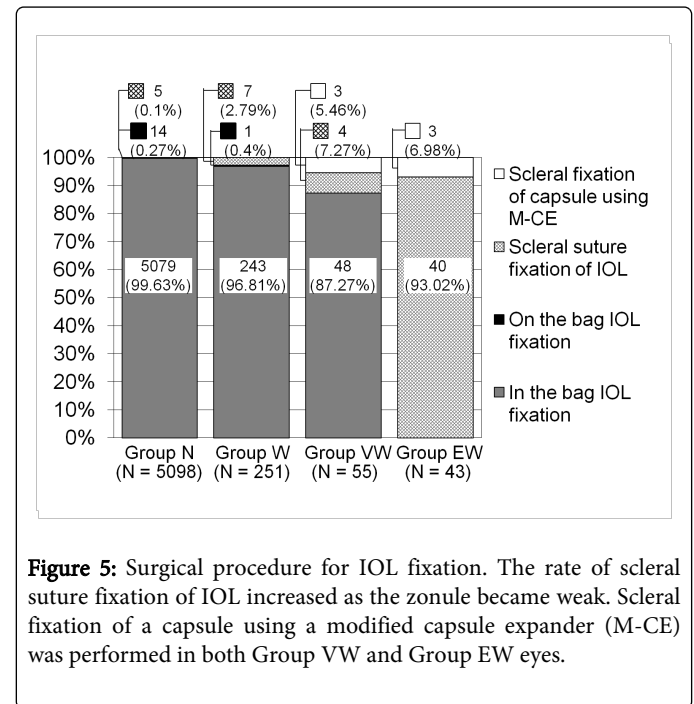
**Table 4:** PCR rate during PEA in cases of PEA with and without CE.

Eyes that sustained a PCR during PEA were examined, which means eyes that sustained a PCR during IOL implantation were excluded. We chose to examine PCRs that occurred due to zonular weakness and capsule instability. We observed that PCR had occurred in 2 eyes (4.08%) with Group VW score and 2 eyes (6.67%) with a Group EW score that underwent PEA with a CE. However, these four eyes did not show additional complications, such as vitreous prolapse or a dropped nucleus, which occurred with PCR.

### Surgical procedure for IOL fixation

The specific methods for IOL fixation included in the bag IOL fixation, on the bag IOL fixation, the scleral suture fixation of IOL, and in the bag IOL fixation following scleral fixation of the lens capsule using a modified CE (modified capsule expander™, M-CE, Handaya, Japan). We have also developed an M-CE that permanently fixates the lens capsule to the sclera in eyes with extensive or progressive zonular compromise [9].

The number and percentage of each IOL fixation procedure is shown by group in Figure 5. The rate of scleral suture fixation of IOL increased as the zonule became weak. Scleral fixation of the capsule using an M-CE was performed in 3 eyes (5.46%) with a Group VW, and 3 eyes (6.98%) with a Group EW. The IOLs remained centered and stable following the procedure.



**Figure 5:** Surgical procedure for IOL fixation. The rate of scleral suture fixation of IOL increased as the zonule became weak. Scleral fixation of a capsule using a modified capsule expander (M-CE) was performed in both Group VW and Group EW eyes.

### Discussion

Surgical management of weak zonules can be quite challenging in cataract surgery, as it requires additional methodologies, adjunctive devices, and surgical techniques to ensure the best possible outcome. Our categorization of weak zonule revealed that the need for a capsule stabilization device during PEA, ICCE, PPV, or scleral suture fixation of IOL increased as the zonule became weak.

It is important to recognize zonule instability when selecting the appropriate devices and surgical approach for cataract surgery. Lens

subluxation, zonule dialysis, iridodonesis, or phacodonesis are the direct signs of zonule instability, and can be observed preoperatively [6]. In addition to the direct signs of zonulopathy, several indirect signs have been described that predict the likelihood of intraoperative zonular problems. Increasing age, the presence of a shallow or hyper-deep anterior chamber, an increased cataract density, significant differences in refraction between eyes, and reduced pupil size may all indicate impaired zonular function [6]. Kuchle et al. [10] reported that an axial anterior chamber depth of less than 2.5 mm increased the risk of surgical complications, and concluded that a small anterior chamber depth may indicate zonular instability. Ultrasound biomicroscopy has been used to assess changes associated with pseudoexfoliation syndrome in the zonular apparatus, and a method for quantifying zonular integrity had been utilized [11,12].

Furthermore, grading the severity of zonulopathy is more useful than other predictive techniques, since the choice of cataract extraction and a capsule stabilization device depends greatly on the degree of zonular instability [13]. Zonular weakness is often described according to the number of clock hours, which reflect the degree of zonular dialysis [13-15]. However, a more simplified system that more easily grades zonule quality is needed (i.e., using 0 for some grades). Zonular strength is best assessed intraoperatively using several maneuvers and direct observation. Among them, the findings that are present at the initiation and creation of CCC are considered the intraoperative litmus tests for zonule instability [6]. Therefore, we categorize weak zonule into four groups according to the findings present at capsulorhexis and difficulty in performing CCC.

The ciliary zonule mostly consists of a series of fibers passing from the ciliary body to the lens. It holds the lens in position and enables the ciliary muscle to act during accommodation [16]. Zonular weakness is a well-described feature in eyes with pseudoexfoliation syndrome [17], high myopia [18], or connective tissue disorders such as Marfan's syndrome [19]. Subluxation also may be acquired from blunt external trauma [18], iatrogenic zonular dehiscence induced during vitreoretinal surgery [20], or a complicated cataract surgery. Moreover, zonules become more fragile as the patient ages [21]. The fetal and infantile zonular fibers are finer and less aggregated than those in the adult. In contrast, zonules decrease in number and the fibers become finer and sparser and rupture more readily in the elderly [16]. Assia et al. [21] demonstrated that the maximal zonular stretch decreased significantly with age. In this study, the proportion of eyes which categorized as Group W and VW, was increased in the >60 group compared with the <40 group. This tendency reflects zonule aging and provides validity for our zonular weakness categorization system.

We used a CE for most of the cases with weak zonular support that required a capsule stabilization device during PEA. In the 147 eyes in which a CE was used, PEA was completed in 144 eyes (97.96%). This high success rate demonstrated that PEA can be performed safely with the capsular bag suspended and stabilized by a CE in the presence of weak zonules.

In the past, cases with a severe zonular deficiency that would be categorized as Group EW, required ICCE and PPV for lens removal. These procedures require a large incision that increases the risk of complications. However, using the CE enabled lens removal by PEA in 62.79% (27) of the eyes assigned a Group EW categorization. Although vitreous prolapse was observed in 33.33% (9) of eyes undergoing PEA, this complication could be managed with an anterior vitrectomy. No nucleus was dropped into the vitreous cavity. The expanded capsular

bag that is mediated by the CE prevents the progressive vitreous prolapse through the area around the zonular loss, which reduces the likelihood of errant fragments ending up in the posterior segment. Using a CE enables lens removal with a small incision, even when zonular support is severely weak.

Furthermore, a CE does not interfere with CTR implantation, as CE makes contact with the anterior capsule and equator. A CTR was used in combination with CE to maintain the circular contour of the lens in 1 Group W eye and 2 Group VW eyes.

In this study, a single surgeon (S.Y.) performed all cataract operations, and CCC was created with a bent 23-gauge needle through a side-port paracentesis under BSS. This categorization is reliable because it is based on findings from a single surgeon who performed the same CCC procedure for each surgery. In addition, we had previously reported using a CE [5] and M-CE [9] to demonstrate their usefulness in cases with weak zonules.

There were limitations to our study. First, this categorization was based on subjective evaluations. A clear-cut distinction between groups can be determined, if the zonular instability can be quantitatively examined. This categorization is based on the findings that the needle movement during CCC was accompanied with severe lens movement in cases with severe zonular weakness. We considered that the needle would move for a longer distance when the lens is more fragile with weak zonular support, although zonular stretching and capsule elasticity may also affect this movement. Therefore, we managed to measure the distance that the needle moved at the start of CCC (Figure S1). Video recording of the CCC procedure was performed with high magnification. Two images were captured: one image showed when the needle tip caught the anterior capsule, and the other image demonstrated when the needle tip tore the capsule in Group N and W, or when the needle tip scratched the capsule to make a tear in Group VW. The margins of the needle, pupil, and pupil pattern were traced, and the two images were overlaid to coincide with the pupillary margin and pupil pattern. It appeared that there was a propensity for the distance of the needle movement to be longer in Group W and VW compared with Group N. We plan to further measure this distance of the needle with a large numbers of procedures and patients.

Second, the findings at CCC differs depending on the surgical technique, the instruments used (cystotome or forceps), the access and approach (via a primary incision or a side-port paracentesis), and the medium (BSS or OVD). The bent angle, length of the cystotome, point of initial perforation in the anterior capsule, and amount of medium may also affect the CCC findings. Before establishing this categorization system, the CCC findings were comparable between eyes filled with BSS and OVD, which confirmed that the tendency was similar between mediums. The findings associated with the CCC creation under different conditions must be examined. The usefulness of this categorization to other cataract surgeons performing CCC with their own technique must be also discussed.

Third, the fold formation during CCC was not a definitive finding. Although the zonules may be weakened, fold formation can be difficult to detect in cases with mature and intumescent cataracts. For this reason, Group W was defined as moderate lens movement "frequently" accompanied by fold formation around the needle tip during CCC. The current techniques that use the needle first require an initial puncture of the anterior capsule within the central area, which is then extended in a curve-shaped manner to target an

eccentric circle. The flap is then turned over, which applies vectorial forces when tearing with the needle [22]. The facts about lens movement and fold formation in this popular method must be examined.

Fourth, the applicability of this categorization system for other capsule stabilization devices must be examined. Concerning the CTR selection, the standard CTR is usually adequate when the dialysis is small, and a modified CTR [23] is needed in cases with more than 4 clock hours of involvement [13]. Deciding which capsule stabilization device to use may require more information regarding the extent of zonular damage, which is described as the number of clock hours.

Fifth, up-dated management and prevention of complication for challenging cases in cataract surgery must be discussed. A new generation of femtosecond laser for cataract surgery was introduced into ophthalmology in 2009 [24]. Since its introduction, femtosecond laser-assisted cataract surgery is increasing and offering advantages in complex cataracts such as traumatic cataracts, Marfan syndrome [25-27], and less severe cases of subluxated cataracts [13]. However, not every subluxated crystalline lens is applicable to this type of surgery; grossly subluxated lenses, poorly dilating pupils, and mobile crystalline lens represent contraindication to successful femtosecond laser-assisted cataract surgery [13]. The indication for femtosecond laser-assisted cataract surgery in each of the categorization must be examined. In this study, we used highly retentive and cohesive OVD and a capsule stabilization device in cases with zonular weakness. In addition to these devices, capsular staining is a useful adjunct to improve the safety of CCC by allowing for enhanced visualization of the anterior capsule in a variety of situations [28]. The usefulness of capsular staining in this categorization system must be examined.

In conclusion, we report a categorization of weak zonule that is determined by findings at the capsulorhexis and difficulty in performing CCC. The use of a capsule stabilization device, ICCE, and scleral suture fixation of IOL increased as the zonule became weak. PPV for lens removal was performed for cases in Group EW. This categorization may be useful in selecting an appropriate capsule stabilization device and the surgical procedure in cataract surgery.

## Financial Support

Shigeo Yaguchi has a patent Capsule Expander (No.8, 038,684 B2) with royalties paid to HANDAYA, Tokyo, Japan. No other author has any financial or proprietary interest in any material or method mentioned. The sponsor or funding organization had no role in the design or conduct of this research.

## References

- Hara T, Hara T, Yamada Y (1991) "Equator ring" for maintenance of the completely circular contour of the capsular bag equator after cataract removal. *Ophthalmic Surg* 22: 358-359.
- Blecher MH, Kirk MR (2008) Surgical strategies for the management of zonular compromise. *Curr Opin Ophthalmol* 19: 31-35.
- Hasanee K, Ahmed II (2006) Capsular tension rings: update on endocapsular support devices. *Ophthalmol Clin North Am* 19: 507-519.
- Hasanee K, Butler M, Ahmed II (2006) Capsular tension rings and related devices: current concepts. *Curr Opin Ophthalmol* 17: 31-41.
- Nishimura E, Yaguchi S, Nishihara H, Ayaki M, Kozawa T (2006) Capsular stabilization device to preserve lens capsule integrity during phacoemulsification with a weak zonule. *J Cataract Refract Surg* 32: 392-395.
- Shingleton BJ, Crandall AS, Ahmed II (2009) Pseudoexfoliation and the cataract surgeon: preoperative, intraoperative, and postoperative issues related to intraocular pressure, cataract, and intraocular lenses. *J Cataract Refract Surg* 35: 1101-1120.
- Yaguchi S, Ogiwara H, Imai M (1989) Bimanual Capsulotomy. *IOL* 3: 82-87.
- Gimbel HV (1992) Down slope sculpting. *J Cataract Refract Surg* 18: 614-618.
- Yaguchi S, Yaguchi S, Asano Y, Kozawa T, Miyawaki T, et al. (2011) Repositioning and scleral fixation of subluxated lenses using a T-shaped capsule stabilization hook. *J Cataract Refract Surg* 37: 1386-1393.
- Küchle M, Viestenz A, Martus P, Händel A, Jünemann A, et al. (2000) Anterior chamber depth and complications during cataract surgery in eyes with pseudoexfoliation syndrome. *Am J Ophthalmol* 129: 281-285.
- Inazumi K, Takahashi D, Taniguchi T, Yamamoto T (2002) Ultrasound biomicroscopic classification of zonules in exfoliation syndrome. *Jpn J Ophthalmol* 46: 502-509.
- Guo S, Gewirtz M, Thaker R, Reed M (2006) Characterizing pseudoexfoliation syndrome through the use of ultrasound biomicroscopy. *J Cataract Refract Surg* 32: 614-617.
- Hoffman RS, Snyder ME, Devgan U, Allen QB, Yeoh R, et al. (2013) Management of the subluxated crystalline lens. *J Cataract Refract Surg* 39: 1904-1915.
- Jacob S, Agarwal A, Agarwal A, Agarwal S, Patel N, et al. (2003) Efficacy of a capsular tension ring for phacoemulsification in eyes with zonular dialysis. *J Cataract Refract Surg* 29: 315-321.
- Ahmed II, Chen SH, Kranemann C, Wong DT (2005) Surgical repositioning of dislocated capsular tension rings. *Ophthalmology* 112: 1725-1733.
- Bron AJ (1997) The lens and zonules: Wolff's Anatomy of the Eye and Orbit. Chapman & Hall, London.
- Naumann GO, Schlötzer-Schrehardt U, Küchle M (1998) Pseudoexfoliation syndrome for the comprehensive ophthalmologist. Intraocular and systemic manifestations. *Ophthalmology* 105: 951-968.
- Zech JC, Tanniére P, Denis P, Trepsat C (1999) Posterior chamber intraocular lens dislocation with the bag. *J Cataract Refract Surg* 25: 1168-1169.
- Dureau P (2008) Pathophysiology of zonular diseases. *Curr Opin Ophthalmol* 19: 27-30.
- Yasuda A, Ohkoshi K, Orihara Y, Kusano Y, Sakuma A, et al. (2000) Spontaneous luxation of encapsulated intraocular lens onto the retina after a triple procedure of vitrectomy, phacoemulsification, and intraocular lens implantation. *Am J Ophthalmol* 130: 836-837.
- Assia EI, Apple DJ, Morgan RC, Legler UF, Brown SJ (1991) The relationship between the stretching capability of the anterior capsule and zonules. *Invest Ophthalmol Vis Sci* 32: 2835-2839.
- Neuhann TH (2004) Capsulorhexis: Clinical Practice in Small Incision Cataract Surgery. Taylor & Francis, UK.
- Cionni RJ, Osher RH (1998) Management of profound zonular dialysis or weakness with a new endocapsular ring designed for scleral fixation. *J Cataract Refract Surg* 24: 1299-1306.
- Nagy Z, Takacs A, Filkorn T, Sarayba M (2009) Initial clinical evaluation of an intraocular femtosecond laser in cataract surgery. *J Refract Surg* 25: 1053-1060.
- Nagy ZZ, Kránitz K, Takacs A, Filkorn T, Gergely R, et al. (2012) Intraocular femtosecond laser use in traumatic cataracts following penetrating and blunt trauma. *J Refract Surg* 28: 151-153.
- Schultz T, Ezeanosike E, Dick HB (2013) Femtosecond laser-assisted cataract surgery in pediatric Marfan syndrome. *J Refract Surg* 29: 650-652.
- Grewal DS, Basti S, Singh Grewal SP (2014) Femtosecond laser-assisted cataract surgery in a subluxated traumatic cataract. *J Cataract Refract Surg* 40: 1239-1240.

28. Goldman JM, Karp CL (2007) Adjunct devices for managing challenging cases in cataract surgery: capsular staining and ophthalmic viscosurgical devices. *Curr Opin Ophthalmol* 18: 52-57.