

Case Report: One Eye, Two Images

Hoang Harry Huy Joseph Tran* and Stuart P. Richer

237 Fisher Branch Health Clinic, US

*Corresponding author: Hoang Harry Huy Joseph Tran, O.D., 237 Fisher Branch Health Clinic Great Lakes, IL US, Tel: 13162008417; E-mail: hoang.tran@med.navy.mil

Received date: August 08, 2014, Accepted date: September 16, 2014, Published date: September 23, 2014

Copyright: © 2014 Tran HHHJ, et al. This is an open-access article distributed under the terms of the Creative Commons Attribution License, which permits unrestricted use, distribution, and reproduction in any medium, provided the original author and source are credited.

Case Presentation

A 25 year-old Caucasian male is present for an annual comprehensive eye exam with a chief complaint of double vision in the left eye only. The patient's last eye exam was 3 months ago when treated for an uncomplicated corneal abrasion secondary to trauma. The onset of diplopia was 1.5 months ago upon awakening in the morning. The double vision was constant with no other associated symptoms including, but not limited to, pain, irritation or photophobia. The patient's best-corrected visual acuities (BCVA) were 20/20 OD and 20/40 OS; the patient has a history of accommodative spasm causing his best-corrected visual acuity to fluctuate. The patient had normal ocular motility, confrontation visual fields, binocularity and pupillary responses.

Given the aforementioned information, the following differential diagnoses were considered: cataract, keratoconus, lens displacement or other corneal irregularity. Problems such as nerve palsies and extraocular muscle abnormalities were ruled out since they are associated with binocular diplopia.

A complete dilated fundus exam was performed to further investigate the patient's chief complaint. In addition, corneal topography was performed to rule out any corneal irregularity. Anterior corneal topography with a Humphrey Atlas® topographer revealed regular astigmatism with no areas of abnormal thinning, thus ruling out keratoconus. The lens was well-centered with no indication of early cataract formation in either eye. Using a high-magnification setting on the slit lamp biomicroscope, a micro-abrasion was seen directly over the left eye visual axis; this was essentially splitting the eye's image causing the patient's chief complaint of monocular double vision. Small, sub-epithelial ridges and lines were also observed nasal to the micro-abrasion indicating poor adhesion of the surface epithelial basement membrane to the underlying Bowman's layer.

Diagnosis

In cases where the classic indicators of recurrent corneal erosions such as pain, photophobia and excessive tearing are not present, a

careful and thorough slit lamp exam is vital in determining the final diagnosis. In this case, the patient was diagnosed with recurrent corneal erosion.

Treatment

Following diagnosis, we debrided the left eye corneal epithelium. The patient was administered 2 gtt's 0.5% proparacaine and the epithelium was debrided through the slit lamp biomicroscope using a cotton-tip applicator (Figure 1).

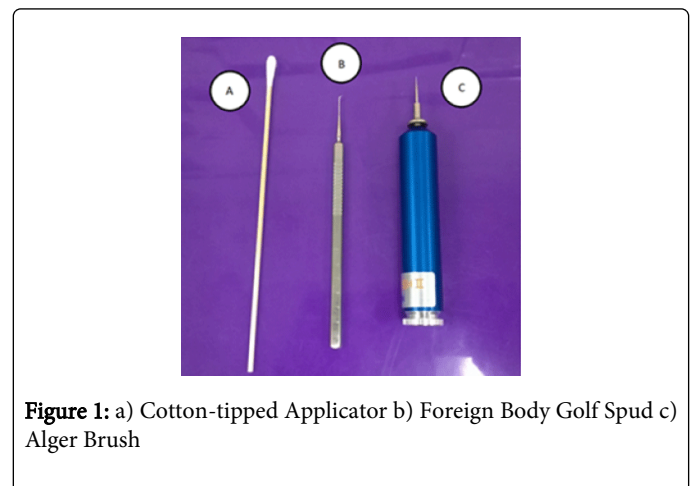

Figure 1: a) Cotton-tipped Applicator b) Foreign Body Golf Spud c) Alger Brush

A normal cornea would not easily be debrided with the gentle touch of a cotton-tipped applicator, however, a cornea with compromised structural integrity easily shrivels and debrides with the cotton swab. Once the loose epithelium was removed, the edges of the area of abrasion were smoothed with a golf spud (Figure 1) or Alger Brush (Figure 1) to ensure proper re-epithelialization. Due to the precise nature of the procedures, it is important to use a slit lamp biomicroscope to avoid permanent damage to the cornea (Figure 2).

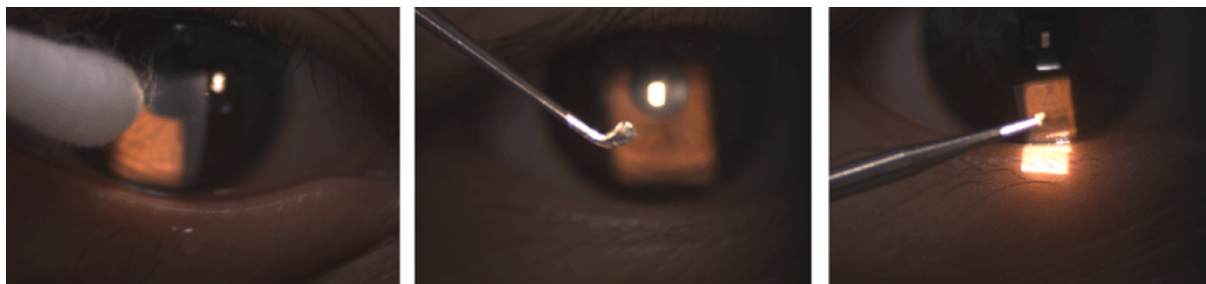


Figure 2: The primary instruments used to debride a corneal epithelium as seen through a slit lamp biomicroscope

Despite the small abrasion size, a large amount of loose epithelium was present resulting in the debridement of 80% of the corneal epithelium. Biomicroscopic examination revealed clean edges and successful clearing of damaged epithelium. The patient was prescribed 1 drop 0.5% moxifloxacin as prophylactic treatment to prevent infection and 1 drop 2% Cyclogyl for pain.

The patient was released with a Ciba Air Optix Night & Day® bandage contact lens approved for 30 days of extended-wear to protect the ocular surface through the re-epithelialization process. The patient left the office with 0.5% moxifloxacin qid, Refresh® artificial tears sig 30 minutes, and Vicodin qid for pain.

At one day, the patient was in severe pain with photophobia as expected, but healing was on schedule. Biomicroscopic examination showed diffuse stromal haze but normal epithelial migration and no signs of infection. Another gtt of 2% Cyclogyl was given for pain. The right eye BCVA on this day was 20/200 and 20/150 via pinhole.

After three days, the cornea had completely re-epithelialized and there were no signs of infection or ulceration. The patient was given 1 drop of 2% Cyclogyl again for increased comfort. The patient was also given a prescription of 50mg doxycycline to take two times a day to assist with reformation of epithelial adhesion complexes.

The one week follow up showed a significant improvement in symptoms. Vision was 20/50 via pinhole without correction in the left eye. The cornea in the left eye had 1+ edema and trace stromal haze. The patient was prescribed 0.5% loteprednol BID left eye to decrease swelling and edema.

At the two-week follow-up, the stromal haze had resolved but the patient still had mild corneal edema. The patient's visual acuity is expected to return once the edema resolves. The patient will continue to take 0.5% loteprednol for two weeks and slowly taper as the cornea heals. He will also continue taking 0.5% moxifloxacin as prophylaxis to infection since he will be wearing a bandage contact lens for three months with a two week replacement schedule. The patient is to take 50mg doxycycline once daily for three months to facilitate the healing of the anchoring molecules in the adhesion complexes of the basement membrane. If the aforementioned medical treatment fails, consider surgical treatment options such as anterior stromal puncture or phototherapeutic keratectomy.

Discussion

The human cornea has 5 layers: epithelium, Bowman's, Stroma, Dua's, Descemet's and endothelium. Recurrent corneal erosions (RCE) often occur in individuals with a history of corneal injury such as an

abrasion or ulcer. Previous corneal injuries predispose a disruption in the corneal epithelial membrane (1st layer), resulting in defective and unstable adhesions between the epithelium and the underlying Bowman's membrane (2nd layer) and stroma (3rd layer). The most common causes of abrasive injuries are by human fingernails, tree leaves and tree branches. 4 Other common causes of RCEs are corneal dystrophies and corneal diseases resulting in recurrent breakdown of corneal epithelial cells.

The general treatment for an acute episode of recurrent corneal erosion includes a single cycloplegic drop and antibiotic ointment four to six times daily. A large defect may require epithelial debridement and warrant the use of a pressure patch or bandage contact lens and topical antibiotic drops four times a day [2].

Once the cornea has healed, maintenance therapy is generally required to decrease the chance of recurrence. There are two main options with regard to decreasing future erosion(s): medical therapy and surgical therapy.

One of the more common medical therapies includes 5% sodium chloride qid and 5% sodium chloride ung qhs for at least 3 to 6 months. Studies additionally show that medical treatment with oral doxycycline 50mg BID po along with topical fluoromethalone 0.1% TID for at least 4 weeks is effective for treating recurrent attacks and preventing further attacks [5]. A study shows that only one-third of medically treated cases have had recurrences. Surgical therapies such as anterior stromal puncture and phototherapeutic keratectomy, on the other hand, have been shown to be even more effective; with only a quarter of surgically treated cases having recurrences [3]. Anterior stromal puncture employs a 23 gauge needle or Nd:YAG to puncture the stroma, thus creating a strong adhesion complex stimulated by scar formation. Phototherapeutic keratectomy uses a laser to ablate Bowman's membrane thus facilitating healing with a more secure attachment of the corneal epithelium to its underlying layers. Essentially, both techniques are aimed toward creating a more stable epithelium by first damaging it and allowing it to regenerate with stronger adhesion complexes.

Overall, treatment options for RCEs are on a case-by-case basis. Erosions often present differently and the eye care provider must take careful consideration in choosing the appropriate treatment plan.

References

1. Das S, Seitz B (2008) Recurrent corneal erosion syndrome. *Surv Ophthalmol* 53: 3-15.

2. Ramamurthi S, Rahman MQ, Dutton GN, Ramaesh K (2006) Pathogenesis, clinical features and management of recurrent erosions. *Eye (Lond)* 20: 635-644.
3. Reeves SW, Kang PC, Zlogar DF, Gupta PK, Stinnett S, et al. (2010) Recurrent Corneal Erosion Syndrome: A Study of 364 Episodes. *Ophthalmic surgery, lasers & imaging: the official journal of the International Society for Imaging in the Eye* 9: 1-2.
4. Singh R and Sutton G (2012) Medical and surgical treatment of recurrent corneal erosions. *Medicine Today* 13: 71-73.
5. Wang L, Tsang H, Coroneo M (2008) Treatment of recurrent corneal erosion syndrome using the combination of oral doxycycline and topical corticosteroid." *Clinical & experimental ophthalmology* 36: 8-12.