

Calcific Pancreatitis mimicking as Metastasis from Neuroendocrine Tumour

Abhijeet Dharmaji Sawant*, Adrianna D'Mello, Namita Deogaonkar and Sudeep R Shah

Department of GI Surgery, P.D. Hinduja, National Hospital and MRC, Mahim, Mumbai, India

*Corresponding author: Abhijeet Dharmaji Sawant, Senior Resident, Department of GI Surgery, P.D. Hinduja, National Hospital and MRC, Mahim, Mumbai, Tel: +919820993365; E-mail: dr.sawant.abhijeet@gmail.com

Rec date: Jul 30, 2015; Acc date: Aug 31, 2015; Pub date: Sep 7, 2015

Copyright: © 2015 Sawant AD. This is an open-access article distributed under the terms of the Creative Commons Attribution License, which permits unrestricted use, distribution, and reproduction in any medium, provided the original author and source are credited.

Abstract

We present a 44 year old man, a known case of neuroendocrine tumor of periampullary region that underwent Whipple's procedure. He was asymptomatic for four years postoperatively, following which he complained of loss of appetite, malaise and had significant weight loss. His CT scan of abdomen and pelvis revealed pancreatic duct dilatation and calcific pancreatitis with no sign of disease anywhere else. Hence, calcific pancreatitis can mimic metastasis in an operated case of Whipple's procedure especially in neuroendocrine tumors which are low grade & slow growing. Calcific pancreatitis is not a known complication of Whipple's procedure and has not been cited in literature.

Keywords: Neuroendocrine tumor; Whipple's procedure; Calcific pancreatitis

Introduction

Neuroendocrine tumours (NET) are also known as carcinoid tumours [1]. NET are slow growing tumours, except in cases of Neuroendocrine carcinomas. Surgical excision is the treatment of choice for these tumours. Whipple's procedure is the treatment of choice for tumours in the second and third part of duodenum and the periampullary region or tumours larger than 2 cm [2].

Whipple's surgery has many known complications but development of chronic calcific pancreatitis after Whipple's surgery is not a known complication. Whipple's surgery is commonly performed for adenocarcinoma of periampullary region or pancreas, which have poor prognosis with poor 5 year survival rate. Hence development of chronic calcific pancreatitis is not a known entity in these cases due to non-availability of long term follow-up. Chronic pancreatitis mostly presents with debilitating abdominal pain that may be episodic or continuous. The pathogenesis of pain is likely multifactorial with contributions from ischemia, neural factors, and free radical injury and pancreatic duct obstruction with resultant ductal hypertension [3].

Case Report

A 44 year old gentleman, a known case of neuroendocrine tumour of periampullary region presented with obstructive jaundice about four years back. He underwent Whipple's procedure for the same. His histopathological report was suggestive of low grade neuroendocrine carcinoma. His post-operative recovery was uneventful and he was discharged 10 days after surgery. He didn't receive any adjuvant therapy as the tumor was low grade. He was on routine follow up and was asymptomatic with normal laboratory reports. His CT scan after two years of surgery done for routine follow up was also normal (Figure 1).

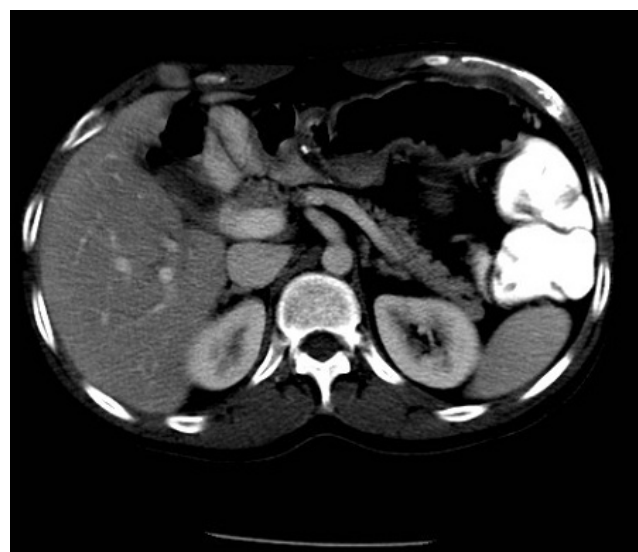


Figure 1: Follow up CT scan of abdomen 2 years after surgery showing no abnormality.

But four years after the surgery he noticed decreased appetite, associated with weight loss of 6 kg over a 3 three month period. He also had malaise and easy fatigability. On investigations his blood parameters and chest X-ray were normal. Metastasis was suspected and the patient underwent a contrast enhanced CT scan of abdomen and pelvis. His scan revealed dilated pancreatic duct measuring 7 mm with multiple foci of intraductal as well as few foci of intra pancreatic calcification as the only positive finding (Figure 2).

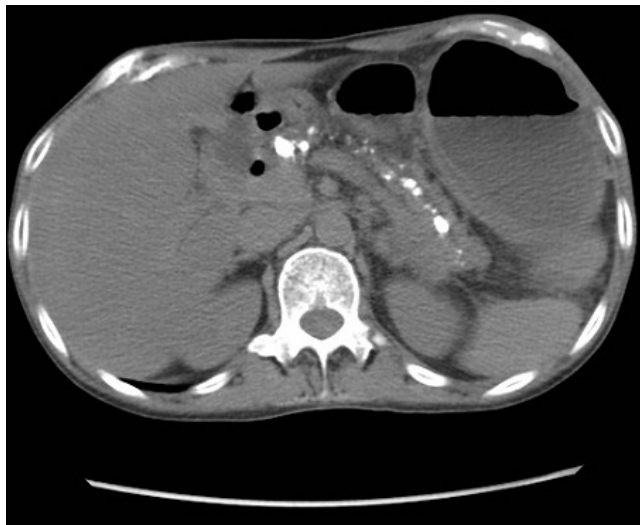

Figure 2: CT scan of abdomen showing calcification within the pancreatic parenchyma and dilatation of duct with calcification within the pancreatic duct. White arrow denoting calcification within the pancreatic duct resulting into its dilatation.

The Patient was counseled about the condition and started on oral pancreatic enzyme supplements. He gradually improved with symptomatic treatment, with increased appetite and weight gain. On follow up for two years, patient is asymptomatic with no signs of disease elsewhere in the body. He currently does not require pancreatic enzyme supplements.

Discussions

Neuroendocrine tumors are most commonly seen in small intestine [1]. They are mostly benign and hence slow growing with no metastatic potential. However, there is a small incidence of these tumors being malignant, with metastatic potential. NET arising in the periampullary region can cause obstructive jaundice. Of the various treatment modalities, surgical excision of the tumor is the treatment of choice. Excision can be done endoscopically for small tumors. But for

tumors greater than two cm and located in the second and third part of duodenum or in head of pancreas warrant a Whipple's procedure. Whipple's procedure is usually done for malignant tumors arising in the head of the pancreas and periampullary region which are mostly adenocarcinoma which have poor prognosis due to late detection and high propensity for metastasis. Due to poor prognosis of adenocarcinoma the 5 year survival rates are very low. So these patients do not have long term follow-up. In cases of NET the survival rates are high. So these patients can be followed up for a longer time frame.

As in our case, we report a complication of Whipple's procedure, in which a patient developed calcific pancreatitis after four years of surgery. This could be due to development of anastomotic stricture at pancreato-jejunal anastomosis. There is no report in literature of cases with development of calcific pancreatitis after Whipple's procedure. Development of calcific pancreatitis can mimic signs of metastasis like loss of appetite with weight loss and malaise. It can create a diagnostic dilemma. But its diagnosis and differentiation from metastatic disease is important as their management and prognosis is different.

Conclusion

Due to good prognosis of NET and hence prolonged survival complications like calcific pancreatitis can develop post Whipple's procedure. As this is not a known complication of Whipple's procedure it is often not considered and can produce diagnostic dilemma, with often the symptoms being considered as metastatic disease. Hence calcific pancreatitis should be considered as a differential diagnosis in these cases especially in patients with prolonged survival.

References

1. Modlin IM, Sandor A (1997) An analysis of 8305 cases of carcinoid tumors. *Cancer* 79: 813-829.
2. Hartel M, Wente MN, Sido B, Friess H, Büchler MW (2005) Carcinoid of the ampulla of Vater. *J Gastroenterol Hepatol* 20: 676- 681.
3. Christopher L, Siddiqi FM, Hamilton JN, Keane TE, Romagnuolo J et al. (2010) Chronic Calcific Pancreatitis: Combination ERCP and Extracorporeal Shock Wave Lithotripsy for Pancreatic Duct Stones. *South Med J* 103: 505-508.