

Break Through Inspiration During IPPV is Seen as “Curare Crest” in Sevograph

Mukesh Tripathi^{1,2*}, Sanjay Kumar², Nilay Tripathi³ and Mamta Pandey⁴

¹Department of Anesthesiology, All India Institute of Medical Sciences, Rishikesh, India

²Department of Anesthesiology, Sanjay Gandhi Postgraduate Institute of Medical Sciences, Lucknow, India

³Internist, Department of Medicine, King George's Medical University, Lucknow, India

⁴Department of Emergency Medicine, Sanjay Gandhi Postgraduate Institute of Medical Sciences, Lucknow, India

*Corresponding author: Mukesh Tripathi, Professor and Head, Department of Anesthesiology, Type V-B/20, Campus SGPGIMS, Lucknow-226014, India, Tel: 0091522294486/00919452211155; Fax: 00915222668544; E-mail: mukesh_tripathi@yahoo.com

Received date: June 28, 2016; Accepted date: September 09, 2016; Published date: September 15, 2016

Copyright: © 2016 Tripathi M, et al. This is an open-access article distributed under the terms of the Creative Commons Attribution License, which permits unrestricted use, distribution, and reproduction in any medium, provided the original author and source are credited.

Abstract

Background: The break through spontaneous effort in anaesthetized and ventilated patients is seen as 'curare-cleft' during expiratory plateau phase of the capnography. At the open position of the sevoflurane vaporizer, the sevograph displays a mirror image graph to the capnograph. We studied the sevograph changes corresponding to 'curare-cleft' in capnography.

Methods: We have observed that during break through spontaneous breaths the sevograph complemented 'curare-crest' corresponding to 'curare-cleft' in six patients. In second part of study 25 consenting adult patients coming for surgery were given general anaesthesia using fentanyl, propofol and suxamethonium. After tracheal intubation, controlled ventilation was started under sevoflurane anaesthesia. We allowed the onset of spontaneous effort and observed for the onset time to 'curare-cleft' in capnograph, 'curare-crest' in sevograph, visible negative deflection of the needle in airway pressure gauge till negative airway pressure of 5 cm H₂O. The onset time for the both changes were statistically analysed for agreement analysis using Blend and Altman test.

Results: 'Curare-crest' in sevograph was visible at the same breath in majority (76%) of instances along with that of 'curare-cleft' in capnograph. Both appeared in respective graphs significantly earlier than the negative deflection of airway gauge needle by 5 cm H₂O and disappeared after vecuronium. Onset time for both 'curare-cleft' in capnograph and 'curare-crest' in sevograph had significant ($p < 0.01$) correlation ($R = 0.97$) too.

Conclusions: The authors feel that both changes 'curare-crest' in sevograph complemented 'curare-cleft' in capnograph and can be equivocally used as warning signal for lighter planes of anesthesia or diminishing effect of muscle relaxant.

Keywords: Sevography; Capnography; Curare crest; Curare cleft; Monitoring

Introduction

In patient under controlled ventilation during general anesthesia, if patients get break through spontaneous inspiratory efforts, a cleft is seen in the expiratory plateau phase of capnograph. These are popularly referred as 'curare-cleft' and represent diaphragmatic contraction [1]. These defects are associated with diaphragmatic contraction when no response is elicited at the adductor pollicis under muscle relaxant effect [1].

Modern anesthesia monitors give simultaneous graphic display of multiple vital parameters. Anesthesia gas monitoring graphs have also been included along with the digital values of the inspiratory and expiratory levels. Sevograph displays a mirror image graph to capnograph during inspiratory and expiratory phases during positive pressure ventilation (Figure 1).

The mirror image pattern is also reflected as a downslope in expiratory phase in sevograph during bronchospasm vis-a-vis upslope in capnography [2]. Therefore we got interested to look for the changes

in sevograph in the event of 'curare-cleft' seen during break through breaths under controlled ventilation. After extensive scientific search when we did not find any report, we wish to report our observations of the 'curare-crest' seen on the expiratory sevograph.

Materials and Methods

A female aged 45 yr was posted for emergency laparotomy. Written informed consent was taken and we monitored electrocardiography, non-invasive arterial blood pressure, central venous pressure, capnography and sevography using anesthesia work station (Dragger Fabius GS premium, Dräger Medical AG and Co KG 23542, Lubeck, Germany).

We performed rapid sequence induction of general anesthesia by giving intravenous injection of fentanyl (100 mcg), thiopental (250 mg) and suxamethonium (100 mg). After cessation of the fasciculation we intubated trachea. Anesthesia was maintained with sevoflurane at 2% along with N₂O and O₂ (50:50). Just below the capnograph a mirror image sevograph was seen on monitor (Figure 1).

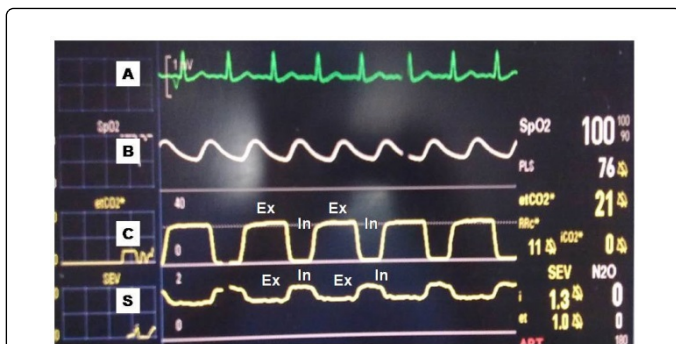


Figure 1: The Multi-channel monitoring screen displaying various wave-forms; A) Electrocardiogram; B) Plethysmograph of pulse oximetry; C) Capnograph; S) Sevograph. The sevograph displayed mirror image of inspiratory (Ins) and expiratory (Ex) phases during positive pressure ventilation during open position of sevoflurane vaporizer characteristically showing 'i-sevo' levels higher than 'et-sevo' levels.

After 10 min patient started breathing and break through breaths were reflected as 'curare-cleft' during expiratory phase in the capnograph. Interestingly we also noticed a corresponding 'curare-crest' in sevograph at same point in expiratory phase of respiratory cycle replicating the mirror image pattern to the capnograph (Figure 2A). After intravenous vecuronium bromide (7 mg) both changes in expiratory phase disappeared to restore plateau character in both graphs (Figure 2B). In next five consecutive anesthetised patients for surgery, we again confirmed similar changes of curare-cleft in capnograph vis-a-vis curare-crest in sevograph during break through breaths. The two changes appeared in on position of the sevoflurane vaporizer.

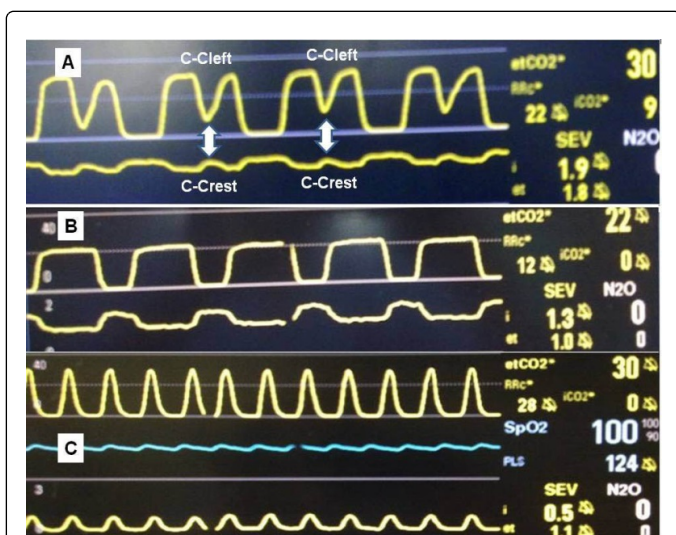


Figure 2: A) Mirror image capnograph and sevograph; B) Curare-cleft' in capnograph corresponds a 'curare-crest' in sevograph (white arrow); C) Sevograph becomes similar to capnograph as vaporizer is switched off.

Based on these results, second part of the simple observational study was conducted on the randomly selected 25 adult (28 yr to 55 yr), ASA grade I, patients of both gender (female=10 and male=15) coming for surgery under general anesthesia. A written informed consent was obtained from all patients after explaining the study protocol. Ethical approval for conducting routine anesthesia protocol for the observations during allowed breathing under anesthesia was taken from the Institute Ethics Committee.

We induced general anesthesia by fentanyl (1 µg/kg), propofol (1 to 1.5 mg/kg) and suxamethonium (1 mg/kg) to facilitate laryngoscopy and intubation. We ventilated lungs on positive pressure ventilation of tidal volume (10 ml/kg) and respiratory rate (12/min) at switched-on sevoflurane vaporizer at 3% during study period. We allowed the patient till we observed the 'curare-cleft', 'curare-crest' negative deflection of breathing pressure gauge needle and the generation of negative airway pressure of 5 cm H₂O. We noted onset time from the induction of anesthesia for the respective changes as above. At the end of study vecuronium (0.1 mg/kg) was given to continue general anesthesia for surgery.

All data were entered in SPSS-16.0 (Statistical Package Social Sciences, Chicago, US) and MS-Excel (Microsoft Office inc., US) for the statistical analysis. The Paired students'-t test was applied to compare mean values. To find out the agreement between 'curare-cleft' and 'curare-crest' the regression analysis was performed between the onset times of the two changes. The Blend and Altman graph was prepared using Excel software.

Results

We observed that in all six occasions, the inspiratory sevoflurane (i-sevo) levels (2.4 ± 0.9 %) were persistently higher than the expiratory sevoflurane (et-sevo) levels (1.7 ± 1.1 %) during open position of the vaporizer. Interestingly when we switched off the sevoflurane vaporizer, the sevograph displayed the respiratory phases same as of capnograph (Figure 2C). The i-sevo (1.3 ± 0.5 %) levels at this pattern were also lesser than the et-sevo (0.7 ± 0.8 %) levels during IPPV (Figure 2C). Similar findings were noted on all the occasion in both the graphic display.

The second part of study included 25 observations on 25 adult patients weighing (55 ± 18.5 kg) and height (158 ± 12 cm) (Table 1). The onset time of curare-cleft (394 ± 43.1 sec) was insignificantly ($p > 0.05$) earlier than the onset 'curare-crest' (400 ± 46.3 sec). However the onset times of the two parameters were significantly ($p < 0.01$) earlier than the onset time (445 ± 40.9 sec) of visible negative deflection of the needle of the airway pressure gauge and the onset time (467 ± 40.4 sec) of the negative airway pressure by 5 cm H₂O during break through breaths (Table 1). We also found that in majority (19/25; 76%) patients, the curare-cleft in capnograph and 'curare-crest' in sevograph was visible in same breath on monitor. The 'curare-cleft' and 'curare-crest' disappeared after vecuronium injection in all patients.

A significant ($p < 0.01$) correlation existed between the onset times of the curare-cleft and the 'curare-crest' ($R^2=0.94$) (Table 2). The Bland and Altman plot of 25 paired samples again depicted significant ($p < 0.01$) correlation with slope 0.085 (Figure 3).

	Curare cleft	Curare crest	Negative needle deflection	Negative airway pressure (5 cm H ₂ O)
Number of observation (n)	25	25	25	25
Onset time (sec) (mean ± SD)	394 ± 43.1	400 ± 46.3	445 ± 40.9*	467 ± 40.4*
Median onset time (sec)	390	390	430	466
Range (min-max)	340-480	340-480	380-520	400-550

*-Statistically significant (p<0.01) difference from other onset times

Table 1: Showing the observations of the study.

		Onset time to curare-cleft (s)	Onset time to curare-crest (s)
Pearson Correlation	Onset time to curare-cleft (s)	1	0.972
	Onset time to curare-crest (s)	0.972	1
Sig. (1-tailed)	Onset time to curare-cleft (s)	.	0
	Onset time to curare-crest (s)	0	.
Correlation coefficients	R=0.972	R ² =0.94	P<0.001

Table 2: Showing observations of the correlation analysis between onsets of 'curare-cleft' with 'curare-crest'.

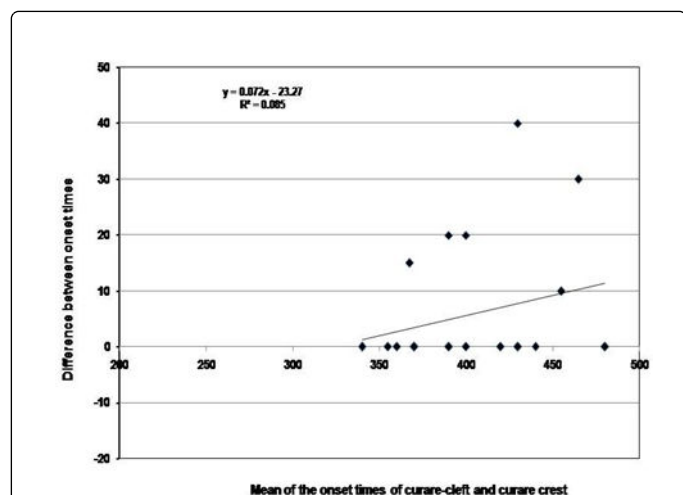


Figure 3: Bland and Altman Plot of the data obtained from 25 paired observations of onset time of 'curare-cleft' and 'curare-crest'. Correlation coefficient R= 0.97 (p<0.01), Slope=0 (p<0.01).

Discussion

These observations confirm that the mirror image configuration of sevograph is seen during 'open-position' of its vaporizer under

controlled ventilation in general anesthesia. The 'curare-cleft' in capnograph on break-through breath was also complemented as 'curare-crest' during expiratory phase of ventilation on sevograph. Both the changes 'curare-cleft' and 'curare-crest' appeared in majority of patients at the same breath of ventilation. The onset time of the two changes were significantly earlier than the diaphragmatic contractions forceful enough to cause negative deflection of the airway pressure measuring needle or generating negative airway pressure of 5 cm H₂O. There was significant correlation between the onset times of the 'curare-cleft' and 'curare-crest' during allowed break-through breaths and both disappeared after the injection of vecuronium.

The 'curare-cleft' in capnograph was associated with the diaphragm activity [1]. It results from the in-drawing of the gases from the inspiratory limb of the breathing circuit containing lower levels of the carbon dioxide. Since these inspiratory gases contain higher levels of sevoflurane during 'open-position' of the vaporizer, contrary to capnograph this sudden in-drawing of the gases from inspiratory limb was displayed as "curare-crest" on the sevograph at the identical point of the expiratory plateau phase (Figure 2).

Although 'curare-cleft' have been correlated with the diaphragm activity in the paralyzed and ventilated patients and disappears after repeat dose of muscle relaxant, it has failed to measure degree of muscle relaxation of the peripherally monitored muscles (adductor pollicis) [3]. We too found that 'curare-cleft' and 'curare-crest' appeared simultaneously in the expiratory phase of ventilated patients significantly earlier than the diaphragmatic contractions to generate visible negative deflection of the needle of the airway pressure monitoring gauge or generate a negative airway pressure of 5 cm H₂O. The related mechanism has been correlated with rapid kinetics of the muscle relaxant in the diaphragm than the adductor pollicis [4,5].

Anesthesiologists are interested to detect the break through breaths of the patients when the muscle relaxants affect vanes off. If remained unnoticed such efforts are fraught with the problems of the jerky movement, swallowing, gagging movement, tight abdomen and even hemodynamic changes. Recently 'curare-cleft' have also been described during non-specific conditions related to breathing circuit [6,7] unilateral capnothorax [8] and even without respiratory effort in children [9]. We have found that the two changes correlated very closely and appeared simultaneously as well as significantly earlier than the contractions of the diaphragm intense enough to cause negative reflection of the airway pressure gauge. Thus these changes seen on monitor warn significantly earlier to take measures to correct light anesthesia [10] or perhaps inadequate analgesia in the patient.

The 'curare-crest' has the limitation that this change on sevograph is only visible when the vaporizer is in open position and the sevograph shows similar configuration as of capnograph as soon as the vaporizer is put off [2].

Authors feel that the 'curare-crest' in sevograph is new pattern, which closely follows the 'curare-cleft' of capnograph to detect diaphragmatic activity during positive pressure ventilation and can be a good adjunct to detect early diaphragmatic contractions during general anesthesia under controlled ventilation.

Conflict of Interest

Authors declared that there are no conflicts of interest.

Funding

No external funding and no competing interests declared or Funded by the grant.

Author's Contribution

Mukesh Tripathi: Conception and study design, conduct of case, acquisition of data, photographs, primary drafting of article and editing, approver of final draft.

Sanjay Kumar: Conduct of cases, data acquisition, data interpretation, literature search, editing of article, approver of final draft.

Nilay Tripathi: Data acquisition, computation and interpretation, photograph editing literature search, Manuscript writing and editing and approver of final draft.

Mamta Pandey: Study design, data interpretation, statistical analysis, literature search, editing of article and approver of final draft.

References

1. Bissinger U, Lenz G (1993) Capnographic detection of diaphragm movements ("curare cleft") during complete vecuronium neuromuscular block of the adductor pollicis muscle. *Anesth Analg* 77: 1303-1304.
2. Kumar S, Tripathi M (2013) Down slope on sevoflurane graph in expiratory phase evidence on monitor to diagnose subtle bronchospasm. *Br J Anaesth*.
3. Bissinger U, Lenz G, Reiter A, Albrecht T, Schorer R (1993) Monitoring neuromuscular function: capnography versus relaxometry. *Anaesthesiol Intensivmed Notfallmed Schmerzther* 28: 359-362.
4. Donati F, Meistelman D, Plaud B (1990) Vecuronium neuromuscular blockade at the diaphragm, the orbicularis oculi, and the adductor pollicis muscles. *Anesthesiology* 73: 870-875.
5. Lebrault C, Chauvin M, Guirimand F, Duvaldestin P (1989) Relative potency of vecuronium on the diaphragm and the adductor pollicis. *Br J Anaesth* 63: 389-392.
6. Hensler T, Chamee MS (1990) Anesthesia machine malfunction simulating spontaneous respiratory effort. *J Clin Monit* 6: 128-131.
7. Tripathi M, Tripathi M (1998) A partial disconnection at the main stream CO2 transducer mimics "curare-cleft" capnograph. *Anesthesiology* 88: 1117-1119.
8. Singh M, Chaudhary K, Uppal R (2014) Jain S. Beware of "curare cleft" like changes during unilateral capnothorax. *J Clin Monit Comput* 28: 315-318.
9. Seefelder C (2012) The 'curare cleft' is not the first sign of respiratory effort. *Paediatr Anaesth* 22: 415-416.
10. http://www.multileadmedics.com/www.multileadmedics.com/Capnography_files/Slap%20the%20Cap%20handout%202012_revised.pdf.